Hong Kong J Radiol. 2019;22:130-41 | https://doi.org/10.12809/hkjr1916924

ORIGINAL ARTICLE

Preoperative Sonographic Assessment of Axillary Lymph Nodes in Newly Diagnosed Invasive Breast Cancer

KH Wong[1], YL Li[2], MKH Yam[1], HKY Tam[1], GKF Tam[1], APY Tang[3]

[1]*Department of Radiology, North District Hospital, Sheung Shui, Hong Kong*
[2]*Department of Radiology, Queen Mary Hospital, Pokfulam, Hong Kong*
[3]*Diagnostic Radiology Department, Alice Ho Miu Ling Nethersole Hospital, Tai Po, Hong Kong*

ABSTRACT

Objective: *To assess the sonographic features and fine needle aspiration of ipsilateral metastatic axillary lymph nodes of newly diagnosed invasive breast cancer.*

Methods: *This was a retrospective review of the sonographic features of ipsilateral axillary lymph nodes of patients with newly diagnosed invasive breast cancers, attending a single radiology centre from January 2014 to December 2016. Among 449 axillae review, 362 axillae of 355 breast cancer patients with available sonographic images and surgical histopathology or positive fine needle aspiration cytology were analysed. Qualitative morphological assessments and quantitative measurements of the axillary lymph nodes were performed.*

Results: *Various dimensions, areas, and ratios of the entire lymph node and its cortex were associated with nodal metastasis ($p < 0.001$), with the maximal cortical thickness showed superior performance. Using a 4-point grading system, the sonographic morphological features including focal cortical thickening, hilar displacement or replacement, and perinodal infiltration were associated with nodal metastasis ($p < 0.001$) with sensitivity 65.2% (95% confidence interval [CI] = 58.2%-71.8%) and specificity 96.9% (95% CI = 92.9%-99.0%). With the surgical histopathological result as the reference standard, the ultrasound-guided fine needle aspiration cytology showed moderate sensitivity 74.7% (95% CI = 63.3%-84.0%) and high specificity 100% (95% CI = 92.3%-100%).*

Conclusion: *Axillary ultrasound helps in preoperative axillary nodal staging of patients with invasive breast cancer. Ultrasound-guided fine needle aspiration cytology offers additional information to the metastatic nodal status with high specificity.*

Key Words: *Biopsy, fine-needle; Breast neoplasms*

Correspondence: *Dr KH Wong, Department of Radiology, North District Hospital, Sheung Shui. Hong Kong*
Email: wkh513@ha.org.hk

Submitted: 14 Sep 2017; Accepted: 27 Dec 2017.

Conflicts of Interest: All authors have disclosed no conflicts of interest.

Funding/Support: This research received no specific grant from any funding agency in the public, commercial, or not-for-profit sectors.

Ethics Approval: The study was approved by the Joint Chinese University of Hong Kong–New Territories East Cluster Clinical Research Ethics Committee (Joint CUHK-NTEC CREC Ref 2017.376). The requirement for patient consent was waived by the committee.

中文摘要

侵襲性乳腺癌新發病例的腋下淋巴結術前超聲檢查

黃健開、李恩年、任啟豪、譚家盈、譚國輝、鄧珮儀

目的：評估侵襲性乳腺癌新發病例的同側腋下淋巴結轉移的超聲影像特徵和細針抽吸檢查。

方法：回顧性分析2014年1月至2016年12月於一所放射科受檢的侵襲性乳腺癌新發病例的同側腋下淋巴結超聲影像特徵。在449項腋下檢查中，對355名乳腺癌病人的362項同時備有可供查閱的超聲影像及外科組織病理診斷結果或細針抽吸細胞學陽性結果的病例進行了分析， 包括腋下淋巴結定性形態評估和定量測量。

結果：淋巴結及其皮質的各種大小、面積及比例與淋巴結轉移相關（$p < 0.001$），其中以皮質最大厚度相關最為顯著。使用四級評分方法評估超聲影像，包括局部淋巴結皮質增厚、淋巴結門移位或侵犯及淋巴結周邊浸潤，此評分方法與淋巴結轉移顯著相關（$p < 0.001$），敏感性為65.2%（95%置信區間：58.2%-71.8%），特異性為96.9%（95%置信區間：92.9%-99.0%）。以外科組織病理診斷結果為參考標準，超聲引導細針抽吸細胞學診斷對腋下淋巴結轉移顯示中等敏感性（74.7%，95%置信區間：63.3%-84.0%）及高度特異性100%（95%置信區間：92.3%-100%）。

結論：腋下超聲波檢查有助侵襲性乳癌患者的術前淋巴結分期。超聲波引導細針抽吸細胞學為淋巴結轉移提供高特異度信息。

INTRODUCTION

Axillary ultrasound is an indispensable part of preoperative imaging for suspected breast cancer. Surgical management of the axilla, whether by sentinel lymph node biopsy (SLNB) or axillary lymph node dissection (ALND), depends on the identification of metastatic axillary lymph nodes by ultrasound and ultrasound-guided fine needle aspiration cytology (FNAC). Patients with operable breast tumour with unfavourable prognostic factors undergo ALND at the initial breast surgery. Early breast cancer patients with T1 or T2 disease without evidence of axillary metastasis undergo SLNB to determine the axillary nodal status to decide for ALND.[1] Preoperative accurate identification of metastatic axillary lymph nodes by sonographic features and accurate targeting of axillary lymph node for FNAC potentially eliminates the need for SLNB and a second axillary procedure for full ALND.[2] Moreover, the false-negative rate of SLNB is approximately 8.4%,[2] which could potentially be reduced with preoperative ultrasound. Despite the importance of axillary staging and sonography, there is no existing standard or consensus on the sonographic criteria of metastatic lymph nodes.[3]

The objective of the present study was to identify sonographic features of the axillary lymph nodes of patients with invasive breast cancer which could be associated with axillary metastasis.

METHODS

This was a single-centre retrospective study of patients who had newly diagnosed invasive breast cancer and received ultrasonography of the breast and the ipsilateral axilla from January 2014 to December 2016 at the Department of Radiology, North District Hospital, Hong Kong.

This study was approved by the Joint Chinese University of Hong Kong–New Territories East Cluster Clinical Research Ethics Committee The requirement of informed consent for the study was waived. All clinical investigations were conducted in accordance with the principles expressed in the Declaration of Helsinki. All patient records were anonymised and de-identified prior to analysis.

Background clinical information and demographic data were obtained through a search from the hospital electronic patient record and radiology information system. Patients with invasive breast cancer confirmed by imaging-guided core biopsy histology results, or subsequent surgical histopathology were included.

Patients with only non-invasive or non-primary breast tumours, or presented with recurrent or residual invasive breast cancer were excluded.

Ultrasound images were obtained from a Logiq E9 ultrasound machine (GE Healthcare GmbH, Solingen, Germany) with a high-frequency 11-15 MHz linear array transducer, or an iU22 (Philips Medical Systems, Bothell, Washington, US) or HDI 5000 (Philips Medical Systems) ultrasound machine with a high-frequency 6-15 MHz linear array transducer. Axillary ultrasonography to detect abnormal lymph nodes was routinely performed for all patients with breast imaging, particularly for the patients with lesions suspicious of malignancy (Breast Imaging Reporting and Data System category 4 or 5).[4] The axilla was scanned from level I of the axilla to higher axillary groups, and to the infraclavicular and supraclavicular regions sequentially, if suspicious-looking lymph nodes were found at a lower level. The number of suspicious lymph nodes was estimated. If considered indicated, ultrasound-guided FNAC of the targeted lymph node was performed in the same setting using 21- or 22-gauge hypodermic needle. A cytological smear was prepared and fixed in alcohol. The system was rinsed with 10% formalin solution for subsequent cell block preparation by the pathology department.

Ultrasound images of the ipsilateral axillae with the invasive cancer were reviewed using OsiriX (Pixmeo SARL, Bernex, Switzerland) or Carestream PACS Client Suite (Carestream Inc, Rochester, New York, US) by two consultant radiologists who had more than 10 years of experience in breast imaging. They were blinded to the subsequent cytological or histopathological results of the axillae. The images and measurements of the most suspicious ipsilateral axillary lymph nodes were chosen for analysis.

The ultrasound-guided FNAC and surgical histopathology results were obtained from electronic patient records. Surgical histopathology results obtained after neoadjuvant chemotherapy were excluded from the analysis.

Qualitative Assessment of the Axillary Lymph Nodes

The horizontal and vertical dimensions of lymph nodes were measured, and the ratio between the two was calculated. The maximal cortical thickness was measured according to the schematic representations by Deurloo et al[5] and Abe et al.[6] It could also be defined as the maximal thickness in a transverse plane perpendicular to the long axis of the lymph node as described by Saffar et al[7] (Figure 1). The vertical dimension of hilum-replaced lymph nodes was considered as equal to its cortical thickness. The ratio of the maximal cortical thickness to the vertical dimension of the lymph node was calculated. The area of the lymph node as displayed on the sonographic image was measured. The area of the cortex was calculated by subtracting the area of the lymph node from that of the hilum. The ratio of the area of the cortex to the area of the node was calculated.

Morphological Assessment of the Axillary Lymph Node

The lymph node morphology was classified using a 4-point grading scale, which was developed with reference to previous literature and studies.[8-12] Lymph nodes with no suspicion (Group 1) were defined as those with smooth regular thin cortex (<3 mm) and a central echogenic hilum without compression or displacement. Lymph nodes with intermediate suspicion (Group 2) were defined as those with diffuse cortical thickening (≥3 mm) and a preserved central echogenic hilum. There might be minor surface lobulations or lobulations which follow the contour of central hilum. Lymph nodes with high suspicion (Group 3) were defined as those with focal cortical thickening (≥3 mm), as evidenced by focal lobulation or bulging of the cortical outer contour, which did not follow the contour of the central hilum. There might be focal indentation or erosion into the echogenic central hilum. Lymph nodes with very high suspicion (Group 4) were defined as those with severe displacement

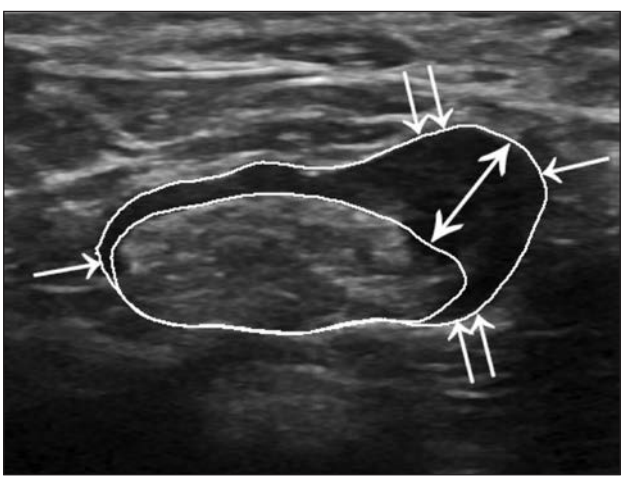

Figure 1. Schematic diagram of the quantitative measurements of the lymph node dimensions (horizontal dimension: in between → and ← arrows; vertical dimension: in between ↓↓ and ↑↑ arrows), and the maximal cortical thickness (↕ arrow).

and compression of the fatty hila, or complete hilar replacement. Lymph nodes with microcalcifications, or irregular shape with perinodal infiltration were also included.

The demographic data, quantitative measurements, and morphological descriptions were correlated with the FNAC results, surgical histopathology results, and combined results of FNAC and histopathology results. In the surgical histopathology result, axillary lymph nodes with isolated tumour cells were considered as negative for axillary metastasis, while those with micrometastasis were considered positive.[13]

Statistical Analysis

The statistical analysis was performed using SPSS (Windows version 24.0; IBM Corp, Armonk [NY], US). Descriptive statistics were reported as range, median, and interquartile range where appropriate. The statistical significance of the association of the independent variables with nodal status was determined using Pearson Chi squared test for categorical variables. Results with $p \leq 0.05$ were considered significant. Receiver operating characteristic (ROC) curve analysis was performed to evaluate and compare the performance of various quantitative measurements. Sensitivity and specificity were calculated for selected cut-off values. The 95% confidence interval (95% CI) for proportions, such as sensitivity and specificity, were calculated using the Clopper-Pearson exact method.

RESULTS

There were 449 axillae ipsilateral to proven invasive breast cancer identified from 435 patients; 14 patients had bilateral cancer. 55 axillae with neither a cytology result nor a valid surgical histopathology result were excluded. 18 axillae with no surgical histopathology result but with reactive, indeterminate, or insufficient material FNAC results were also excluded to avoid the risk of a false negative node. A further 14 axillae were excluded with no sonographic images of the axillary lymph node available for review (Figure 2).

A total of 355 patients with 362 axillae were analysed (Table 1). 354 (99.7%) patients were female and one patient (0.3%) was male. The age of the patients ranged from 27 to 93 years (mean, 60.9 years). 186 (51.4%) left axillae and 176 (48.6%) right axillae were included. Clinical tumour size, defined by the greatest dimension of the tumour by imaging, ranged from 4 to 140 mm (median, 29 mm); 96 (26.5%) tumours were ≤20 mm,

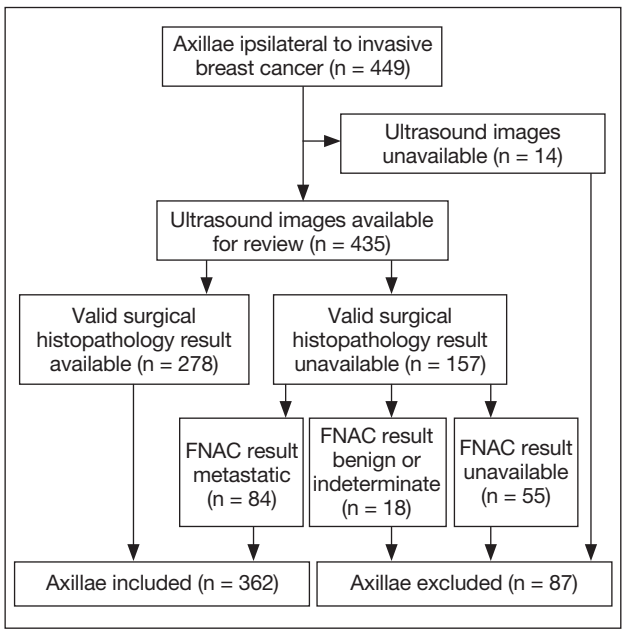

Figure 2. Flowchart showing the inclusion criteria with reference to FNAC and surgical histopathological results.
Abbreviation: FNAC = fine needle aspiration cytology.

195 (53.9%) were 21-50 mm, and 71 (19.6%) were >50 mm. More than half of the primary breast tumours were of clinical stage T2 (51.1%). The majority of the primary breast tumours were invasive ductal carcinoma (n = 334, 92.3%). 36 (9.9%) of the axillae were associated with metastatic disease.

There were 278 (76.7%) surgical histopathological results of axilla available. The duration from the axillary ultrasonography to the axillary SLNB or full dissection ranged from 7 to 124 days (median, 36 days). Of the primary breast tumours with available surgical histopathology result, 133 (47.8%) were of modified Bloom-Richardson grade 2 and 140 (50.4%) were of pathological stage T2. 117 (42.1%) of the axillae were positive and 161 (57.9%) were negative for metastasis (including those with isolated tumour cells). Of the positive axillae, 36 (30.8%) of them contained one metastatic node, 21 (17.9%) contained two metastatic nodes, and 60 (51.3%) contained three or more metastatic nodes.

Among the 278 (76.7%) surgical histopathological results of axillary nodal status available, 121 out of 278 (43.5%) preoperative ultrasound-guided FNAC of the axillary lymph nodes were performed. Taking the surgical histopathological result as the reference

Table 1. Patient demographics and breast tumour characteristics.*

Characteristics	Data
Age (n = 355)	
Median (range) [years]	60 (27-93)
Sex (n = 355)	
Female	354 (99.7%)
Male	1 (0.3%)
Tumour laterality (n = 362)	
Left breast	186 (51.4%)
Right breast	176 (48.6%)
Tumour size by imaging (n = 362)	
≤20 mm	96 (26.5%)
21-50 mm	195 (53.9%)
>50 mm	71 (19.6%)
Clinical T stage (n = 362)	
T1	96 (26.5%)
T2	185 (51.1%)
T3	50 (13.8%)
T4	31 (8.6%)
Histological tumour type (n = 362)	
Invasive ductal carcinoma	334 (92.3%)
Mucinous carcinoma	8 (2.2%)
Papillary carcinoma with stromal invasion	2 (0.6%)
Invasive lobular carcinoma	11 (3.0%)
Angiosarcoma	1 (0.3%)
Metaplastic carcinoma	4 (1.1%)
Mixed invasive ductal and lobular carcinoma	2 (0.6%)
Modified Bloom-Richardson grading (n = 278)	
Grade 1	54 (19.4%)
Grade 2	133 (47.8%)
Grade 3	78 (28.1%)
Unknown	13 (4.7%)
Pathological T stage (n = 278)	
T1	115 (41.4%)
T2	140 (50.4%)
T3	13 (4.7%)
T4	10 (3.6%)
Pathological N stage (n = 278)	
N0 (including isolated tumour cells, N0[i+])	161 (57.9%); (N0[i+]: 11 [4.0%])
N1 (including micrometastasis, N1mi)	71 (25.5%); (N1mi: 14 [5.0%])
N2	32 (11.5%)
N3	14 (5.0%)
No. of metastatic node (n = 117)	
1	36 (30.8%)
2	21 (17.9%)
≥3	60 (51.3%)
Metastasis (n = 362)	
M0 or unknown	326 (90.1%)
M1	36 (9.9%)

* Data are shown as No (%), unless otherwise specified.

standard, the ultrasound-guided FNAC showed the results of 56 (46.3%) true-positive, 46 (38.0%) true-negative, 19 (15.7%) false-negative, and 0 (0%) false-positive. The sensitivity, specificity, positive predictive value and negative predictive value were 74.7% (95% CI = 63.3%-84.0%), 100% (95% CI = 92.3%-100%), 100% (95% CI = 93.6%-100%), and 70.8% (95% CI = 58.2%-81.4%), respectively (Table 2).

There were 84 (23%) axillae with positive FNAC result without available histopathology results. Of them, 81 had metastatic cells present and three had cells suspicious for metastasis. All FNAC of the axillary lymph nodes were performed at the same setting with the axillary ultrasonography.

The presence of axillary metastasis was significantly associated with a larger tumour size ($p < 0.001$) [Table 3], invasive ductal carcinoma as the histology of the primary breast tumour ($p = 0.028$) [Table 4], and a higher tumour grade ($p = 0.001$) [Table 5].

Quantitative Measurements

All eight quantitative measurements investigated showed statistically significant association with the nodal status of FNAC and surgical histopathology ($p < 0.001$) [Figure 3]. Higher values of lymph node horizontal and vertical dimensions, ratio of lymph node vertical to horizontal dimensions, lymph node area, maximal cortical thickness, ratio of maximal cortical thickness to lymph node vertical dimension, cortex area, and ratio of cortex area to lymph node area were associated with axillary metastatic disease. In ROC curve analysis of the eight quantitative measurements, the area under the ROC curve ranged from 0.653 to 0.871 (Table 6), with the maximal cortical thickness showing superior performance than other measurements. At the maximal cortical thickness cut-off values of 2.3 mm, 2.5 mm and 3.0 mm, the sensitivity values were 85.6%, 83.1% and 81.1%, respectively; and specificity values were 65.8%, 68.9% and 77.6%, respectively (Table 7).

Table 2. Fine needle aspiration cytological and surgical histological results of the axillary lymph nodes.

Fine needle aspiration cytology nodal status	Surgical histopathology nodal status			
	Positive	Negative	Not available	Total
Positive (metastatic / suspicious)	56	0	84	140
Negative (reactive / indeterminate / atypia)	19	46	*	65
Not available	42	115	*	157
Total	117	161	84	362

* Excluded from the study.

Morphological Assessment

Using the 4-point grading system (Figures 4 to 7, Table 8), nodal status was significantly positively associated with higher grade of lymph node morphology ($p < 0.001$). Positive nodal status was found in 23.3% of the low suspicion group (Group 1), 50.8% of the intermediate suspicion group (Group 2), 89.7% of the high suspicion group (Group 3), and 98.1% of the very high suspicion group (Group 4). Considering Groups 1 and 2 as the sonographic negative group and Groups 3 and 4 as the sonographic positive group, the sensitivity, specificity, positive predictive value and negative predictive value were 65.2% (95% CI = 58.2%-71.8%), 96.9% (95% CI = 92.9%-99.0%), 96.3% (95% CI = 91.6%-98.8%) and 69.0% (95% CI = 62.3%-75.0%), respectively. The single feature of the absence of central hilum showed a specificity of 98.8% (95% CI = 95.6%-99.9%) and a sensitivity of 34.8% (95% CI = 28.3%-41.9%). All nine lymph nodes with microcalcification were positive for metastases.

The positive FNAC result was significantly positively associated with a higher morphological grade, with a positive node found in 9.1% of the low suspicion group

Table 3. Correlation of size of the primary breast tumour with nodal status.*

Tumour size by imaging	Nodal status	
	Positive (n = 201)	Negative (n = 161)
≤20 mm (n = 96)	29 (30.2%)	67 (69.8%)
21-50 mm (n = 195)	110 (56.4%)	85 (43.6%)
>50 mm (n = 71)	62 (87.3%)	9 (12.7%)

* Data are shown as No (%).

Table 4. Correlation of tumour histology (status of invasive ductal carcinoma) with nodal status.*

Tumour histology	Nodal status	
	Positive (n = 201)	Negative (n = 161)
IDC (n = 334)	191 (57.2%)	143 (42.8%)
Non-IDC (n = 28)	10 (35.7%)	18 (64.3%)
Mucinous carcinoma	1	7
Papillary carcinoma	1	1
Invasive lobular carcinoma	5	6
Angiosarcoma	1	0
Metaplastic carcinoma	0	4
Mixed invasive ductal and lobular carcinoma	2	0

Abbreviation: IDC = invasive ductal carcinoma.
* Data are shown as No (%).

Table 5. Correlation of tumour grade (modified Bloom-Richardson grading of surgical histopathology with nodal status.*

Tumour grade	Nodal status		Total†
	Positive (n = 116)	Negative (n = 149)	
Grade 1	15 (27.8%)	39 (72.2%)	54 (100%)
Grade 2	55 (41.4%)	78 (58.6%)	133 (100%)
Grade 3	46 (59.0%)	32 (41.0%)	78 (100%)

* Data are shown as No (%).
† Among 278 axillae with valid surgical histopathology result available,. the tumour grade (modified Bloom-Richardson) of 13 invasive breast tumours was unknown.

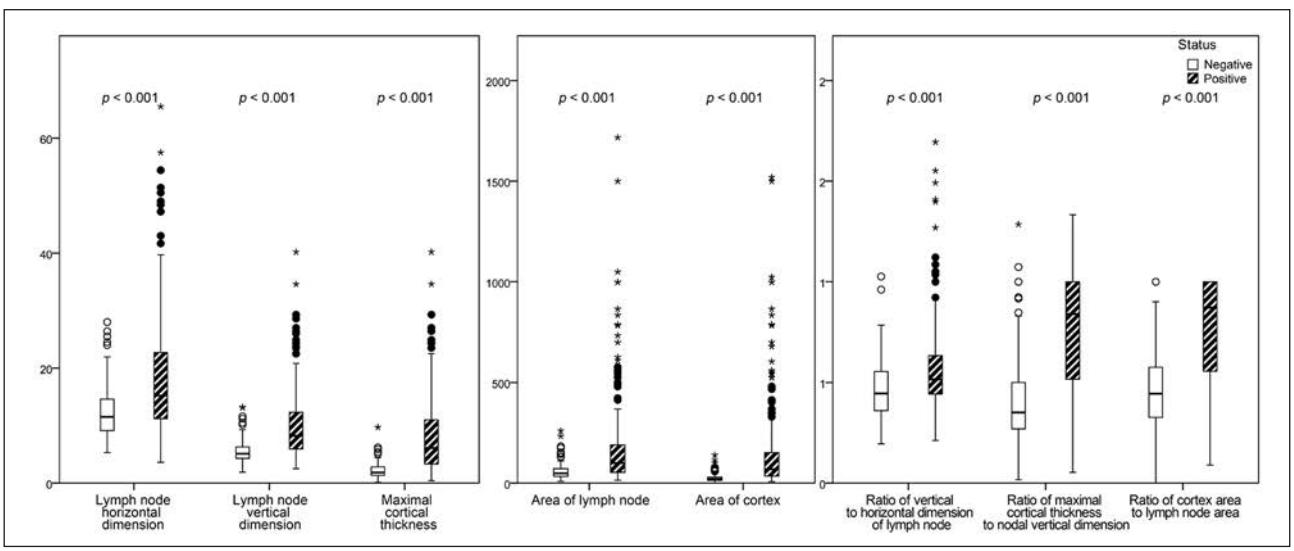

Figure 3. Boxplot of quantitative measurements of lymph nodes with correlation to the nodal status.

Table 6. Receiver operating characteristic (ROC) curve analysis of the association of quantitative measurements of lymph node with nodal status.

	ROC curve analysis		p Value
	Area under curve	95% Confidence interval	
Lymph node horizontal dimension	0.694	0.641-0.747	<0.001
Lymph node vertical dimension	0.796	0.750-0.841	<0.001
Maximal cortical thickness	0.871	0.835-0.908	<0.001
Area of lymph node	0.745	0.695-0.795	<0.001
Area of cortex	0.841	0.801-0.881	<0.001
Ratio of lymph node vertical to horizontal dimensions	0.653	0.597-0.710	<0.001
Ratio of maximal cortical thickness to lymph node vertical dimension	0.829	0.786-0.871	<0.001
Ratio of cortex area to lymph node area	0.829	0.787-0.871	<0.001

Table 7. Selected cut-off points and diagnostic utility of maximal cortical thickness for identifying positive axillary status.

	Sensitivity		Specificity	
	%	95% confidence interval	%	95% confidence interval
≥1.5 mm	95.0	91.0-97.6	33.5	26.3-41.4
≥2.0 mm	88.6	83.3-92.6	55.9	47.9-63.7
≥2.3 mm	85.6	79.9-90.1	65.8	58.0-73.1
≥2.5 mm	83.1	77.2-88.0	68.9	61.2-76.0
≥3.0 mm	81.1	75.0-86.3	77.6	70.4-83.8
≥3.5 mm	73.6	67.0-79.6	88.8	82.9-93.2
≥4.0 mm	69.2	62.3-75.5	93.2	88.1-96.5
≥4.5 mm	64.2	57.1-70.8	96.9	92.9-99.0
≥5.0 mm	61.7	54.6-68.4	96.9	92.9-99.0

(Group 1), 35.9% of the intermediate suspicion group (Group 2), 73.7% of the high suspicion group (Group 3), and 83.3% of the very high suspicion group (Group 4) [$p < 0.001$] (Table 9).

Although non-significant, there seemed a trend for a higher FNAC false negative rate in the higher morphological grade group, with the rate ranged from 26.7% in Group 1 lymph nodes to 60.0% in Group 4 lymph nodes ($p = 0.23$) [Table 10].

DISCUSSION

The assessment of axillary lymph node status in patients with newly diagnosed invasive breast cancer is vital in the initial staging of breast cancer.[9] Preoperative staging of the axilla is recommended for breast cancer patients in different guidelines.[14-16] Physical examination and mammography have poor accuracy,[17-22] whereas computed tomography, positron emission tomography/computed tomography, and magnetic resonance imaging are not in routine use.[1,23] Axillary ultrasound is commonly used as the imaging modality of choice as it is readily available and non-invasive. It provides high-

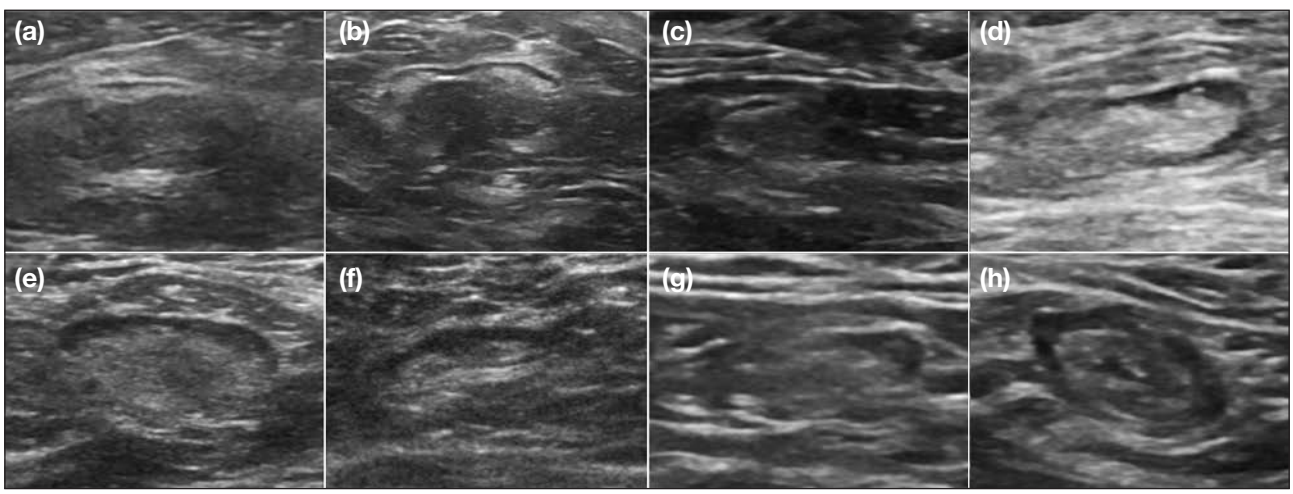

Figure 4. Ultrasound images of selected lymph nodes in the low suspicion group (Group 1), which were those with smooth regular thin cortex (<3 mm) and a central echogenic hilum without compression or displacement. Hypoechoic areas in the central hilum were demonstrated in Figure 4a to c, which may be due to composition consisting of mostly homogeneous fat cells and relatively scanty vessels.

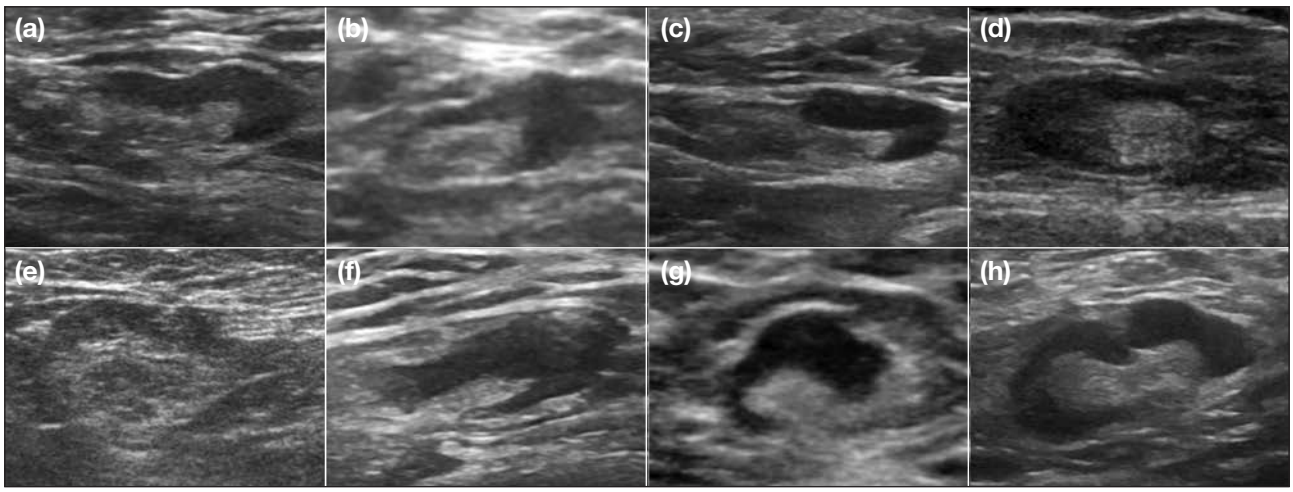

Figure 5. Ultrasound images of selected lymph nodes in the intermediate suspicion group (Group 2), which were those with diffuse uniform cortical thickening (≥3 mm) and a preserved central echogenic hilum. There might be minor surface lobulations or lobulations which follow the contour of central hilum.

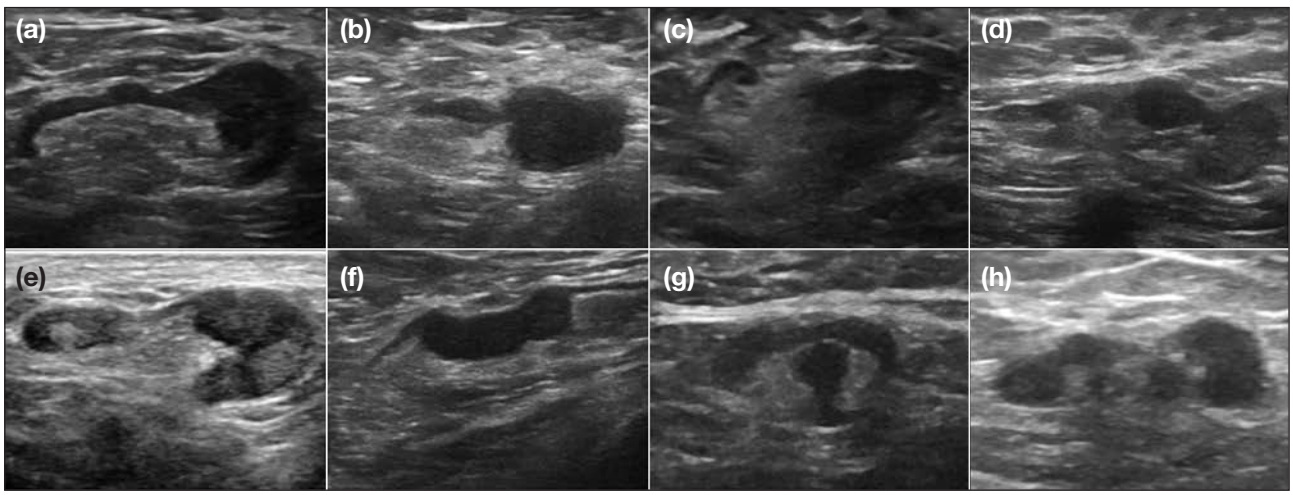

Figure 6. Ultrasound images of selected lymph nodes in the high suspicion group (Group 3), which were those with focal cortical thickening (≥3 mm), as evidenced by focal lobulation or bulging of the cortical outer contour (Figure 6a to d), which did not follow the contour of the central hilum. There might be focal indentation (Figure 6e and f) or erosion (Figure 6g and h) into the echogenic central hilum. No severe hilar compression or displacement was evident.

quality images[24] that enable quantitative and qualitative morphological assessment as well as guiding biopsy or FNAC of abnormal or suspicious axillary lymph nodes at the same setting.[25] Scanning of higher nodal levels, including axillary level II and III, supraclavicular, and internal mammary nodes are feasible especially in patients with multiple suspicious level I axillary nodes or high clinical cancer stage.

Positive axillary nodal status was found to be associated with a larger tumour size and a higher histological grade of the breast tumours in our study, which was consistent with the findings in the literature.[7,17,20,26] In addition, previous studies have also shown that other primary tumour characteristics are associated with positive nodal status, including higher clinical stage,[20,27] outer quadrants[28] or central location,[7] and multiplicity of tumour in one breast.[7]

Nodal metastasis occurs when tumour cells enter the nodes through the afferent lymphatic channels and get arrested in the subcapsular sinusoids.[1,9] This correlates with the observation of focal or eccentric cortical lobulation as the earliest sonographic visible change

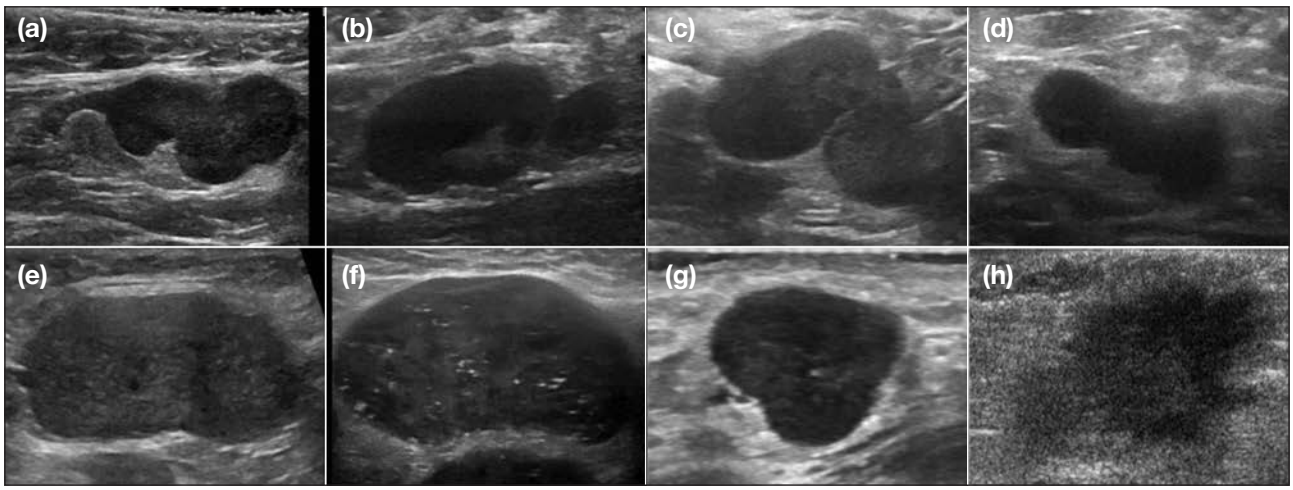

Figure 7. Ultrasound images of selected lymph nodes in the very high suspicion group (Group 4), which were those with severe displacement and compression of the fatty hila (Figure 7a to d), or replacement of the fatty hila (Figure 7e to h). Lymph nodes with microcalcifications (Figure 7f), or irregular shape with perinodal infiltration (Figure 7h) were included in this group.

Table 8. Morphological assessment of lymph node using a 4-point grading scale with correlation to nodal status.*

Morphological assessment of lymph node with grading scale	Nodal status		
	Positive (n = 201)	Negative (n = 161)	Total (n = 362)
Low suspicion (Group 1)	38 (23.3%)	125 (76.7%)	163 (100%)
Intermediate suspicion (Group 2)	32 (50.8%)	31 (49.2%)	63 (100%)
High suspicion (Group 3)	26 (89.7%)	3 (10.3%)	29 (100%)
Very high suspicion (Group 4)	105 (98.1%)	2 (1.9%)	107 (100%)

* Date are shown as No (%).

Table 9. Morphological assessment of lymph node using a 4-point grading scale with correlation to nodal status as determined by fine needle aspiration cytology result.*

Morphological assessment of lymph node with grading scale	Nodal status (fine needle aspiration cytology result)		
	Positive (n = 56)	Negative (n = 65)	Total (n = 121)
Low suspicion (Group 1)	3 (9.1%)	30 (90.9%)	33 (100%)
Intermediate suspicion (Group 2)	14 (35.9%)	25 (64.1%)	39 (100%)
High suspicion (Group 3)	14 (73.7%)	5 (26.3%)	19 (100%)
Very high suspicion (Group 4)	25 (83.3%)	5 (16.7%)	30 (100%)

* Date are shown as No (%).

for metastatic nodes.[1,9,29,30] Increasing nodal infiltration results in further focal or diffuse thickening of the cortex, indentation or replacement of the hilum and finally

Table 10. Proportion of true and false negative fine needle aspiration cytology result with surgical histopathology as reference standard and its association with morphological assessment using a 4-point grading scale.*

Morphological assessment of lymph node with grading scale	Negative fine needle aspiration cytology result		
	True negative (n = 46)	False negative (n = 19)	Total (n = 65)
Low suspicion (Group 1)	22 (73.3%)	8 (26.7%)	30 (100%)
Intermediate suspicion (Group 2)	19 (76.0%)	6 (24.0%)	25 (100%)
High suspicion (Group 3)	3 (60.0%)	2 (40.0%)	5 (100%)
Very high suspicion (Group 4)	2 (40.0%)	3 (60.0%)	5 (100%)

* Date are shown as No (%).

extranodal deposits as an irregular mass in the axilla.[30] To identify the possible nodal metastasis, various sonographic criteria based on quantitative measurement and morphology assessment are investigated.

With the insight from the pathophysiology, it is reasonable that maximal cortical thickness was the most commonly utilised parameter in quantitative measurement to identify metastatic lymph nodes. Most studies[7,12,31,32] recommended 3 mm as the threshold, which showed the sensitivity from 56% to 88% and the specificity from 64% to 75%. Our study with 3 mm as threshold showed the sensitivity of 81.1% and the specificity of 77.6%. Deurloo et al[5] recommended the threshold of 2.3

mm with sensitivity 95% and specificity 44%, to reduce the proportion of missed metastatic node. Cho et al[18] recommended 2.5 mm as the threshold with sensitivity 85% and specificity 78%. Abe et al[6] defined suspicious nodes as those with a maximal cortical thickness greater than the vertical dimension of lymph node, which showed the sensitivity of 79% and the specificity of 64%.

In our study, maximal cortical thickness showed superior performance when compared with other quantitative measurements of the entire lymph node, and other ratios and measurement of the cortex. The cortical measurements in general performed better than the nodal measurements as shown in the result. This was consistent with previous studies, showing the inferior accuracy of using lymph node size or length in determining nodal status.[5,11,30,32]

More commonly applied than quantitative assay is the morphological criteria in assessing nodal metastasis. The spectrum of morphological changes of lymph node described by Stavros[11] focused on the cortex of the lymph node. There were eight morphological descriptions ranging from normal, concentric cortical thickening, eccentric cortical thickening, hilar indentation, to severe hilar compression and displacement, and eventually replaced hilum with a rounded nodal contour and perinodal invasion. Subsequent studies integrated cortical thickness measurement in the morphological grading systems. An in-vitro sonographic study[9] recommended a 6-point grading system, ranging from imperceptible cortex, thin cortex, uniform cortex thicker than 3 mm, generalised cortical lobulations following hilar contour, to focal lobulation and hilar replacement. To simplify, many studies use a 3- to 4-point grading system,[8,10,25,31,33] based on the morphological cortical changes coupled with cortical thickness. Those studies showed a sensitivity of 56.3% to 91.2% and specificity of 53.1% to 80.8%. A meta-analysis has shown that studies of non-palpable axillary nodes utilising morphological criteria appeared to have higher specificity values (range, 88.4%-98.1%) than do those utilising size criteria (range, 55.6%-97.3%).[34] In both groups, the sensitivity values were variable. For morphological criteria studies, the sensitivity values ranged from 26.4% to 79.5%, and for size criteria studies, from 48.8% to 87.1%. Our study adopted a 4-point grading system to predict metastatic nodal status and showed moderate sensitivity (65.2%) and high specificity (96.9%) in highly and very highly suspicious grading groups (Group 3 and 4). A previous study of a 6-point grading system identified an interobserver agreement of 88% for characterisation of a node as benign or malignant.[9]

Sonographic criteria were not completely reliable in differentiating benign from malignant nodes. Ultrasound-guided FNAC might offer additional information on positive metastatic status with specificity improvement to 94.8% to 100%.[34] In our study, ultrasound-guided FNAC showed moderate sensitivity 74.7% and high specificity 100% for positive nodal status. In practice, the lymph node with the most suspicious feature and with maximal cortical thickness >3 mm should be selected for aspiration. The nodal cortex with maximal thickness or bulging should be the target of the aspiration to improve the positive yield. Axillary lymph nodes associated with a larger size, higher grading, and ductal histology of the primary tumour should be viewed with a higher suspicion, as these criteria were associated with positive nodal status. Although not statistically significant, the false negative rate of FNAC was shown to have a trend which increased with higher morphological grade. The discordant negative FNAC result in morphologically highly suspicious lymph node should be interpreted with caution.

The current trend of minimising axillary intervention raises uncertainty on the role of preoperative axillary staging in early tumour with clinically negative axilla. The American College of Surgeons Oncology Group Z0011 trial[35] found that ALND showed no additional benefit for women with T1/T2 tumours with only one or two positive lymph nodes with no extracapsular extension in SLNB, noting that all these patients received adjuvant chemotherapy and whole breast irradiation after conservative breast surgery. The European Organization for Research and Treatment of Cancer AMAROS trial[36] showed that in patients with T1/T2 tumours, no palpable lymphadenopathy, and a positive sentinel node, radiotherapy of the axillae was non-inferior to ALND. This suggests a low need for preoperative axillary staging. Omitting FNAC or biopsy of indeterminate or less suspicious lymph nodes may be considered to avoid ALND in patients who meet the Z0011 trial eligibility criteria.[2,29]

European Institute of Oncology of Milan took another approach and evaluated the role of SLNB in patients of early breast cancer with no clinically palpable lymphadenopathy. In the ongoing SOUND (Sentinel node vs Observation after axillary UltraSouND) trial,[37] patients of breast cancer <2 cm and clinically negative

axilla treated with breast conserving surgery and radiotherapy are randomised to undergo SLNB (with or without ALND) or to receive no axillary surgery depending on a negative preoperative ultrasound with or without FNAC in case one doubtful node is found.

The role of ultrasound in preoperative axilla staging for early-stage tumour in post Z0011 era is in its evolutionary stage. It is essential for radiologists to work collaboratively with surgeons and patients, in the delivery of the most appropriate treatment.

Our study had limitations, including the retrospective nature, the small sample size and single-centre setting, the high proportion of T2 stage tumours of the present study, and axillae with negative FNAC results were excluded from the study. Further investigation with prospective multicentre studies could be more representative of the prevalence of different types and stages of breast cancer in this locality and improve the completeness of the data.

CONCLUSION

Axillary ultrasound plays an important role in the preoperative staging of lymph nodes of patients with invasive breast cancer. Familiarisation of nodal morphology and application of grading system facilitate the identification of suspicious axillary lymph nodes. Ultrasound-guided FNAC offers additional information of the nodal status and can improve specificity.

REFERENCES

1. Ecanow JS, Abe H, Newstead GM, Ecanow DB, Jeske JM. Axillary staging of breast cancer: what the radiologist should know. Radiographics. 2013;33:1589-612. Crossref
2. Humphrey KL, Saksena MA, Freer PE, Smith BL, Rafferty EA. To do or not to do: axillary nodal evaluation after ACOSOG Z0011 Trial. Radiographics. 2014;34:1807-16. Crossref
3. Stachs A, Göde K, Hartmann S, Stengel B, Nierling U, Dieterich M, et al. Accuracy of axillary ultrasound in preoperative nodal staging of breast cancer—size of metastases as limiting factor. SpringerPlus. 2013;2:350. Crossref
4. Mendelson EB, Böhm-Vélez M, Berg WA, Whitman GJ, Feldman MI, Madjar H. ACR BI-RADS® Ultrasound. In: ACR BI-RADS® Atlas, Breast Imaging Reporting and Data System. 5th ed. Reston, VA, American College of Radiology; 2013. p 1-73.
5. Deurloo EE, Tanis PJ, Gilhuijs KG, Muller SH, Kröger R, Peterse JL, et al. Reduction in the number of sentinel lymph node procedures by preoperative ultrasonography of the axilla in breast cancer. Eur J Cancer. 2003;39:1068-73. Crossref
6. Abe H, Schmidt RA, Kulkarni K, Sennett CA, Mueller JS, Newstead GM. Axillary lymph nodes suspicious for breast cancer metastasis: sampling with US-guided 14-gauge core-needle biopsy—clinical experience in 100 patients. Radiology. 2009;250:41-9. Crossref
7. Saffar B, Bennett M, Metcalf C, Burrows S. Retrospective preoperative assessment of the axillary lymph nodes in patients with breast cancer and literature review. Clin Radiol. 2015;70:954-9. Crossref
8. Rocha RD, Girardi AR, Pinto RR, de Freitas VA. Axillary ultrasound and fine-needle aspiration in preoperative staging of axillary lymph nodes in patients with invasive breast cancer. Radiol Bras. 2015;48:345-52. Crossref
9. Bedi DG, Krishnamurthy R, Krishnamurthy S, Edeiken BS, Le-Petross H, Fornage BD, et al. Cortical morphologic features of axillary lymph nodes as a predictor of metastasis in breast cancer: in vitro sonographic study. AJR Am J Roentgenol. 2008;191:646-52. Crossref
10. De Coninck C, Noël JC, Boutemy R, Simon P. Preoperative axillary lymph node staging by ultrasound-guided cytology using a four-level sonographic score. BMC Med Imaging. 2016;16:13. Crossref
11. Stavros AT. Evaluation of regional lymph nodes in breast cancer patients. In: Stavros AT, editor. Breast Ultrasound. Philadelphia: Lippincott; 2004. p 834-76.
12. Amonkar SJ, Oates E, McLean L, Nicholson S. Pre-operative staging of the axilla in primary breast cancer. By redefining the abnormal appearing node can we reduce investigations without affecting overall treatment? Breast. 2013;22:1114-8. Crossref
13. Compton CC, Byrd DR, Garcia-Aguilar J, Kurtzman SH, Olawaiye A, Washington MK. AJCC Cancer Staging Atlas: a companion to the seventh editions of the AJCC cancer staging manual and handbook. Springer: New York; 2012. Crossref
14. Senkus E, Kyriakides S, Ohno S, Penault-Llorca F, Poortmans P, Rutgers E, et al. Primary breast cancer: ESMO Clinical Practice Guidelines for diagnosis, treatment and follow-up. Ann Oncol. 2015;26 Suppl 5:v8-30. Crossref
15. The National Institute for Health and Clinical Excellence. Early and locally advanced breast cancer: diagnosis and treatment. March 2017. Available from: https://www.nice.org.uk/guidance/cg80. Accessed 7 Aug 2017.
16. Federatie Medisch Specialisten. Preoperative and ultrasound of the axilla as triage test for SN procedure (breast cancer). Available from: https://richtlijnendatabase.nl/en/richtlijn/breast_cancer/diagnostics/preoperative_staging/triage_testing_for_sn_procedure.html. Accessed 7 Aug 2017.
17. Ertan K, Linsler C, di Liberto A, Ong MF, Solomayer E, Endrikat J. Axillary ultrasound for breast cancer staging: an attempt to identify clinical/histopathological factors impacting diagnostic performance. Breast Cancer (Auckl). 2013;7:35-40. Crossref
18. Cho N, Moon WK, Han W, Park IA, Cho J, Noh DY. Preoperative sonographic classification of axillary lymph nodes in patients with breast cancer: node-to-node correlation with surgical histology and sentinel node biopsy results. Am J Roentgenol. 2009;193:1731-7. Crossref
19. van Rijk MC, Deurloo EE, Nieweg OE, Gilhuijs KG, Peterse JL, Rutgers EJ, et al. Ultrasonography and fine-needle aspiration cytology can spare breast cancer patients unnecessary sentinel lymph node biopsy. Ann Surg Oncol. 2006;13:31-5. Crossref
20. Lee MC, Joh JE, Chau A. Axillary staging prior to neoadjuvant chemotherapy: the roles of sentinel lymph node biopsy and axillary ultrasonography. Cancer Control. 2012;19:277-85. Crossref
21. Lanng C, Hoffmann J, Galatius H, Engel U. Assessment of clinical palpation of the axilla as a criterion for performing the sentinel node procedure in breast cancer. Eur J Surg Oncol. 2007;33:281-4. Crossref
22. Pamilo M, Soiva M, Lavast EM. Real-time ultrasound, axillary mammography, and clinical examination in the detection of axillary lymph node metastases in breast cancer patients. J Ultrasound Med. 1989;8:115-20. Crossref
23. Rahbar H, Partridge SC, Javid SH, Lehman CD. Imaging axillary

lymph nodes in patients with newly diagnosed breast cancer. Curr Probl Diagn Radiol. 2012;41:149-58. Crossref
24. Britton PD, Goud A, Godward S, Barter S, Freeman A, Gaskarth M, et al. Use of ultrasound-guided axillary node core biopsy in staging of early breast cancer. Eur Radiol. 2009;19:561-9. Crossref
25. Duchesne N, Jaffey J, Florack P, Duchesne S. Redefining ultrasound appearance criteria of positive axillary lymph nodes. Can Assoc Radiol J. 2005;56:289-96.
26. Aitken E, Osman M. Factors affecting nodal status in invasive breast cancer: a retrospective analysis of 623 patients. Breast J. 2010;16:271-8. Crossref
27. Castellano I, Deambrogio C, Muscarà F, Chiusa L, Mariscotti G, Bussone R, et al. Efficiency of a preoperative axillary ultrasound and fine-needle aspiration cytology to detect patients with extensive axillary lymph node involvement. PLoS One. 2014;9:e106640. Crossref
28. Susini T, Nori J, Olivieri S, Molino C, Marini G, Bianchi S, et al. Predicting the status of axillary lymph nodes in breast cancer: a multiparameter approach including axillary ultrasound scanning. Breast. 2009;18:103-8. Crossref
29. Dialani V, James DF, Slanetz PJ. A practical approach to imaging the axilla. Insights Imaging. 2014;6:217-29. Crossref
30. Mainiero MB. Regional lymph node staging in breast cancer: the increasing role of imaging and ultrasound-guided axillary lymph node fine needle aspiration. Radiol Clin North Am. 2010;48:989-97. Crossref
31. Mainiero MB, Cinelli CM, Koelliker SL, Graves TA, Chung MA. Axillary ultrasound and fine-needle aspiration in the preoperative evaluation of the breast cancer patient: an algorithm based on tumor size and lymph node appearance. AJR Am J Roentgenol. 2010;195:1261-7. Crossref
32. Choi YJ, Ko EY, Han BK, Shin JH, Kang SS, Hahn SY. High-resolution ultrasonographic features of axillary lymph node metastasis in patients with breast cancer. Breast. 2009;18:119-22. Crossref
33. Fidan N, Ozturk E, Yucesoy C, Hekimoglu B. Preoperative evaluation of axillary lymph nodes in malignant breast lesions with ultrasonography and histopathologic correlation. J Belg Soc Radiol. 2016;100:58. Crossref
34. Alvarez S, Añorbe E, Alcorta P, López F, Alonso I, Cortés J. Role of sonography in the diagnosis of axillary lymph node metastases in breast cancer: a systematic review. AJR Am J Roentgenol. 2006;186:1342-8. Crossref
35. Giuliano AE, Hunt KK, Ballman KV, Beitsch PD, Whitworth PW, Blumencranz PW, et al. Axillary dissection vs no axillary dissection in women with invasive breast cancer and sentinel node metastasis: a randomized clinical trial. JAMA. 2011;305:569-75. Crossref
36. Donker M, van Tienhoven G, Straver ME, Meijnen P, van de Velde CJ, Mansel RE, et al. Radiotherapy or surgery of the axilla after a positive sentinel node in breast cancer (EORTC 10981-22023 AMAROS): a randomised, multicentre, open-label, phase 3 non-inferiority trial. Lancet Oncol. 2014;15:1303-10. Crossref
37. Gentilini O, Veronesi U. Abandoning sentinel lymph node biopsy in early breast cancer? A new trial in progress at the European Institute of Oncology of Milan (SOUND: Sentinel node vs Observation after axillary UltraSouND). Breast 2012;21:678-81. Crossref