
PERSPECTIVE

Four-Dimensional Computed Tomography for Localisation of Parathyroid Adenomas

HS Leung¹, SYW Liu², KT Wong¹, SM Yu¹, AD King¹

¹Department of Imaging and Interventional Radiology, Prince of Wales Hospital, Hong Kong SAR, China

²Department of Surgery, Prince of Wales Hospital, Hong Kong SAR, China

ABSTRACT

Primary hyperparathyroidism is a relatively common disorder with a myriad of end-organ manifestations, and surgical treatment remains the only curative option. Minimally invasive parathyroidectomy has replaced bilateral neck exploration as the standard technique for the majority of patients with solitary adenomas. Preoperative imaging is essential for accurate localisation of parathyroid adenomas. Four-dimensional computed tomography of the parathyroids has emerged as a useful problem-solving tool in the initial workup. This article reviews the underlying imaging principles, techniques, and practical tips on image interpretation and reporting, all of which are essential in successful preoperative localisation of parathyroid adenomas.

Key Words: Hyperparathyroidism; Hyperparathyroidism, primary; Parathyroid neoplasms; Parathyroidectomy

中文摘要

用於副甲狀腺腺瘤定位的四維電腦斷層掃描

梁皓生、廖玉華、黃嘉德、于雪梅、金雅桃

原發性副甲狀腺功能亢進症是一種相對常見的疾病，並會影響多重器官功能，手術治療仍然是唯一的治療選擇。微創副甲狀腺切除術已取代雙側頸部探查而成為用於大多數單一副甲狀腺腺瘤患者的標準技術。術前影像學檢查對於準確定位副甲狀腺腺瘤至關重要。副甲狀腺四維電腦斷層掃描已成為術前檢查中解決問題的有用工具。本文回顧基本成像原理、技術及圖像解釋和報告的實用技巧，以上均對術前定位至關重要。

Correspondence: Dr HS Leung, Department of Imaging and Interventional Radiology, Prince of Wales Hospital, Hong Kong SAR, China

Email: lhs655@ha.org.hk

Submitted: 5 Feb 2022; Accepted: 17 May 2022.

Contributors: HSL and KTW designed the study. HSL, KTW and SMY acquired the data. HSL and SMY analysed the data. HSL and ADK drafted the manuscript. SYWL, KTW, SMY and ADK critically revised the manuscript for important intellectual content. All authors had full access to the data, contributed to the study, approved the final version for publication, and take responsibility for its accuracy and integrity.

Conflicts of Interest: All authors have disclosed no conflicts of interest.

Funding/Support: This study received no specific grant from any funding agency in the public, commercial, or not-for-profit sectors.

Data Availability: All data generated or analysed during the present study are available from the corresponding author on reasonable request.

Ethics Approval: The study was approved by the Joint Chinese University of Hong Kong–New Territories East Cluster Clinical Research Ethics Committee (Ref No.: 2022.069). A waiver for obtaining patient consent was granted by the Committee due to the retrospective nature of the study.

INTRODUCTION

Primary hyperparathyroidism is a relatively common disorder with an average population prevalence of 0.3%.^{1,2} Long-term primary hyperparathyroidism with the accompanying hypercalcaemia may cause skeletal (pathological fractures), renal (nephrolithiasis, polyuria, and polydipsia), and gastrointestinal (peptic ulceration and pancreatitis) abnormalities. With more widespread use of biochemical screening in developed countries, the paradigm has shifted to an asymptomatic presentation, with or without elevated calcium levels.³⁻⁷

Surgical treatment remains the only curative option, with a shift in approach for the majority of patients with a solitary adenoma from bilateral neck exploration to minimally invasive parathyroidectomy (MIP),⁸ offering similar outcomes with reduction in complications and shorter postoperative recovery.^{8,9} Preoperative imaging localisation of the parathyroid glands is essential to a successful MIP. Traditionally achieved by ultrasound and/or technetium-99m (^{99m}Tc) sestamibi scintigraphy, in recent years four-dimensional computed tomography (4DCT) has emerged as a robust alternative modality, offering more accurate localisation.^{10,11} This article on 4DCT reviews the technique, practical guidelines, and tips on what to look for; diagnostic performance; and advantages/disadvantages compared with other imaging modalities.

INDICATIONS FOR PARATHYROID IMAGING

International guidelines¹²⁻¹⁴ have suggested that preoperative imaging for parathyroid localisation followed by parathyroidectomy is indicated when there is primary hyperparathyroidism together with any of the following conditions: (1) symptomatic hyperparathyroidism; (2) significantly elevated calcium levels (>1 mg/dL or 0.25 mmol/L above upper reference limit); (3) evidence of end-organ involvement, including renal (nephrocalcinosis, hypercalciuria, and impaired renal function) or skeletal (osteoporosis, fragility fractures as a manifestation of osteoporosis or vertebral insufficiency fractures); and (4) recurrent or persistent hyperparathyroidism after initial surgery.¹⁵

In addition, preoperative imaging followed by parathyroidectomy may also be considered when there is biochemical hyperparathyroidism in any of the following circumstances: (1) presence of neurocognitive or neuropsychiatric symptoms attributable to hyperparathyroidism¹⁶; (2) aged <50 years old, in

the absence of symptoms or evidence of end-organ involvement; and (3) inability or unwillingness to comply with follow-up protocols after the initial diagnosis of primary hyperparathyroidism.

IMAGING TECHNIQUE

4DCT refers to evaluation of the lesions acquired in three dimensions¹⁷ and their enhancement characteristics over time.¹⁸ Various protocols with different timed phases have been established in the literature,¹⁸ although it most commonly consists of an arterial phase at 25 to 30 seconds after contrast injection, together with venous phase at 45 to 60 seconds and/or a delayed phase at 80 to 90 seconds. A very delayed phase at approximately 120 seconds has also been adopted in some centres.¹⁹ The addition of a non-contrast phase is also controversial; a previous study has demonstrated that 22% of parathyroid lesions might have been missed if a pre-contrast scan had been excluded,²⁰ although another retrospective study²¹ showed that a two-phase protocol has only slightly reduced accuracy which has to be balanced with the radiation exposure of an additional phase. The use of dual energy acquisition to generate virtual non-contrast images for parathyroid adenomas have also been reported,^{22,23} although in our experience the virtual non-contrast images based on subtraction of iodine signal also diminished the hyperattenuation of the normal thyroid parenchyma, rendering more difficult visualisation of the parathyroid glands in the perithyroidal region.

Optimisation of the imaging protocol is of foremost importance in achieving accurate parathyroid localisation. The range of scanning has to cover all potential sites of ectopic parathyroid glands, from angle of the mandible to the upper mediastinum at the level of the aortic arch, although the pre-contrast scan can be limited to the thyroid bed (from hyoid bone to the inferior margin of clavicular head).¹⁷ Prior to scanning, a technique to move the shoulders down is also applied by asking the patient to pull tightly onto a traction bedsheet across his/her soles (Figure 1) so as to reduce the beam hardening artefacts over the lower pole of the thyroid, the level where inferior parathyroid adenomas are most commonly located (Figure 2).¹⁷ A rapid rate of contrast injection (at least 4 mL/s) is also important to better demonstrate the differences in enhancement characteristics. Contrast injection should be performed via a right arm vein to minimise streak artefacts over the midline upper mediastinum and lower neck. In our centre, we perform a non-contrast scan through the thyroid bed, followed by an arterial phase at 25 seconds

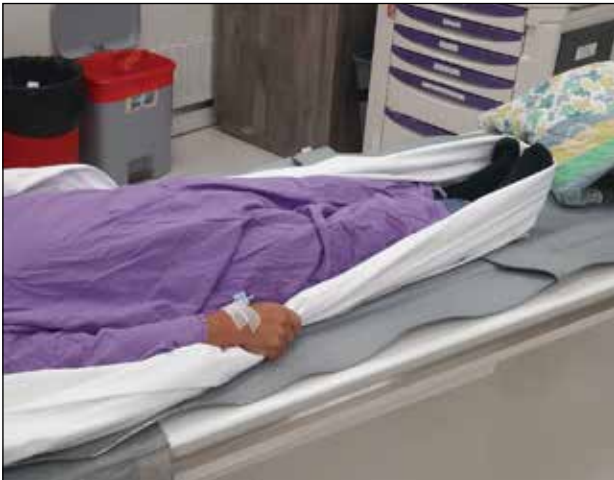

Figure 1. Technique to lower the shoulders prior to scanning using a traction bedsheet strapped around the patient's soles.

and a delayed phase at 80 seconds in a caudocranial direction from the aortic arch through the mandibular angle. Scanning parameters using SOMATOM Drive system (Siemens Healthineers, Munich, Germany) are as follows: 100kV, 300 mA (pre-contrast) and 400 mA (arterial and delayed), pitch 0.8, and 0.6-mm section thickness with multiplanar reconstruction.

IMAGE INTERPRETATION AND REPORTING

A structured template for reporting is useful to ensure that all important areas for management are included.

How Many Lesions Are There?

Most cases of primary hyperparathyroidism (85%-90%) are the result of a solitary hyperfunctioning adenoma, with multiglandular disease (6%), double adenoma (4%), and carcinoma (1%) being less common. Conversely, most if not all second hyperparathyroidism from renal failure is due to multiglandular hyperplasia.

Practical tip

The number of enlarged, hyperfunctioning parathyroid glands is an important factor for surgical planning. Patients with solitary lesions are eligible for MIP while patients with >1 lesion may require a unilateral or bilateral neck exploration.

Position of Parathyroid Glands

Approximately 80% of patients have four normal glands in two symmetrical pairs. The superior glands originate from the fourth pharyngeal pouch and descend caudally,

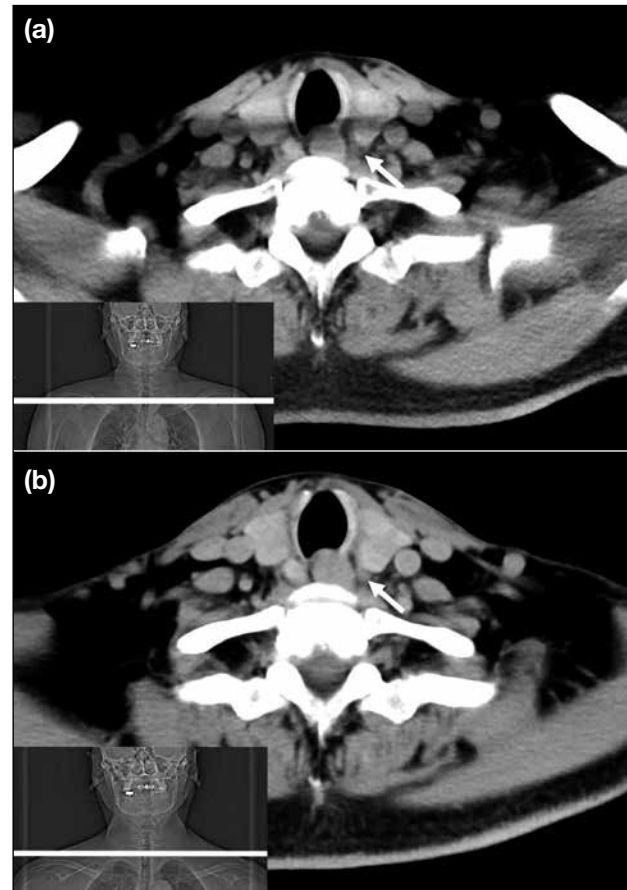


Figure 2. Pre-contrast images acquired without (a) and with (b) the use of the shoulder-lowering technique. With the technique, the shoulders are moved inferiorly to the level of the lower pole of the thyroid (scan plane is indicated by white line on the scanograms in the lower left-hand corner of [a] and [b]), with better demonstration of a small left-sided parathyroid adenoma (arrows) at this level.

orthotopically located posterior to the upper two-thirds of the thyroid lobe (most at the equator of the gland) and posterior to the recurrent laryngeal nerve. The inferior parathyroid glands originate from the third pharyngeal pouch, joining the thymus with a longer route of descent and are usually found more ventrally around the inferior thyroid poles and anterior to the recurrent laryngeal nerve.^{24,25} Supernumerary glands have been reported in approximately 15% of patients, while in 3% of cases only three glands can be found.²⁶

Ectopic parathyroid glands have a prevalence of 14% to 16% in patients with hyperparathyroidism and up to 43% in anatomical studies.²⁷ Superior ectopic glands are most commonly found in the retro-oesophageal region and trachea-oesophageal groove.^{28,29} These may result from over-descent in 10% to 20% of cases, mimicking, or

even more caudal to, an orthotopic inferior parathyroid.³⁰ Inferior ectopic parathyroid glands have a more variable location due to the longer descent, most commonly found in the thymic region and upper mediastinum with less common sites including undescended glands above the superior thyroid pole or within the carotid sheath.^{28,29} Intrathyroid parathyroid glands have also been reported in 1% to 3% of patients^{31,32} and are often difficult to detect by preoperative imaging or intra-operatively.

Practical tips

Firstly, a detailed description of location in relation to level and adjacent structures is required, such as hyoid, larynx, trachea, oesophagus, thyroid gland, carotid sheath, suprasternal notch, and mediastinal vessels. The relationship of an enlarged parathyroid gland to the trachea-oesophageal groove (expected location of recurrent laryngeal nerve) is also important, as superior parathyroid glands are posterior and inferior parathyroid glands are anterior to the groove (Figure 3). Secondly, check all areas from the angle of the mandible down to and including to the superior mediastinum. Lastly, the presence of an intervening fat plane is useful in distinguishing a parathyroid adenoma from a thyroid nodule, although this can be absent in small parathyroid adenomas within or abutting the thyroid capsule. It is therefore important to check all scanned phases, particularly the pre-contrast phase where parathyroid adenomas are relatively hypodense to the thyroid parenchyma.

How to Call a Lesion as an Abnormal Parathyroid Gland?

Size and shape

The normal parathyroid gland is up to 2 mm in thickness and 5 to 10 mm in length³³; hence, a gland is usually only visualised when enlarged and abnormal. Enlarged glands may be oval, round, pyramidal or lobulated and tend to be larger in parathyroid adenomas than multiple gland hyperplasia.

Enhancement pattern

The typical adenoma enhancement pattern would be hypodense to the thyroid on pre-contrast, hyperenhancing relative to the thyroid on arterial phase, and hypoenhancing on delayed phase. However, these imaging features are not consistently present in all parathyroid adenomas, as a recent study using dynamic CT¹⁸ has demonstrated that hyperfunctioning parathyroid tissue only shows a short period of hyperenhancement relative to the thyroid, with vast heterogeneity in the presence and timing of

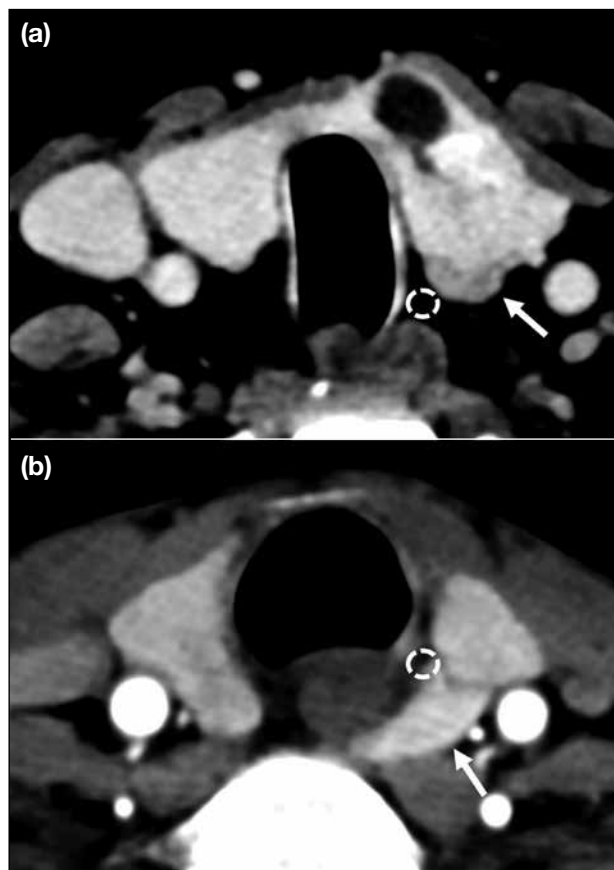


Figure 3. The trachea-oesophageal groove (dotted circles) is a useful landmark for the position of the recurrent laryngeal nerve. (a) Inferior parathyroid adenomas (arrow) lie anterior to the nerve and (b) superior parathyroid adenomas (arrow) lie posterior to it.

hyperenhancement amongst different adenomas. Three types of variations in enhancement have been previously described (Figures 4 to 6).²⁰

Ancillary features

The presence of a fat plane between the nodule and thyroid is used to discriminate a parathyroid adenoma from a thyroid nodule.

The presence of a polar vessel³⁴ entering the superior or inferior pole of the parathyroid is a useful ancillary feature to support the diagnosis of parathyroid adenoma (Figure 7a). Rim or central calcification (Figure 7b), internal cystic changes, or necrosis have been described as variant appearances of parathyroid adenomas, which can be present in up to 10% of cases.^{35,36} Acute necrosis in a parathyroid adenoma has been associated with spontaneous reduction in hormone levels.³⁷ Accurate differentiation of parathyroid carcinoma from adenoma is difficult,³⁸ although the presence of a large (>3 cm)

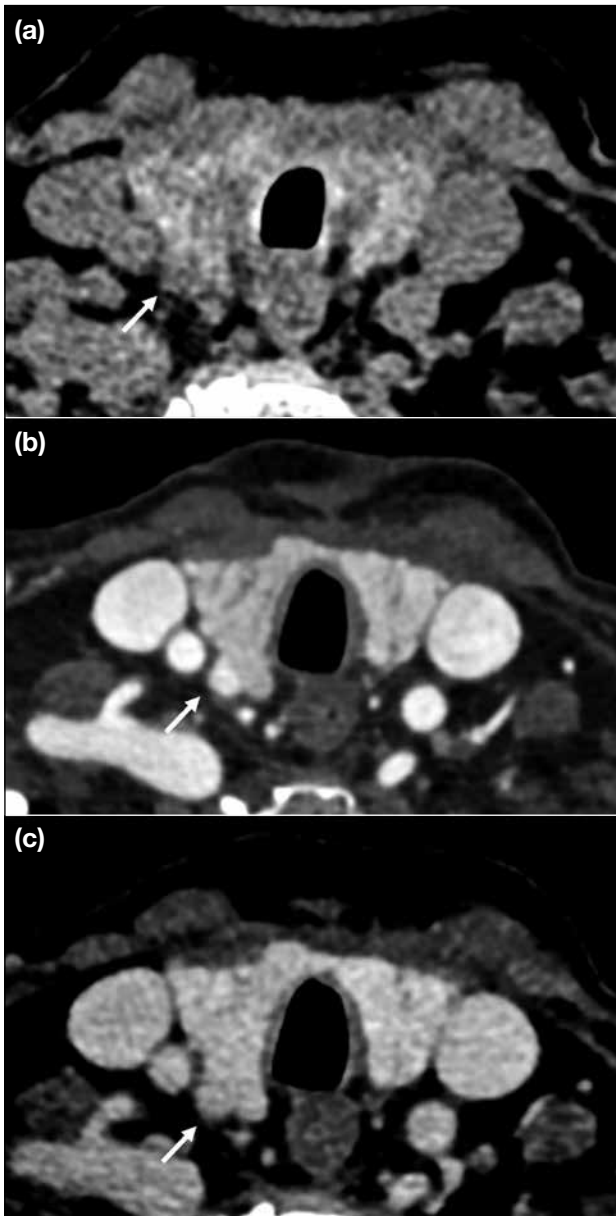


Figure 4. Parathyroid adenoma (arrows) with type A enhancement. It is hypodense to the adjacent thyroid parenchyma on pre-contrast imaging (a), hyperdense compared to the thyroid during the arterial phase (b), and isodense compared to the thyroid with contrast washout (c).

parathyroid gland, irregular borders and peritumoural infiltration into adjacent structures aids in distinguishing carcinoma from adenoma.^{39,40}

Practical tips

Firstly, small lymph nodes may be mistaken for parathyroid adenomas, although the presence of progressive enhancement on delayed phase and the presence of a fatty hilum are useful distinguishing

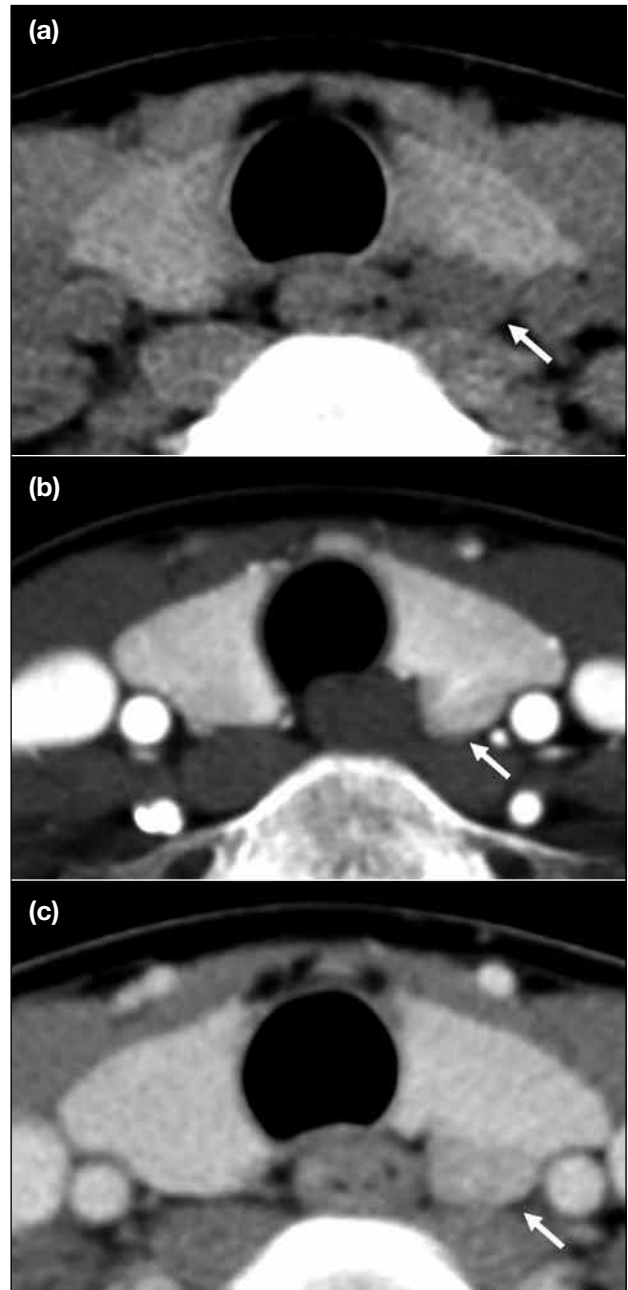


Figure 5. Parathyroid adenoma (arrows) with type B enhancement, defined by the absence of arterial hyperenhancement but presence of delayed phase hypoenhancement relative to the thyroid. It is hypodense to the adjacent thyroid parenchyma on the pre-contrast phase (a), showing hypodensity compared to the thyroid on the arterial phase (b) but with delayed phase hypoenhancement (c).

features. Secondly, for indeterminate lesions it is important to review previous ultrasound and scintigraphy, as lesions concordant with previous imaging findings afford much more diagnostic confidence. Repeating the ultrasound, especially in

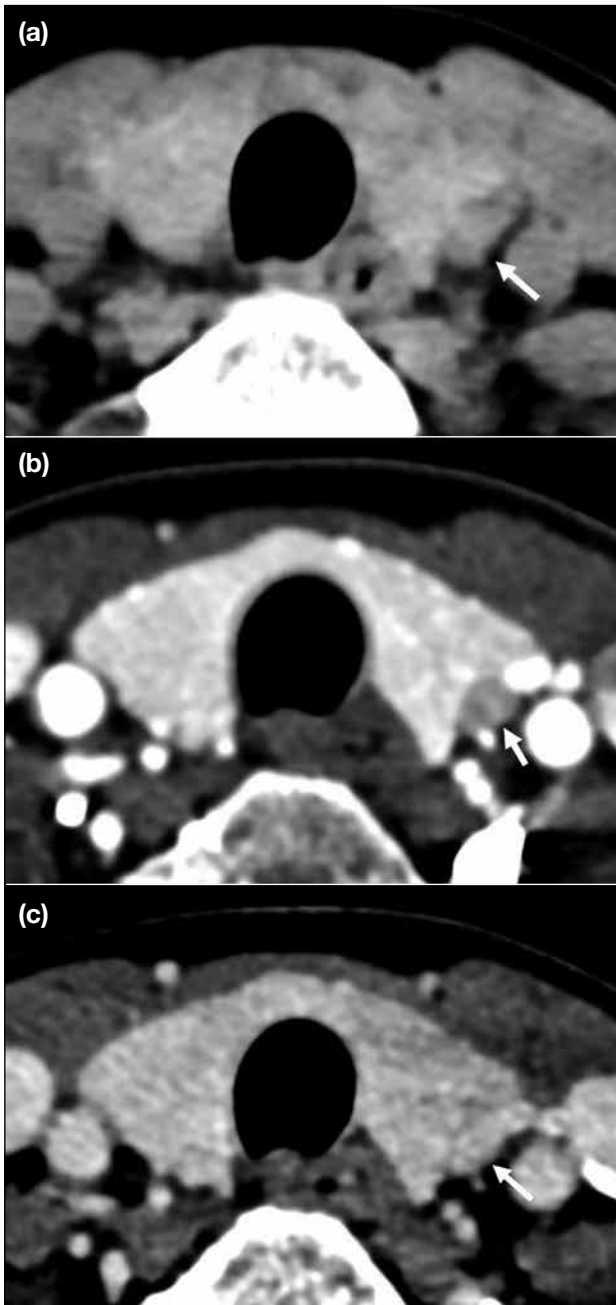


Figure 6. Parathyroid adenoma (arrows) with type C enhancement, defined by absence of arterial phase hyperenhancement and delayed phase hypoenhancement relative to the thyroid. It is hypodense on the pre-contrast phase (a) and shows hypoenhancement on the arterial phase (b) and iso-enhancement on the delayed phase (c). Contrast enhancement is still demonstrated in the venous and delayed phases, with slight washout on the delayed phase (Hounsfield unit on pre-contrast +33, arterial phase +148, and delayed phase +122).

cases where a previous study was negative or discordant from 4DCT, is an important problem-solving tool and increases diagnostic confidence without incurring additional radiation exposure (Figure 8).

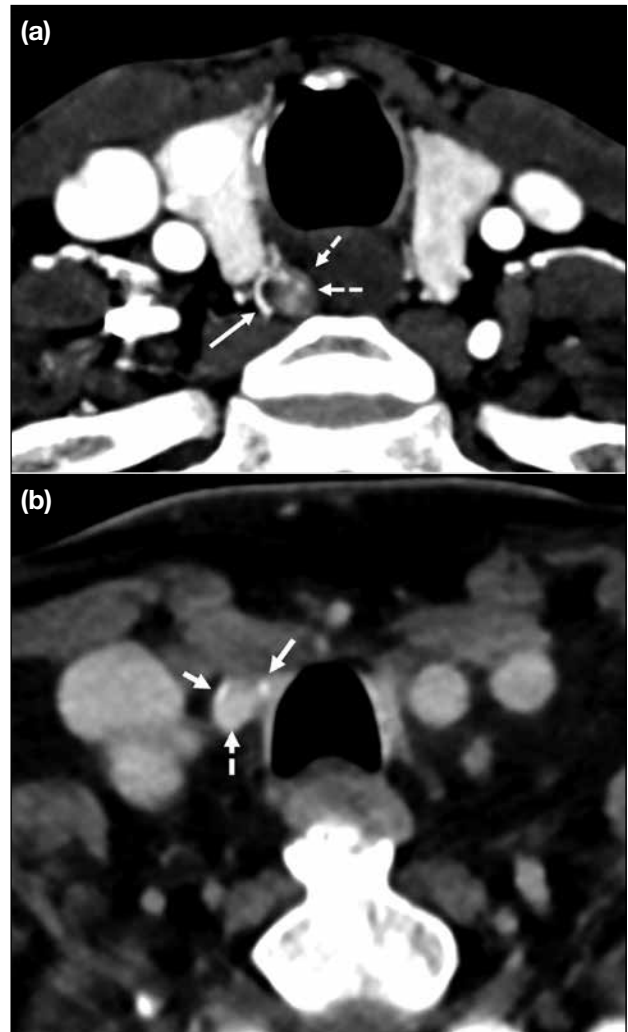


Figure 7. Ancillary features suggestive of parathyroid adenoma (dashed arrows) include presence of a polar vessel (solid arrow in [a]) and peripheral rim calcification (solid arrows in [b]).

Other Important Findings which may Affect Surgical Planning

The presence of concomitant thyroid nodules should be reported, which requires further evaluation with ultrasound and/or fine-needle aspiration cytology, as any suspicious thyroid nodule would necessitate a hemi- or total thyroidectomy in the same operation. This is also useful in investigating the possibility of a rare intrathyroid parathyroid adenoma, especially in patients where no other candidate lesion is identified. In addition, the presence of anomalies of the major arteries, such as an aberrant right subclavian artery, which can be associated with a non-recurrent laryngeal nerve,⁴¹ should be highlighted as this constitutes potential

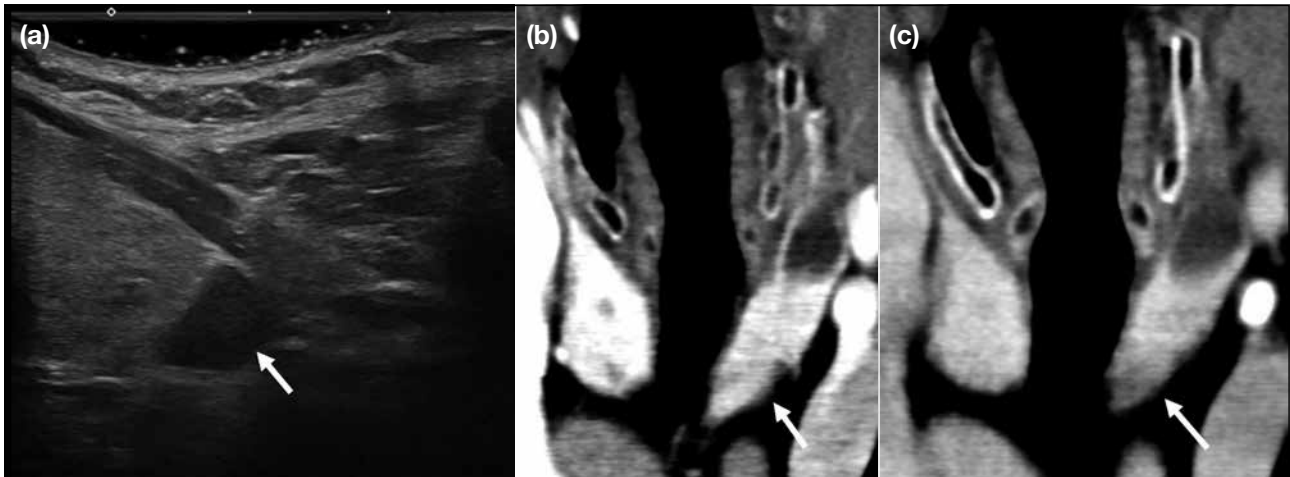


Figure 8. Ultrasound as a useful adjunct to four-dimensional computed tomography (4DCT) in problem solving. The parathyroid adenoma (arrows) is more conspicuous on this longitudinal ultrasound image showing the left lower pole of the thyroid (a), while it is only barely conspicuous on the arterial phase (b) and delayed phase (c) of 4DCT.

surgical hazard. Evidence of any previous head and neck surgery and altered anatomy should also be identified for accurate operative planning.

Performance of Four-Dimensional Computed Tomography and Comparison with Other Imaging Modalities

Ultrasound, nuclear scintigraphy, and 4DCT are widely accepted modalities for parathyroid localisation.⁴² While 4DCT has been adopted in some centres as first-line imaging,⁴³ the choice and sequence of imaging investigations remain variable across centres depending on availability and expertise.^{44,45} One of the main advantages of 4DCT is the ability to clearly demonstrate to the surgeon the location of a parathyroid adenoma and its relationship to adjacent structures. Multiple studies have proven 4DCT as a robust technique in parathyroid localisation,^{10,19,44,46} with the latest meta-analysis showing a sensitivity of 81% and positive predictive value of 91%.⁴⁷ The 4DCT has been shown to be superior to ^{99m}Tc sestamibi and ultrasound for localisation in several studies,^{10,11,48} although some other studies showed no significant difference in diagnostic accuracy.^{49,50} In our centre, a combination of parathyroid ultrasound and ^{99m}Tc sestamibi scintigraphy, which are more readily available, still serves as a first-line diagnostic approach while 4DCT is reserved for patients with negative or discordant localisation. Repeated parathyroid ultrasound in the same session as 4DCT can often enhance diagnostic confidence.

The 4DCT technique has also been proven useful in hyperparathyroid patients with previously negative ultrasound and/or scintigraphy.⁵¹ Limited studies have also explored its application in patients with secondary hyperparathyroidism,⁵² in whom bilateral neck exploration remains mandatory but which can identify ectopic or supernumerary glands to improve the rate of surgical success.⁴⁴

The issue of radiation exposure is also of concern. A previous study by Mahajan et al⁵³ has shown that the effective dose of 4DCT (10.4 mSv) is higher than ^{99m}Tc sestamibi scintigraphy (7.8 mSv). Although more recent studies have demonstrated a lower effective dose of 4DCT (4.5-8.9 mSv),⁴³ the organ dose to the thyroid bed from 4DCT remains significantly higher. The risk of attributed malignancy to radiation exposure from 4DCT should be balanced with the benefit of reducing surgical morbidity, by converting to a less complex MIP and lower chance of reoperation. This is especially helpful in younger patients where radiation exposure bears a more significant long-term cumulative effect. Despite a younger age of presentation of hyperparathyroidism in the Chinese population,⁵⁴ the majority of patients are still >50 years of age and the benefits of proceeding with 4DCT examination is mostly justified. In our institution, a combination of ultrasound and ^{99m}Tc sestamibi scintigraphy remains the initial investigation, with patients referred for 4DCT if the initial workup is inconclusive.

Finally, it is important to emphasise that all modalities have their advantages and disadvantages. Therefore, a multimodality approach and careful review of all previous parathyroid imaging studies are the keys to increase diagnostic confidence.

SUMMARY

4DCT of the parathyroids offers a promising alternative for preoperative localisation of parathyroid adenoma, not only as a problem-solving tool but with potential for becoming the modality of choice in the initial workup. A good understanding of underlying anatomy and imaging principles, optimisation of CT protocol, correlation with other imaging modalities, and structured reporting tailored to answer specific question by surgeons are all important in delivering accurate preoperative localisation for better surgical outcomes.

REFERENCES

- Adami S, Marcocci C, Gatti D. Epidemiology of primary hyperparathyroidism in Europe. *J Bone Miner Res.* 2002;17 Suppl 2:N18-23.
- Christensson T, Hellström K, Wengle B, Alveryd A, Wikland B. Prevalence of hypercalcaemia in a health screening in Stockholm. *Acta Med Scand.* 1976;200:131-7.
- Pradeep PV, Jayashree B, Mishra A, Mishra SK. Systematic review of primary hyperparathyroidism in India: the past, present, and the future trends. *Int J Endocrinol.* 2011;2011:921814.
- Liu JM, Cusano NE, Silva BC, Zhao L, He XY, Tao B, et al. Primary hyperparathyroidism: a tale of two cities revisited—New York and Shanghai. *Bone Res.* 2013;1:162-9.
- Insogna KL. Primary hyperparathyroidism. *N Engl J Med.* 2018;379:1050-9.
- Dawood NB, Yan KL, Shieh A, Livhits MJ, Yeh MW, Leung AM. Normocalcaemic primary hyperparathyroidism: an update on diagnostic and management challenges. *Clin Endocrinol (Oxf).* 2020;93:519-27.
- Walker MD, Silverberg SJ. Primary hyperparathyroidism. *Nat Rev Endocrinol.* 2018;14:115-25.
- Laird AM, Libutti SK. Minimally invasive parathyroidectomy versus bilateral neck exploration for primary hyperparathyroidism. *Surg Oncol Clin N Am.* 2016;25:103-18.
- Udelsman R, Lin Z, Donovan P. The superiority of minimally invasive parathyroidectomy based on 1650 consecutive patients with primary hyperparathyroidism. *Ann Surg.* 2011;253:585-91.
- Yeh R, Tay YD, Tabacco G, Derclé L, Kuo JH, Bandeira L, et al. Diagnostic performance of 4D CT and sestamibi SPECT/CT in localizing parathyroid adenomas in primary hyperparathyroidism. *Radiology.* 2019;291:469-76.
- Cheung K, Wang TS, Farrokhyar F, Roman SA, Sosa JA. A meta-analysis of preoperative localization techniques for patients with primary hyperparathyroidism. *Ann Surg Oncol.* 2012;19:577-83.
- National Institute for Health and Care Excellence. Hyperparathyroidism (primary): diagnosis, assessment and initial treatment. London: National Institute for Health and Care Excellence; 2019.
- Wilhelm SM, Wang TS, Ruan DT, Lee JA, Asa SL, Duh QY, et al. The American Association of Endocrine Surgeons Guidelines for Definitive Management of Primary Hyperparathyroidism. *JAMA Surg.* 2016;151:959-68.
- Bilezikian JP, Brandi ML, Eastell R, Silverberg SJ, Udelsman R, Marcocci C, et al. Guidelines for the management of asymptomatic primary hyperparathyroidism: summary statement from the Fourth International Workshop. *J Clin Endocrinol Metab.* 2014;99:3561-9.
- Stack BC Jr, Tolley NS, Bartel TB, Bilezikian JP, Bodenner D, Camacho P, et al. AHNS Series: Do you know your guidelines? Optimizing outcomes in reoperative parathyroid surgery: definitive multidisciplinary joint consensus guidelines of the American Head and Neck Society and the British Association of Endocrine and Thyroid Surgeons. *Head Neck.* 2018;40:1617-29.
- Walker MD, McMahon DJ, Inabnet WB, Lazar RM, Brown I, Vardy S, et al. Neuropsychological features in primary hyperparathyroidism: a prospective study. *J Clin Endocrinol Metab.* 2009;94:1951-8.
- Hoang JK, Sung WK, Bahl M, Phillips CD. How to perform parathyroid 4D CT: tips and traps for technique and interpretation. *Radiology.* 2014;270:15-24.
- Raeymaeckers S, De Brucker Y, Vanderhasselt T, Buls N, De Mey J. Detection of parathyroid adenomas with multiphase 4DCT: towards a true four-dimensional technique. *BMC Med Imaging.* 2021;21:64.
- Starker LF, Mahajan A, Björklund P, Sze G, Udelsman R, Carling T. 4D parathyroid CT as the initial localization study for patients with de novo primary hyperparathyroidism. *Ann Surg Oncol.* 2011;18:1723-8.
- Bahl M, Sepahdari AR, Sosa JA, Hoang JK. Parathyroid adenomas and hyperplasia on four-dimensional CT scans: three patterns of enhancement relative to the thyroid gland justify a three-phase protocol. *Radiology.* 2015;277:454-62.
- Griffith B, Chaudhary H, Mahmood G, Carlin AM, Peterson E, Singer M, et al. Accuracy of 2-phase parathyroid CT for the preoperative localization of parathyroid adenomas in primary hyperparathyroidism. *AJNR Am J Neuroradiol.* 2015;36:2373-9.
- Leiva-Salinas C, Flors L, Durst CR, Hou Q, Patrie JT, Wintermark M, et al. Detection of parathyroid adenomas using a monophasic dual-energy computed tomography acquisition: diagnostic performance and potential radiation dose reduction. *Neuroradiology.* 2016;58:1135-41.
- Roskies M, Liu X, Hier MP, Payne RJ, Mlynarek A, Forest V, et al. 3-phase dual-energy CT scan as a feasible salvage imaging modality for the identification of non-localizing parathyroid adenomas: a prospective study. *J Otolaryngol Head Neck Surg.* 2015;44:44.
- Mohebbati A, Shaha AR. Anatomy of thyroid and parathyroid glands and neurovascular relations. *Clin Anat.* 2012;25:19-31.
- Kunstman JW, Kirsch JD, Mahajan A, Udelsman R. Clinical review: parathyroid localization and implications for clinical management. *J Clin Endocrinol Metab.* 2013;98:902-12.
- Akerström G, Malmaeus J, Bergström R. Surgical anatomy of human parathyroid glands. *Surgery.* 1984;95:14-21.
- Noussios G, Agagnostis P, Natsis K. Ectopic parathyroid glands and their anatomical, clinical and surgical implications. *Exp Clin Endocrinol Diabetes.* 2012;120:604-10.
- Phitayakorn R, McHenry CR. Incidence and location of ectopic abnormal parathyroid glands. *Am J Surg.* 2006;191:418-23.
- Roy M, Mazeh H, Chen H, Sippel RS. Incidence and localization of ectopic parathyroid adenomas in previously unexplored patients. *World J Surg.* 2013;37:102-6.
- Duke WS, Vernon HM, Terris DJ. Reoperative parathyroidectomy: overly descended superior adenoma. *Otolaryngol Head Neck Surg.* 2016;154:268-71.

31. Goodman A, Politz D, Lopez J, Norman J. Intrathyroid parathyroid adenoma: incidence and location—the case against thyroid lobectomy. *Otolaryngol Head Neck Surg.* 2011;144:867-71.
32. McIntyre RC Jr, Eisenach JH, Pearlman NW, Ridgeway CE, Liechty RD. Intrathyroidal parathyroid glands can be a cause of failed cervical exploration for hyperparathyroidism. *Am J Surg.* 1997;174:750-3; discussion 753-4.
33. Grimelius L, Bondeson L. Histopathological diagnosis of parathyroid diseases. *Pathol Res Pract.* 1995;191s:353-65.
34. Bahl M, Muzaffar M, Vij G, Sosa JA, Choudhury KR, Hoang JK. Prevalence of the polar vessel sign in parathyroid adenomas on the arterial phase of 4D CT. *AJNR Am J Neuroradiol.* 2014;35:578-81.
35. Chandramohan A, Sathyakumar K, John RA, Manipadam MT, Abraham D, Paul TV, et al. Atypical ultrasound features of parathyroid tumours may bear a relationship to their clinical and biochemical presentation. *Insights Imaging.* 2014;5:103-11.
36. Ahuja AT, Wong KT, Ching AS, Fung MK, Lau JY, Yuen EH, et al. Imaging for primary hyperparathyroidism—what beginners should know. *Clin Radiol.* 2004;59:967-76.
37. Chan WB, Chow CC, King AD, Yeung VT, Li JK, So WY, et al. Spontaneous necrosis of parathyroid adenoma: biochemical and imaging follow-up for two years. *Postgrad Med J.* 2000;76:96-8.
38. Al-Kurd A, Mekel M, Mazeh H. Parathyroid carcinoma. *Surg Oncol.* 2014;23:107-14.
39. Ferraro V, Sgaramella LI, Di Meo G, Prete FP, Logoluso F, Minerva F, et al. Current concepts in parathyroid carcinoma: a single centre experience. *BMC Endocr Disord.* 2019;19(Suppl 1):46.
40. Takumi K, Fukukura Y, Hakamada H, Nagano H, Kumagae Y, Arima H, et al. CT features of parathyroid carcinomas: comparison with benign parathyroid lesions. *Jpn J Radiol.* 2019;37:380-9.
41. Henry BM, Sanna S, Graves MJ, Vikse J, Sanna B, Tomaszewska IM, et al. The non-recurrent laryngeal nerve: a meta-analysis and clinical considerations. *PeerJ.* 2017;5:e3012.
42. Bunch PM, Randolph GW, Brooks JA, George V, Cannon J, Kelly HR. Parathyroid 4D CT: what the surgeon wants to know. *Radiographics.* 2020;40:1383-94.
43. Leong D, Ng K, Boeddinghaus R, Lisewski D. Three-phase four-dimensional computed tomography as a first-line investigation in primary hyperparathyroidism. *ANZ J Surg.* 2021;91:1798-803.
44. Expert Panel on Neurological Imaging; Zander D, Bunch PM, Policeni B, Juliano AF, Carneiro-Pla D, et al. ACR Appropriateness Criteria® Parathyroid Adenoma. *J Am Coll Radiol.* 2021;18(11S):S406-22.
45. Bunch PM, Kelly HR. Preoperative imaging techniques in primary hyperparathyroidism: a review. *JAMA Otolaryngol Head Neck Surg.* 2018;144:929-37.
46. Brown SJ, Lee JC, Christie J, Maher R, Sidhu SB, Sywak MS, et al. Four-dimensional computed tomography for parathyroid localization: a new imaging modality. *ANZ J Surg.* 2015;85:483-7.
47. Sun L, Yao J, Hao P, Yang Y, Liu Z, Peng R. Diagnostic role of four-dimensional computed tomography for preoperative parathyroid localization in patients with primary hyperparathyroidism: a systematic review and meta-analysis. *Diagnostics (Basel).* 2021;11:664.
48. Suh YJ, Choi JY, Kim SJ, Chun IK, Yun TJ, Lee KE, et al. Comparison of 4D CT, ultrasonography, and ^{99m}Tc sestamibi SPECT/CT in localizing single-gland primary hyperparathyroidism. *Otolaryngol Head Neck Surg.* 2015;152:438-43.
49. Wan QC, Li JF, Tang LL, Lv J, Xie LJ, Li JP, et al. Comparing the diagnostic accuracy of 4D CT and ^{99m}Tc-MIBI SPECT/CT for localizing hyperfunctioning parathyroid glands: a systematic review and meta-analysis. *Nucl Med Commun.* 2021;42:225-33.
50. Krakauer M, Wieslander B, Myschetzky PS, Lundström A, Bacher T, Sørensen CH, et al. A prospective comparative study of parathyroid dual-phase scintigraphy, dual-isotope subtraction scintigraphy, 4D-CT, and ultrasonography in primary hyperparathyroidism. *Clin Nucl Med.* 2016;41:93-100.
51. Beland MD, Mayo-Smith WW, Grand DJ, Machan JT, Monchik JM. Dynamic MDCT for localization of occult parathyroid adenomas in 26 patients with primary hyperparathyroidism. *AJR Am J Roentgenol.* 2011;196:61-5.
52. Hiramitsu T, Tomosugi T, Okada M, Futamura K, Tsujita M, Goto N, et al. Pre-operative localisation of the parathyroid glands in secondary hyperparathyroidism: a retrospective cohort study. *Sci Rep.* 2019;9:14634.
53. Mahajan A, Starker LF, Ghita M, Udelsman R, Brink JA, Carling T. Parathyroid four-dimensional computed tomography: evaluation of radiation dose exposure during preoperative localization of parathyroid tumors in primary hyperparathyroidism. *World J Surg.* 2012;36:1335-9.
54. Zhao L, Liu JM, He XY, Zhao HY, Sun LH, Tao B, et al. The changing clinical patterns of primary hyperparathyroidism in Chinese patients: data from 2000 to 2010 in a single clinical center. *J Clin Endocrinol Metab.* 2013;98:721-8.