
ORIGINAL ARTICLE

Cancer Risk of Focal Thyroid Incidentaloma in Patients Undergoing 18F-fluorodeoxyglucose Positron Emission Tomography–Computed Tomography Studies: Local Experience in a Single Centre

BT Kung, CP Wong, KS Chu, TK AuYong, CM Tong

Pong Ding Yuen Clinical PET-CT Centre and Nuclear Medicine Unit, Queen Elizabeth Hospital, Hong Kong

ABSTRACT

Objectives: To determine the prevalence of focal thyroid fluorodeoxyglucose positron emission tomography–computed tomography incidentaloma in our locality and evaluate the rate of malignancy.

Methods: A retrospective review of 1407 individual patients who underwent fluorodeoxyglucose positron emission tomography–computed tomography imaging in a clinical positron emission tomography centre, Queen Elizabeth Hospital, from December 2006 to August 2007 was performed. Thyroid incidentaloma was generally regarded as any newly identified thyroid lesion encountered during imaging studies in patients without a history of thyroid disease. We defined it as an incidental finding of abnormally increased fluorodeoxyglucose uptake in the thyroid gland of a patient without a history of thyroid disease. Among identified patients, those who underwent further investigations were analysed using the electronic patient record system in our institution. Corresponding findings from surgical biopsy, fine needle aspiration, and histopathological findings were reviewed.

Results: Of 1407 subjects, 45 (3.2%) showed focal incidentaloma, 30 of whom were not followed up further, and in 15 (33%) a histopathological diagnosis was obtained. Among the latter, 6 (40%) of the thyroid lesions turned out to be malignant.

Conclusions: The point prevalence of focal thyroid incidentaloma identified by fluorodeoxyglucose positron emission tomography–computed tomography in this study was 3.2%. In all, 33% of focal thyroid incidentaloma patients underwent further histopathological investigation in our institution. In this study, there was no statistically significant difference in maximum standardised uptake value between malignant and benign nodules. Of those patients with focal thyroid incidentalomas that had been clinically selected for further investigation or surgery, 40% had malignant lesions. Further investigation of this patient group may be warranted lest it affects prognosis and management.

Key Words: Fluorodeoxyglucose F18; Positron-emission tomography; Thyroid gland; Thyroid neoplasms; Tomography, emission-computed

中文摘要

18氟-脱氧葡萄糖正子攝影電腦斷層掃描 (PET-CT) 顯像檢出甲狀腺偶發瘤中惡性病灶的比例：香港一所中心的經驗

龔本堯、黃治平、朱競新、歐陽定勤、唐卓敏

目的：探討使用氟脫氧葡萄糖 (FDG) 正子攝影電腦斷層掃描 (PET-CT) 顯像對局部甲狀腺偶發瘤的檢出率，及評估其中惡性病灶的比例。

Correspondence: Dr BT Kung, Pong Ding Yuen Clinical PET-CT Centre and Nuclear Medicine Unit, Queen Elizabeth Hospital, 30 Gascoigne Road, Kowloon, Hong Kong.

Tel: (852) 2958 6543; Fax: (852) 2780 4451; Email: btkung425@gmail.com

Submitted: 11 Jan 2010; Accepted: 2 Sep 2010.

方法：回顧研究2006年12月至2007年8月期間伊利沙伯醫院臨床PET中心接受FDG PET-CT檢測的1407位病人。甲狀腺偶發瘤的一般定義為本身並無甲狀腺病史的病人在影像學檢查中發現新的甲狀腺病灶。本研究的定義為本身並無甲狀腺病史的病人在PET-CT檢查中發現其甲狀腺區FDG攝取異常增加。透過本院的電子病歷系統，再分析這些病人的進一步檢查結果，回顧其手術切片、細針穿刺細胞學檢查、及組織病理學有關結果。

結果：在1407名病人中，45名（3.2%）有甲狀腺偶發瘤，其中30名未有隨訪。餘下15名（33%）接受組織病理學檢查的病人中，有6名（40%）的甲狀腺病灶為惡性。

結論：本研究發現局部甲狀腺偶發瘤的FDG PET-CT檢出率為3.2%。甲狀腺偶發瘤患者中有33%進一步接受組織病理學檢查。比較惡性與良性的病灶顯示兩者的最大標準化FDG攝取值並無統計學顯著性。進一步接受檢查或手術的病人中，有40%為甲狀腺惡性病變。為免影響預後及治療，應為有甲狀腺偶發瘤的病人作進一步檢查。

INTRODUCTION

Whole-body 18F-fluorodeoxyglucose (FDG) positron emission tomography (PET) plays a vital role in patients with various kinds of malignancies. It is crucial in detecting metastasis and also affects disease staging, which influences clinical management of patients. Thyroid incidentalomas have been increasingly reported with the advancing use of FDG positron emission tomography-computed tomography (PET-CT) in clinical practice. Thyroid incidentalomas are generally regarded as newly identified thyroid lesions encountered during imaging studies in patients without a history of thyroid disease. In our study, besides the above criteria, we defined focal thyroid incidentalomas as an incidental finding of abnormally increased focal FDG uptake in the thyroid gland in a patient without a history of thyroid disease (Figure). The prevalence of focal thyroid incidentalomas was found in 1.2 to 2.3% of patients who undergo PET examination.¹⁻³ Whether focal thyroid incidentalomas found by FDG PET indicate a high prevalence of thyroid malignancy is still controversial.⁴⁻¹⁰ To date, the prevalence of thyroid incidentalomas found on clinical FDG PET-CT in Hong Kong has not been reported. The purpose of this study was to determine the point prevalence of malignancy in patients with focal FDG avid thyroid incidentalomas in our locality.

METHODS

Subjects

This retrospective study included 1407 individual patients who underwent FDG PET-CT imaging in the PET centre at Queen Elizabeth Hospital, Hong Kong from 1 December 2006 to 31 August 2007. The sample

comprised patients with or without a documented history of malignancy. Patients with abnormally increased FDG thyroid lesions were interpreted and identified by reporting nuclear medicine physicians. Patients with thyroid incidentaloma who underwent further investigations were analysed using the electronic patient record system in our institution. Surgical biopsy, fine needle aspiration diagnoses, and histopathological findings were reviewed. Patients were followed up from the date of PET-CT examination till 31 October 2008

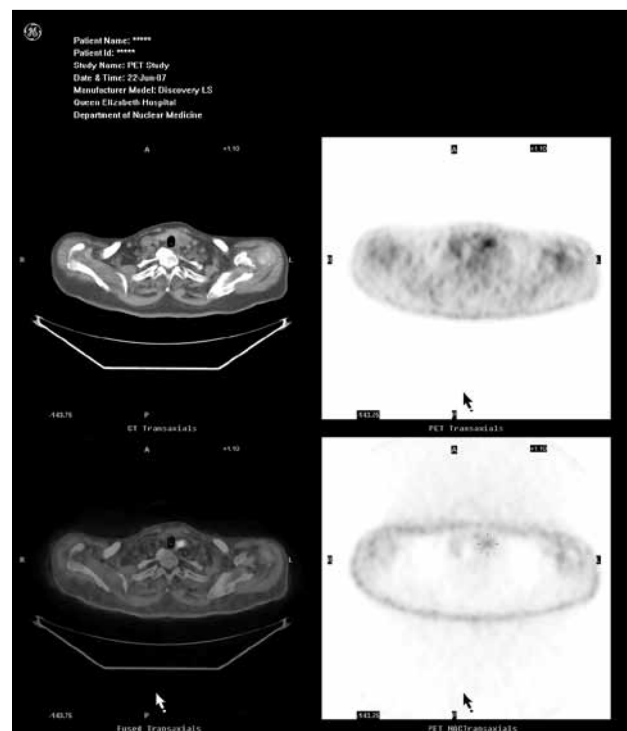


Figure. Image of focal thyroid fluorodeoxyglucose (FDG) positron emission tomography incidentaloma (defined as abnormal focal increase of FDG thyroidal uptake in a patient with no prior history of thyroid disease).

via our electronic patient record system.

Positron Emission Tomography Method

All patients were fasted at least 6 hours before intravenous FDG injection. Scanning was initiated. Sixty minutes after administration, images were taken from the head to the proximal thigh with a PET-CT scanner (Discovery LS, GE Healthcare, US) with a spatial resolution of 6.6 mm in the centre of the field of view; 370 MBq of FDG was injected intravenously. Seven bed positions were used with 3 minutes per bed position. CT-attenuated correction was performed. The images obtained were reconstructed using an ordered subsets expectation maximisation iterative reconstruction algorithm. Regions of interests were drawn for FDG uptake quantification on visible lesions with increased uptake, and the maximum standardised uptake value (SUVmax) was semiquantitatively analysed using the following equation:

$$\text{SUV} = A / (\text{ID} / \text{BW})$$

where *A* represents the decay-and attenuation-corrected activity in tissue (in MBq per ml), *ID* represents the injected dose of FDG (in MBq), and *BW* represents the patient's body weight (in g)

Statistical Analysis

The SUVmax in patients with benign and malignant focal thyroid incidentalomas revealed by FDG PET-CT was compared. The rate of malignancy in focal thyroid incidentalomas with FDG PET uptake, and its association with SUVmax were assessed. Statistical analysis was performed using the SPSS software package (Windows Version 15.0, SPSS, Inc., Chicago [IL], US). Non-parametric Mann-Whitney test was used to compare the SUVmax in patients with benign and malignant lesions of the focal thyroid incidentaloma. Statistical significance was assumed when the *p* value was less than 0.05.

RESULTS

Of the 1407 patients having FDG-PET, 58 (4.1%) patients demonstrated thyroid FDG uptake; 45 (3.2%) patients demonstrated focal thyroid incidentaloma and 13 (0.9%) patients demonstrated diffuse thyroid uptake. Of the 45 patients with focal thyroid incidentaloma, 15 (33%) had a histopathological diagnosis, the remaining 30 (67%) patients had no further investigations. Regarding the 15 focal thyroid incidentaloma patients

who had a histopathological diagnosis, the mean follow-up period was 19 months; 6 (40%) patients turned out to have malignant lesions. Among these 6 patients, 5 (83%) had a primary thyroid carcinoma—3 had a papillary thyroid carcinoma, 1 an anaplastic thyroid carcinoma, and the other a medullary thyroid carcinoma. Of the 6 patients, 1 (17%) had a metastasis from a renal cell carcinoma. Among the remaining 9 patients, 3 (33%) had a follicular lesion with Hurthle cell change, 5 (56%) had a benign thyroid nodule, and 1 (11%) had atypical cells and suboptimal for evaluation. Patient details are shown in the Table.

The mean and median SUVmax of the malignant nodules were 11.7 and 10.2, respectively, and ranged from 2.1 to 28.5; corresponding values for the benign thyroid nodules were 4.8 and 5.1, respectively (range, 2.3-7). When analysed by the Mann-Whitney test, there was no statistically significant difference between the 2 groups (*p* = 0.157).

DISCUSSION

FDG PET is increasingly used in the diagnostic workup and follow-up of patients. The point prevalence of focal thyroid incidentalomas reported in several studies on patients or healthy subjects ranges from 2.2 to 2.9%.^{2,3,5,10} For patients in our institution, the value was 3.2%, which was similar to findings reported by others.

Although there are reports suggesting that FDG accumulation may vary in the normal thyroid gland and that diffuse or focal FDG thyroid uptake could be normal,^{11,12} recent studies have shown that focal thyroid incidentalomas with uptake of FDG PET have a high prevalence of thyroid malignancy.^{2,3,5,10} In contrast to focal thyroid FDG uptake, the associated risk of malignancy in diffuse thyroid FDG uptake is much lower. Diffuse thyroid FDG uptake is usually benign and is usually caused by chronic lymphocytic (Hashimoto's) thyroiditis. Yasuda et al¹³ reported 36 cases with diffuse thyroid FDG uptake, which were identified from a sample of 1102 patients. All the cases were found to be caused by thyroiditis. In a few cases, diffuse thyroid FDG uptake was related to Graves' disease.¹⁴ Rarely, diffuse thyroid FDG uptake can be caused by malignancies.¹⁰

We also observed a high rate of malignancy (40%).

When focal thyroid FDG uptake was detected in patients with an underlying malignancy, primary thyroid cancer, not just metastatic lesions, should be considered. In our study, 1 out of 6 patients with malignant thyroid lesions was confirmed to be a metastatic renal cell carcinoma.

In order to distinguish between benign and malignant focal thyroid lesions by FDG PET, many overseas researchers had emphasised the significance of SUVmax.^{3,6} Some studies suggested that SUVmax of malignant thyroid lesions was significantly higher than that of benign lesions.^{3,6,15} Other investigators, however, found no significant difference between benign and malignant focal thyroid lesions in terms of SUVmax,^{5,10} and hence advised that the latter parameter should not be used as a predictor of malignant lesions.⁸⁻¹⁰ In the current study too, there was no statistically significant difference in SUVmax between benign and malignant nodules, although the mean SUVmax in patients with malignant lesions was higher.

In some centres, it has been a routine to biopsy thyroid incidentalomas detected on PET. In the current study, the percentage of focal thyroid incidentaloma patients who underwent further histopathological diagnosis was 33%. Other studies have reported rates of pursuing further diagnostic confirmation tests for focal thyroid incidentaloma ranging from 14.7 to 71.4%.^{2,3,5,10}

Concerning the pitfalls of this study, 3 histopathological reports of non-malignant individuals revealed follicular lesions with Hurthle cell change. As thyroid cancer takes a long time to develop, we cannot definitely exclude the possibility of future carcinogenesis in these 3 patients.

As illustrated in the Table, the indication for PET-CT was cancer screening in 5 of our patients without a prior history of cancer. Four of them were referred for musculoskeletal symptoms, with prior imaging that showed suspicious lesions. Among these 4 patients, 3

Table. Characteristics, SUVmax, indications, and histology of focal thyroid incidentaloma patients.

Patient No.	Sex	Age at examination (years)	Location	SUVmax	Indication for PET-CT	Histology	FU period (till 31 Oct 2008) [months]	Diagnostic method
1	M	65	R	2.1	Renal cell Ca	Metastatic renal cell Ca	21	Surgery
2	M	71	L	3.5	Ca screening*	Medullary Ca	19	Fine needle aspiration cytology
3	F	61	L	8.5	TCC kidney	Papillary Ca	18	Fine needle aspiration cytology
4	F	58	L	11.8	Lung Ca	Papillary Ca	21	Surgery
5	M	81	L	15.7	Ca screening	Anaplastic Ca	19	Surgery
6	M	60	L	28.5	Ca screening	Papillary Ca	17	Fine needle aspiration cytology
7	F	46	R	2.3	Colon Ca	Benign follicular lesion	18	Fine needle aspiration cytology
8	F	75	R	2.9	Ca screening	Benign follicular lesion	18	Fine needle aspiration cytology
9	F	39	R	3	Breast Ca	Atypical cell, no evidence of malignancy	19	Fine needle aspiration cytology
10	F	59	L	4.1	Cervix Ca	Benign nodular hyperplasia	19	Fine needle aspiration cytology
11	F	59	L	5.1	Breast Ca	Benign follicular lesion	23	Fine needle aspiration cytology
12	F	78	L	5.8	GIST	Follicular lesion with Hurthle cell change	22	Fine needle aspiration cytology
13	F	58	R	6.3	Ovary Ca	Benign follicular lesion	20	Fine needle aspiration cytology
14	F	63	R	6.9	Ca screening	Follicular lesion with Hurthle cell change	14	Fine needle aspiration cytology
15	F	65	L	7	Sigmoid Ca	Follicular lesion with Hurthle cell change	16	Surgery

Abbreviations: Ca = Cancer; FU = follow-up; GIST = gastrointestinal stromal tumour; PET-CT = positron emission tomography-computed tomography; SUVmax = maximum standardised uptake value; TCC = transitional cell carcinoma.

* Ca screening = cancer screening in individuals without a prior history of cancer.

had low back pain, and another had left thigh pain and an X-ray of the femur showing a suspicious lesion. The 5th patient presented with a raised carcinoembryonic antigen level. We do not advocate using PET-CT for routine screening in asymptomatic individuals, as this is not an evidence-based practice.

In conclusion, the point prevalence of focal thyroid incidentalomas identified by FDG PET-CT in this study was 3.2%. The rate in our locality was similar to that reported in overseas studies. In all, 40% of patients with focal thyroid incidentalomas that had been clinically selected for further investigation turned out to have malignant lesions. There was no statistically significant difference in SUVmax between malignant and benign nodules. In our institution, only 33% of the patients with focal thyroid incidentaloma underwent further histopathological investigation. Further investigation in this patient group may be warranted if such a practice can be shown to beneficially influence prognosis and future management.

REFERENCES

- Chen YK, Ding HJ, Chen KT, et al. Prevalence and risk of cancer of focal thyroid incidentaloma identified by 18F-fluorodeoxyglucose positron emission tomography for cancer screening in healthy subjects. *Anticancer Res.* 2005; 25:1421-6.
- Cohen MS, Arslan N, Dehdashti F, et al. Risk of malignancy in thyroid incidentalomas identified by fluorodeoxyglucose-positron emission tomography. *Surgery.* 2001;130:941-6.
- Kang KW, Kim SK, Kang HS, et al. Prevalence and risk of cancer of focal thyroid incidentaloma identified by 18F-fluorodeoxyglucose positron emission tomography for metastasis evaluation and cancer screening in healthy subjects. *J Clin Endocrinol Metab.* 2003;88:4100-4.
- Yi JG, Marom EM, Munden RF, et al. Focal uptake of fluorodeoxyglucose by the thyroid in patients undergoing initial disease staging with combined PET/CT for non-small cell lung cancer. *Radiology.* 2005;236:271-5.
- Kim TY, Kim WB, Ryu JS, Gong G, Hong SJ, Shong YK. 18F-fluorodeoxyglucose uptake in thyroid from positron emission tomogram (PET) for evaluation in cancer patients: high prevalence of malignancy in thyroid PET incidentaloma. *Laryngoscope.* 2005;115:1074-8.
- Choi JY, Lee KS, Kim HJ, et al. Focal thyroid lesions incidentally identified by integrated 18F-FDG PET/CT: clinical significance and improved characterization. *J Nucl Med.* 2006;47:609-15.
- Ramos CD, Chisin R, Yeung HW, Larson SM, Macapinlac HA. Incidental focal thyroid uptake on FDG positron emission tomographic scans may represent a second primary tumor. *Clin Nucl Med.* 2001;26:193-7.
- Davis PW, Perrier ND, Adler L, Levine EA. Incidental thyroid carcinoma identified by positron emission tomography scanning obtained for metastatic evaluation. *Am Surg.* 2001;67:582-4.
- Van den Bruel A, Maes A, De Potter T, et al. Clinical relevance of thyroid fluorodeoxyglucose-whole body positron emission tomography incidentaloma. *J Clin Endocrinol Metab.* 2002;87:1517-20.
- Are C, Hsu JF, Schoder H, Shah JP, Larson SM, Shaha AR. FDG-PET detected thyroid incidentalomas: need for further investigation? *Ann Surg Oncol.* 2007;14:239-47.
- Gordon BA, Flanagan FL, Dehdashti F. Whole-body positron emission tomography: normal variations, pitfalls, and technical considerations. *AJR Am J Roentgenol.* 1997;169:1675-80.
- Shreve PD, Anzai Y, Wahl RL. Pitfalls in oncologic diagnosis with FDG PET imaging: physiologic and benign variants. *Radiographics.* 1999;19:61-77.
- Yasuda S, Shohtsu A, Ide M, et al. Chronic thyroiditis: diffuse uptake of FDG at PET. *Radiology.* 1998;207:775-8.
- Chen YK, Wang YF, Chiu JS. Diagnostic trinity: Graves' disease on F-18 FDG PET. *Clin Nucl Med.* 2007;32:816-7.
- Mitchell JC, Grant F, Evenson AR, Parker JA, Hasselgren PO, Parangi S. Preoperative evaluation of thyroid nodules with 18FDG-PET/CT. *Surgery.* 2005;138:1166-75.