
CASE REPORT

Neonatal Exchange Transfusion Complicated by Haemoperitoneum and Liver Haematoma Related to Umbilical Venous Catheterization

JTH Yeung¹, DCY Lui¹, SY Lee², JKF Ma¹, JCY Fong¹

¹Department of Radiology and ²Department of Paediatrics, Princess Margaret Hospital, Kowloon, Hong Kong.

ABSTRACT

Umbilical venous catheterization is a commonly performed bedside procedure in the neonatal unit. Potential complications include vascular perforation, thrombosis, embolism, haemorrhage, infection, and tissue injuries. We report a case of liver haematoma and haemoperitonem after exchange transfusion, which are uncommon complications of umbilical venous catheterization. Radiological features and clinical presentations are discussed.

Key Words: Catheters, indwelling; Exchange transfusion, whole blood; Hematoma; Liver; Umbilical veins

中文摘要

新生兒換血後與臍靜脈導管有關的腹腔積血及肝臟血腫

楊芷珩、雷彩如、李誠仁、馬嘉輝、方俊仁

臍靜脈導管經常被使用在新生兒臨床程序中，可能的併發症包括血管穿孔、血栓形成、栓塞、出血、感染及組織受損。本文報告一個與臍靜脈導管有關的罕見併發病例，病人換血後出現腹腔積血及肝臟血腫。本文並討論有關此併發的放射學特徵及臨床表現。

CASE REPORT

A male baby was born at gestation of 39 weeks with a birth weight of 3.5 kg. There was slight meconium-stained liquor. He developed cyanosis and grunting shortly after birth. Chest radiography showed diffuse streaky opacities. He was intubated, initially received conventional ventilation, and then high-frequency oscillatory ventilation to achieve satisfactory oxygenation. The pre-ductal oxygen saturation was consistently higher than the post-ductal one. Persistent pulmonary hypertension of the newborn was diagnosed,

which was confirmed by echocardiography showing a pulmonary blood pressure of up to 50 mm Hg. An umbilical venous catheter (UVC) was inserted for delivery of dopamine, dobutamine and parenteral nutrition on day 1. The UVC position was shown to be appropriate on abdominal radiograph (AXR) [Figure 1]. His respiratory condition improved and he was extubated on day 4. On day 5, parenteral nutrition was stopped as full feeding was achieved. In view of high serum bilirubin levels and anticipation of exchange transfusion, the UVC was kept patent by infusion

Correspondence: Dr Jessie TH Yeung, Department of Radiology, Princess Margaret Hospital, Laichikok, Kowloon, Hong Kong.
Tel: (852) 2990 1349 ; Email: jezzyeung@gmail.com

Submitted: 26 Apr 2011; Accepted: 21 Jul 2011.

of heparinised saline (lest it could be used later for exchange transfusion). Despite intensive phototherapy, on day 6 the serum bilirubin level remained high and exchange transfusion was organised. The plan was to withdraw 560 ml of the patient's blood in exchange for the same volume of donor's blood. The patient's blood was slowly withdrawn via an arterial line in the left radial artery. At the same time, donor's blood was slowly infused via the UVC. After 'exchange' of 100 ml of blood over 20 minutes, marked abdominal distension was noted. Displacement of the UVC was seen on AXR (Figure 2). The patient began to have

respiratory distress and was intubated. The heart rate was 180 beats per minute, and the mean blood pressure was 60 mm Hg, but fell to 37 mm Hg after 5 hours. The haemoglobin level dropped from 115 to 71 g/L. The UVC was removed. With a view to demonstrating any active bleeding, computed tomography (CT) of the abdomen was performed instead of ultrasound.

CT abdomen (Figures 3-6) showed hyperdense fluid within the peritoneal cavity. A space-occupying lesion measuring 6.5 cm x 5.5 cm x 5.5 cm (estimated volume of around 100 ml) with fluid-fluid levels and

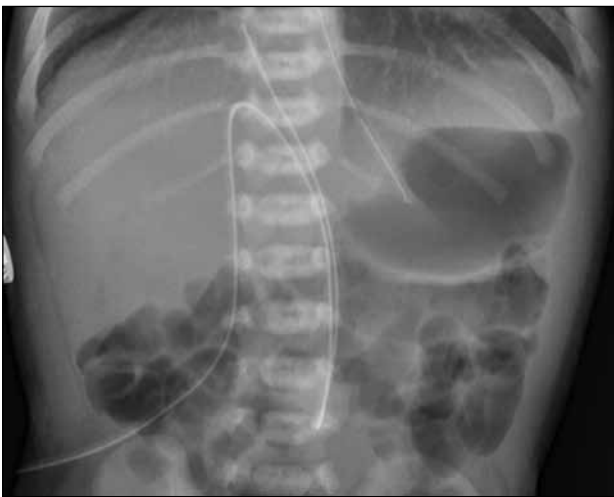


Figure 1. An abdominal radiograph on the day of umbilical venous catheter (UVC) insertion showing UVC position in the expected position of inferior vena cava and right atrial junction. A feeding tube has also been introduced.

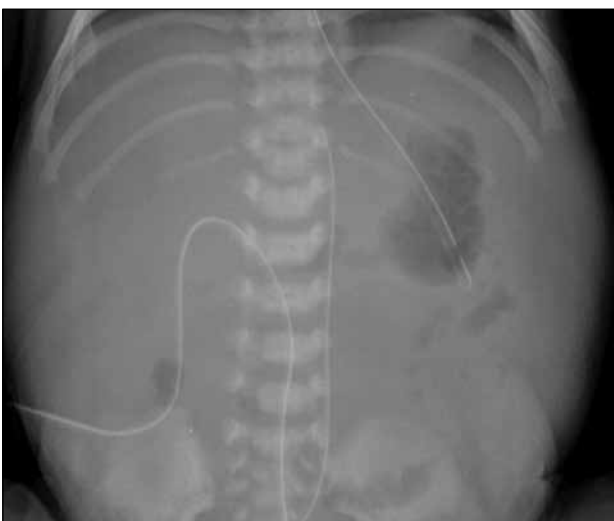

Figure 2. An abdominal radiograph after exchange transfusion showing abdominal distension is evident. The umbilical venous catheter tip is displaced inferiorly and to left of midline within the liver shadow, suggestive of an underlying mass effect in the right upper quadrant.

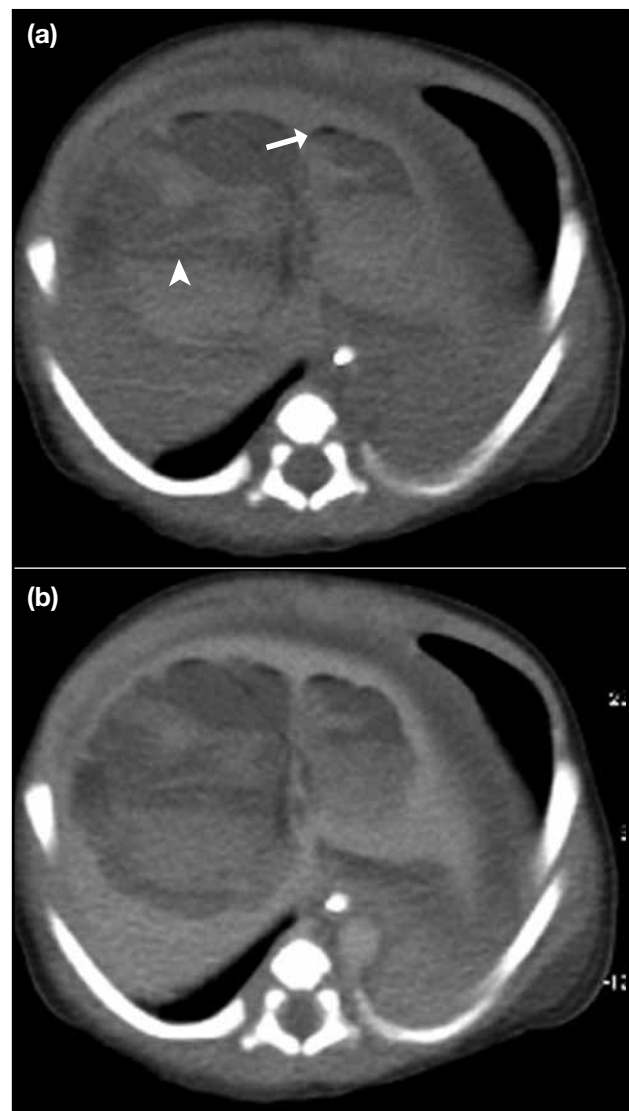


Figure 3. (a) Pre-contrast and (b) post-contrast computed tomographic liver: large space-occupying lesion in the liver with dependent hyperdense fluid-fluid level (arrowhead), compatible with haematoma. Antidependent hypodense foci are compatible with gas pockets (arrow), most likely secondary to previous umbilical venous catheterization.

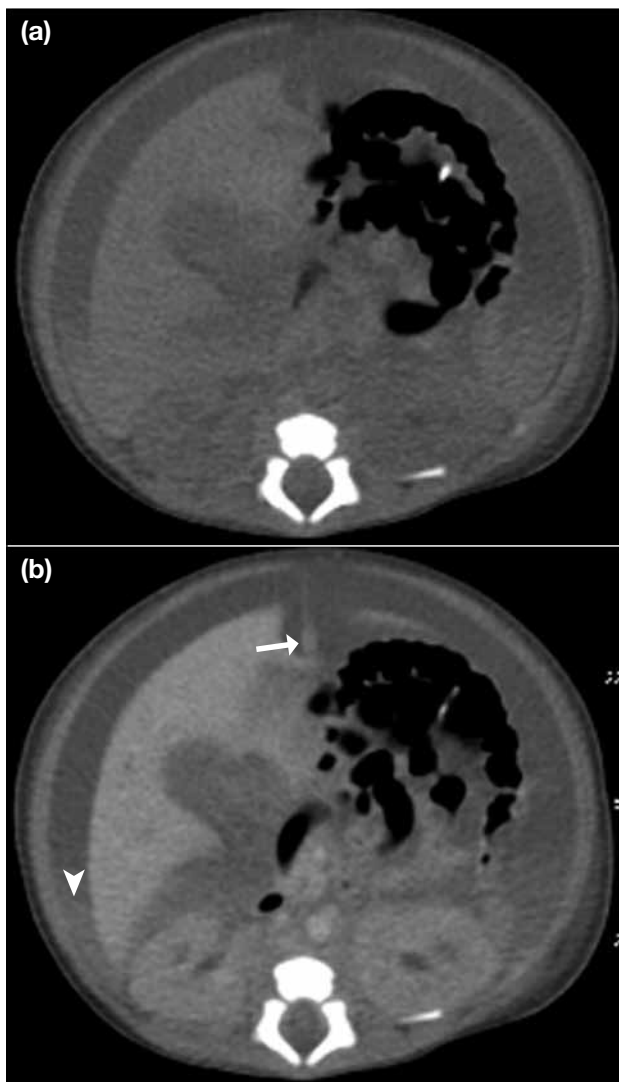


Figure 4. (a) Pre-contrast and (b) post-contrast computed tomographic abdomen: ascites with dependent hyperdense fluid level is seen, compatible with haemoperitoneum (arrowhead). The umbilical vein (arrow) appears patent below the level of liver. No pneumatosis intestinalis (suggestive of necrotising enterocolitis) is seen.

multiple tiny gas pockets was seen within the liver. It extended to the liver hilum, where the liver capsule was discontinuous. The umbilical vein, main, and right and left portal veins were shown to be intact and patent. No area of active contrast extravasation was demonstrated. Findings were compatible with haemoperitoneum and liver haematoma, which were known complications of UVC insertion for exchange transfusion.

The patient's decreasing haemoglobin and haematocrit levels were corrected by transfusion of packed cells via a femoral venous catheter, and his condition remained stable with non-operative management. The patient was deemed fit and discharge on day 14.

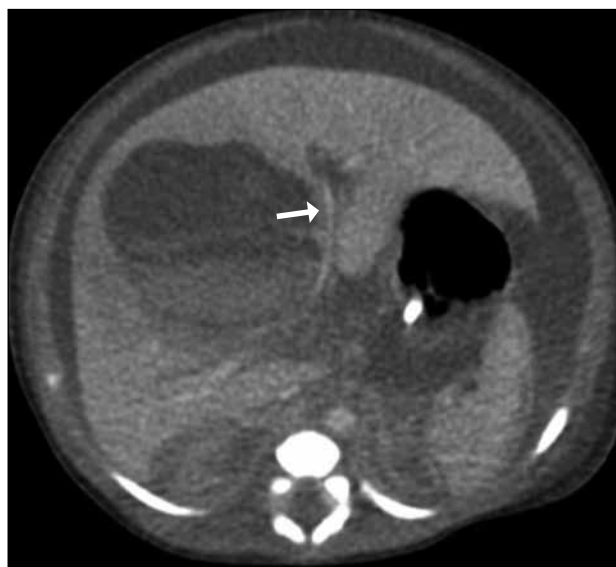

Figure 5. Left portal vein (arrow) appears stretched and compressed, but remains intact and patent; no active contrast extravasation is evident.

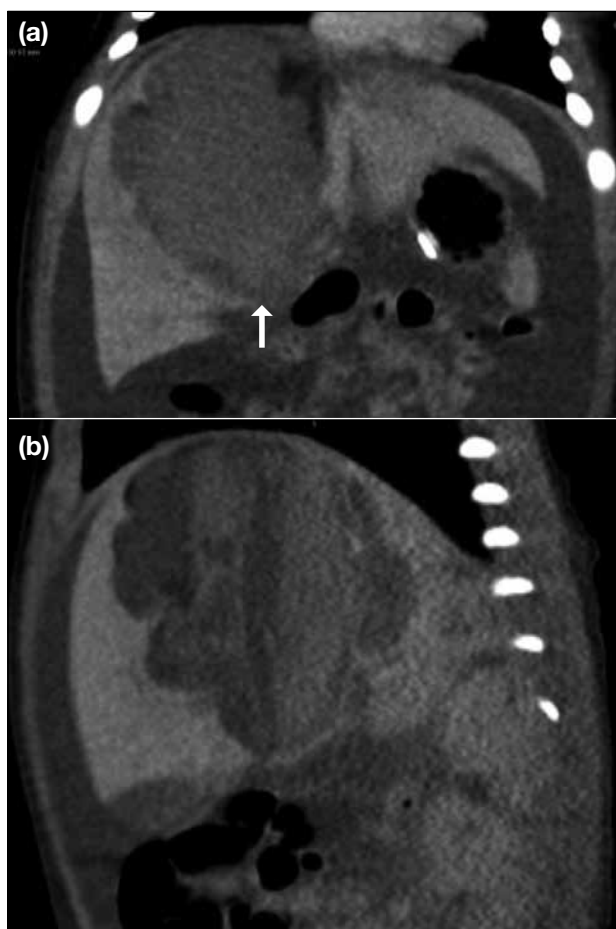


Figure 6. (a) Coronal and (b) sagittal view of post-contrast liver showing large liver haematoma with a suspicious discontinuity of the liver capsule at its inferior aspect (arrow).

Follow-up ultrasound was performed around two months after the CT, and showed a cystic mass with internal septations, echogenic debris with layering in segment 4A and 8, compatible with resolving haematoma that had decreased significantly in size (Figure 7).

DISCUSSION

Umbilical Venous Catheterization

UVC insertion is a common bedside procedure in the neonatal intensive care unit. The UVC normally courses through the umbilical vein, left portal vein, ductus venosus and inferior vena cava.¹ A properly positioned UVC runs a cephalad course at the midline evident on the frontal AXR. Its tip should be near the junction of inferior vena cava and right atrium,¹ which correlates to the level of T8 or T9 vertebral level.² In our patient, the normal course of UVC was demonstrated by the initial AXR (Figure 1).

Air might be introduced by catheterization, which was the most likely cause of gas within the liver haematoma in our patient. In the absence of pneumatosis intestinalis, necrotising enterocolitis was not considered to be the cause of intrahepatic gas in this full-term baby.

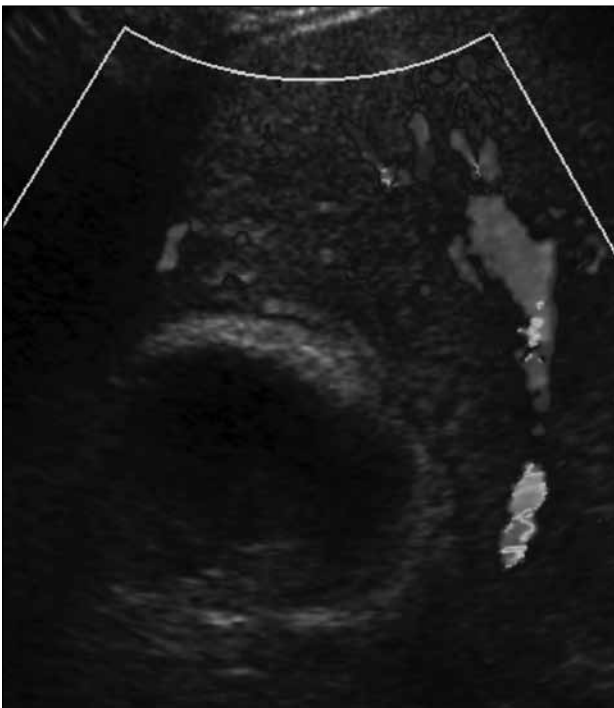


Figure 7. Ultrasonography showing liver haematoma with interval decrease in size.

Complications Related to Umbilical Venous Catheter Insertion

Vascular perforation, thrombosis, embolism, haemorrhage, infection, and organ injuries are known complications of UVC insertion.² Liver haematomas may result from intrahepatic vascular perforation, liver erosion or laceration.^{1,2} Liver parenchymal injury should be suspected in patients who develop abdominal distension after UVC insertion.² The infusion of hypertonic parenteral nutrition and dopamine before exchange transfusion might also have contributed to the liver parenchymal injury.^{3,4} Heparinised saline was infused through the UVC for maintenance of patency. Its use was probably unrelated to the liver injury because the heparin dose was far below that used to treat conditions such as deep vein thrombosis.

Lim-Dunham et al⁵ reported four neonates with liver parenchymal erosions by UVC, all four of whom developed abdominal distension within nine days. Their UVC tips were below the level of the diaphragm and projected over the liver shadow and all four had complex ascites. Our patient also had such findings on imaging that developed on day 6 after UVC insertion. The liver haematoma and haemoperitoneum were probably due to liver erosion. Two of Lim-Dunham's patients⁵ were found to have total parenteral nutrition in their ascitic fluid. Coley et al⁶ and Hui et al³ also reported cases of total parenteral nutrition ascites related to UVCs. These patients all had abdominal distension and UVCs that projected over the liver (on radiographs or ultrasound). In the reported cases, abdominal distension was a result of liver erosion and leakage of material infused through the UVCs.

The liver haematoma in our patient was most likely due to extravasation over time of the transfused blood, resulting from liver erosion by the UVC. The decrease in blood pressure after five hours could have resulted from further oozing of blood inside the liver parenchyma, disruption of the liver capsule, and leakage into the peritoneal cavity. Following supportive management and blood transfusion, the absence of contrast extravasation in the CT images and the clinical improvement was probably due to spontaneous haemostasis. A similar case of liver haematoma was reported by Kebudi et al⁷ in a patient who developed a large intrahepatic haematoma after a third exchange transfusion. Their patient, like ours, recovered fully with conservative management.

Early Detection of Liver Collections Due to Umbilical Venous Catheter-related Complications

Difficulty administering fluid through the UVC, development of abdominal distension associated with respiratory distress, and deterioration in haemodynamic status should act as alerts to complications from UVC insertion. Re-assessment of the UVC position by AXR, and comparison with previous AXRs can help to identify displacement of the UVC. Liver parenchymal injury needs to be considered, especially if abdominal distension is associated with the UVC tip projecting over the liver shadow. Ultrasound can offer a non-invasive and quick bedside assessment for any liver collection and ascites.

Management

Treatment for an intrahepatic haematoma secondary to exchange transfusion and liver erosion consists of discontinuation of the infusion, removal of UVC, close monitoring and supportive management such as transfusion and nutrition. Drainage may be necessary

if there are features of active infection, including rim enhancement evident in post-contrast CT images.

REFERENCES

1. Schlesinger AE, Braverman RM, DiPietro MA. Pictorial essay. Neonates and umbilical venous catheters: normal appearance, anomalous positions, complications, and potential aid to diagnosis. *AJR Am J Roentgenol.* 2003;180:1147-53.
2. Yiğiter M, Arda IS, Hiçsönmez A. Hepatic laceration because of malpositioning of the umbilical vein catheter: case report and literature review. *J Pediatr Surg.* 2008;43:E39-41.
3. Hui JY, Lo KK, Lo J, Chan MLM, Chan JCS. Neonatal total parenteral nutrition ascites secondary to umbilical venous catheterisation. *J Hong Kong Coll Radiol* 2001;4:288-90.
4. Venkataraman PS, Babcock DS, Tsang RC, Ballard JL. Hepatic injury: a possible complication of dopamine infusion through an inappropriately placed umbilical vein catheter. *Am J Perinatol.* 1984;1:351-4.
5. Lim-Dunham JE, Vade A, Capitano HN, Muraskas J. Characteristic sonographic findings of hepatic erosion by umbilical vein catheters. *J Ultrasound Med.* 2007;26:661-6.
6. Coley BD, Seguin J, Cordero L, Hogan MJ, Rosenberg E, Reber K. Neonatal total parenteral nutrition ascites from liver erosion by umbilical vein catheters. *Pediatr Radiol.* 1998;28:923-7.
7. Kebudi R, Uğur S, Celenk A, Uzel N. Intrahepatic hematoma: a rare complication of exchange transfusion. *Pediatr Emerg Care.* 1991;7:21-3.