

Role of Ultrasound-guided Fine-needle Aspiration of Axillary Lymph Nodes in Preoperative Staging of Breast Cancer: Correlation with Final Pathological Results and Staging

JWC Wai, JLF Chiu, TS To, KH Lai, HHC Tsang, CW Siu, SCH Chan

Department of Radiology and Imaging, Queen Elizabeth Hospital, 30 Gascoigne Road, Kowloon, Hong Kong

ABSTRACT

Objective: To retrospectively assess the sensitivity and specificity of ultrasound-guided fine-needle aspiration of axillary lymph nodes for preoperative breast cancer staging, using histological findings as a reference standard.

Methods: This was a retrospective study involving 95 consecutive adult patients having ultrasound-guided fine-needle aspiration of axillary lymph nodes performed from January to December 2010. In all, 45 (47%) of the patients had newly diagnosed carcinoma of breast. Four (4%) had axillary lymph node recurrences from a breast or lung tumour. The remainder (n = 46; 48%) did not have malignancy, showing incidentally enlarged reactive axillary lymph nodes only.

Results: The ages of the 45 women in the study group ranged from 30 to 78 (mean, 51) years. The mean primary breast cancer tumour size was 2.8 cm (range, 0.4-11.0 cm). Regarding the 45 axillary biopsies in this study, only six samples (13%) gave inconclusive results. Among these, four underwent surgery and three had positive lymph nodes. In all, 25 (56%) yielded positive fine-needle cytology findings, whilst in the remainder (n = 14; 31%), cytology was negative for malignancy. Twenty-three (51%) yielded metastatic carcinoma in the sentinel node biopsy or dissected axillary lymph node. Patients with positive ultrasound-guided fine-needle aspiration results and those with negative results were further analysed with their pathological results. Lymph nodes were more likely to be positive for metastatic disease with increased pathological tumour size. Ultrasound-guided fine-needle aspiration of axillary lymph nodes for preoperative staging is highly sensitive and specific, with satisfactory 95% confidence intervals.

Conclusion: Ultrasound-guided fine-needle aspiration of axillary lymph nodes was a highly sensitive and specific non-surgical means of staging breast cancer. Positive cytology for metastatic disease is sufficient to replace sentinel node biopsy and proceed to axillary lymph node dissection, and thus decrease the duration of anaesthesia and associated morbidity.

Key Words: Axilla; Breast neoplasms; Lymph nodes; Sentinel lymph node biopsy; Ultrasonography

Correspondence: Dr Janet Wing-chong Wai, Room 115, Block K, Department of Radiology and Imaging, Queen Elizabeth Hospital, 30 Gascoigne Road, Kowloon, Hong Kong.
Tel: (852) 2958 8888 ; Fax: (852) 2958 5653; Email: wwc053@ha.org.hk

Submitted: 12 Sep 2011; Accepted: 24 Nov 2011.

中文摘要

腋窩淋巴結超聲導引細針穿刺細胞學檢查對乳腺癌術前分期的角色： 與病理學結果和分期的關係

衛穎莊、趙朗峰、杜德信、黎國鴻、曾凱晴、蕭志偉、陳慈欽

目的：利用病理學結果作參考標準，回顧腋窩淋巴結超聲導引細針穿刺細胞學檢查對乳腺癌術前分期的敏感性及特異性。

方法：本研究回顧2010年內所有進行腋窩淋巴結超聲導引細針穿刺細胞學檢查共95名成年病人。其中45例（47%）為新確診乳腺癌，4例（4%）曾有乳腺或肺癌而現有腋窩淋巴結復發，其餘46例（48%）無惡性腫瘤只為偶發性淋巴結反應性腫大。

結果：45名病人年齡介乎30至78歲（平均51歲）。原發性乳腺癌腫瘤平均2.8 cm大小（範圍0.4-11.0 cm）。45個腋窩活檢中，只有6例（13%）的結果不確定；其中4例接受手術，3例淋巴結結果陽性。45例中有25例（56%）的細針穿刺細胞學結果呈陽性，其餘14例（31%）結果呈陰性。23例（51%）前哨淋巴結活檢或手術切開腋窩淋巴結顯示轉移癌。超聲導引細針穿刺細胞學檢查呈陽性和陰性結果的病人均再次進行病理學分析發現腫瘤越大，淋巴結有轉移癌的機會越高。腋窩淋巴結的超聲導引細針穿刺細胞學檢查對乳腺癌術前分期有高敏感度及高特異性，並有滿意的95%可信區間。

結論：腋窩淋巴結超聲導引細針穿刺細胞學檢查對乳腺癌術前分期有高敏感度及特異性。轉移癌細胞學呈陽性結果已經足以替代前哨淋巴結活檢，並繼而進行腋窩淋巴結切除，這樣可以減少麻醉時間及減低有關患病率。

INTRODUCTION

Axillary lymph node involvement remains the most important means for staging early breast cancer and is a prognostic indicator of outcome. Even in the hands of highly specialised surgeons, clinical assessment of axillary lymph nodes has proved of little value.¹ For many years axillary lymph node dissection (ALND) was the gold standard to determine the lymph node status, but was associated with substantial morbidity.² Several studies confirmed that histopathological examination of the sentinel node was reliable in predicting the total axillary lymph node involvement in breast cancer.³ If findings in the sentinel node biopsy (SNB) were negative, the axilla was considered free of disease.⁴ However, if positive, the patient was subjected to a full ALND to assess the number of nodes involved for complete staging and local disease control. In many centres, SNB has replaced ALND for surgical evaluation of axillary nodal status.⁵ However, the sentinel node procedure is time-consuming and results in prolonged periods of anaesthesia.

By detecting the involved nodes with ultrasound-guided (USG) fine-needle aspiration cytology (FNAC)

preoperatively, the sentinel node procedure is no longer needed. Evaluation by ultrasonography of the axilla by USG-guided fine-needle aspiration has been shown to offer a means of non-surgical staging of the axilla.⁶ The procedure, with almost no morbidity, is quick and minimally painful. When there is a negative result, the patient undergoes SNB for further evaluation, which can be omitted if the finding is positive, and undergoes ALND directly.

Despite various potential benefits of USG-FNAC, the procedure is still not widely used for preoperative axillary staging in patients with breast carcinoma. Therefore we set out to retrospectively assess our local experience with respect to the sensitivity and specificity of USG-FNAC of axillary lymph nodes for preoperative staging of breast cancers across a range of pathological stages, based on histological findings as a reference standard.

METHODS

This was a retrospective study of 95 consecutive adult patients with USG-FNAC of axillary lymph nodes performed during the period from January to December

2010. In all, 45 (47%) of the patients had newly diagnosed carcinoma of breast. Four (4%) had axillary lymph node recurrence after a previous history of breast or lung tumour. The remainder (n = 46; 48%) did not have malignancy but had incidentally enlarged reactive axillary lymph node only. Thus, only the 45 patients with newly found carcinoma of breast were included in this analysis. Their clinical data and radiological images were retrieved from the electronic patient record, Radiology Information System, and Picture Archiving and Communication System.

Surgical and pathological records were reviewed to determine the final pathological staging. Patient data retrieved included age, primary pathological tumour size, tumour histology, and preoperative USG-FNAC results. The staging was made by pathologists according to the latest American Joint Committee on Cancer staging system and World Health Organization classification, and graded according to Bloom and Richardson's method. The size criteria were: for T1 was 2 cm or smaller; for T2, larger than 2 cm and smaller than or equal to 5 cm; for T3, larger than 5 cm; and for T4, inflammatory carcinoma determined by positive results in the skin biopsy. Ultrasound images saved at the aspiration procedure were respectively reviewed for each patient.

Prior to USG-FNAC, assessment of axillary lymph nodes was performed in real time by radiologists specialised in breast imaging, using high-resolution (M12 linear probe) ultrasonography equipment (General Electric LOGIQ 9; United States). Visible lymph nodes were identified and measured, and their transverse and sagittal images were recorded on film. The most suspicious lymph node, that with the most replaced hilum in the ipsilateral axilla, was selected for aspiration by the radiologist performing the procedure. Other suspicious sonographic features included axillary lymph nodes with an eccentric hilum, thickened cortices and / or lobulated cortices. If more than one node had a completely replaced hilum, the largest was selected. Even if the lymph nodes appeared normal, the largest node was selected. Written informed consent was obtained for each procedure. In all cases, no immediate post-procedural complications were encountered by the radiologists.

All USG-FNAC procedures were performed with a 22G needle attached to a 10-ml syringe via a short extension tube and under manual suction. For suspicious lymph nodes, areas of the thickened cortices were included and aspirated with to-and-fro movements. In patients with indeterminate or relatively normal lymph nodes, areas where the cortices were most thickened, were

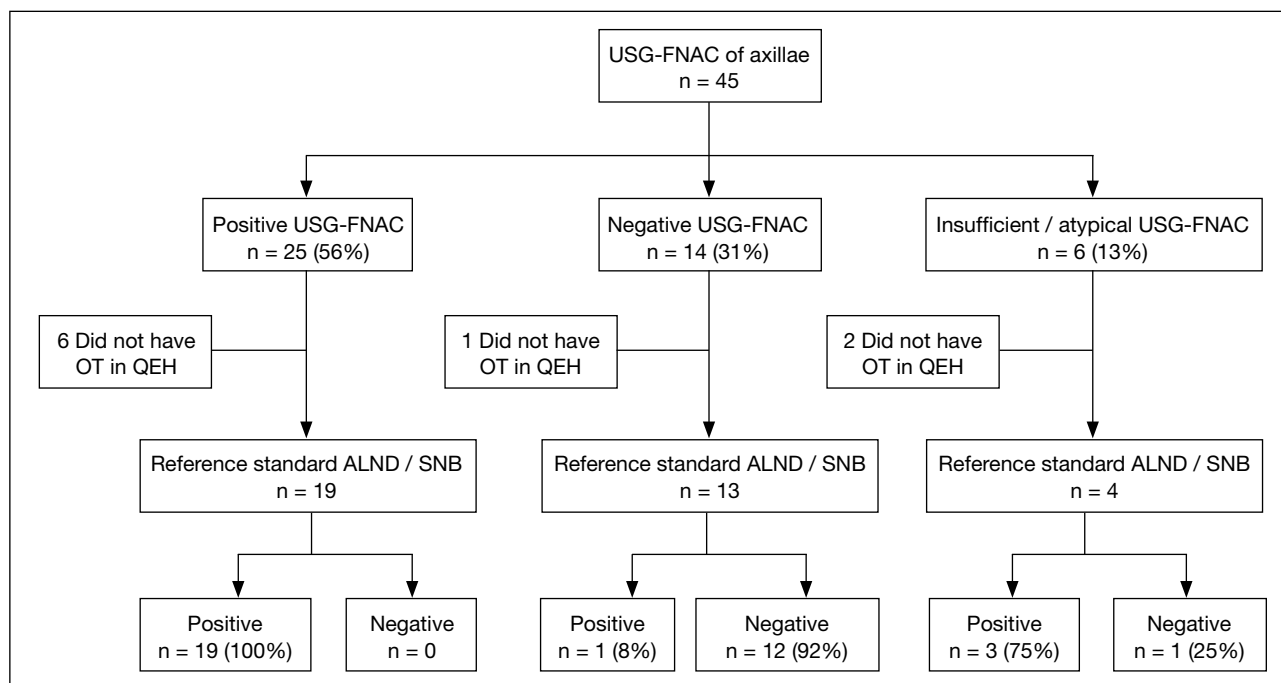


Figure 1. Flowchart shows results of ultrasound-guided fine-needle aspiration in patients and their histological results.

Abbreviations: USG-FNAC = ultrasound-guided fine-needle aspiration cytology; OT = operation; QEH = Queen Elizabeth Hospital; ALND = axillary lymph node dissection; SNB = sentinel node biopsy.

targeted with jerky motions. The aspirate was placed in a solution prepared by the pathology department and sent directly to the laboratory for processing on the same day. All the cytology results were assessed by pathologists according to criteria accepted by National Health Service, United Kingdom: C1 = insufficient cells for cytology analysis; C2 = cells present all benign; no suspicious features; C3 = cells suspicious but probably benign; C4 = cells suspicious but probably malignant; C5 = definitely malignant.

Lymph nodes obtained during surgical excision by SNB or ALND were all examined using standard haematoxylin-eosin-stained sections. Final histopathological findings for excised lymph nodes were used as the reference standard (positive vs. negative). Sensitivity and specificity were calculated for USG-FNAC results, and corresponding 95% confidence intervals were calculated by the normal approximation interval and Wilson score interval methods. The results were presented according to the pathological size of the tumours.

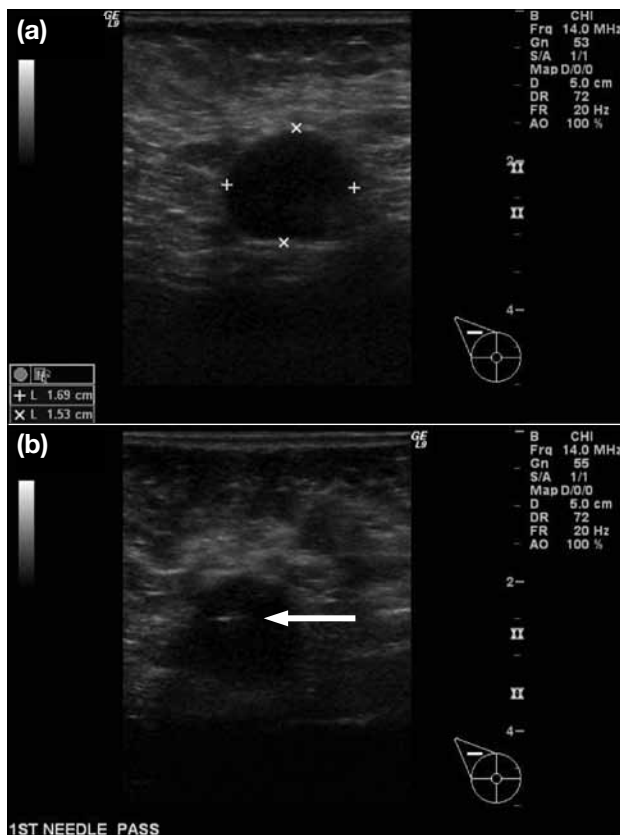


Figure 2. Transverse ultrasound-guided images of malignant axillary lymph node. (a) Image shows loss of fatty hilum with thickened cortex. (b) Ultrasound-guided fine-needle aspiration with tip of needle (arrow) in the suspicious portion of the cortex.

RESULTS

The 45 women patients in the study group were aged 30 to 78 (mean, 51) years. The mean primary breast tumour size was 2.8 cm (range, 0.4-11.0 cm); 41 (91%) were invasive ductal carcinoma, two (4%) were invasive lobular carcinoma, one (2%) was medullary, and one (2%) was a papillary carcinoma.

Of the 45 axillae studied, only six (13%) yielded inconclusive results. Among these, four patients underwent an operation and three were found to have positive lymph nodes. In all, 25 (56%) of the patients yielded positive FNAC, of whom six did not have their operation in our centre, and the other 19 all had concordant, histopathologically positive lymph nodes. The cytology of the remaining patients (n = 14; 31%) was negative for malignancy. One patient did not undergo operation in our centre, and one showed a positive pathological result. The remaining 12 showed

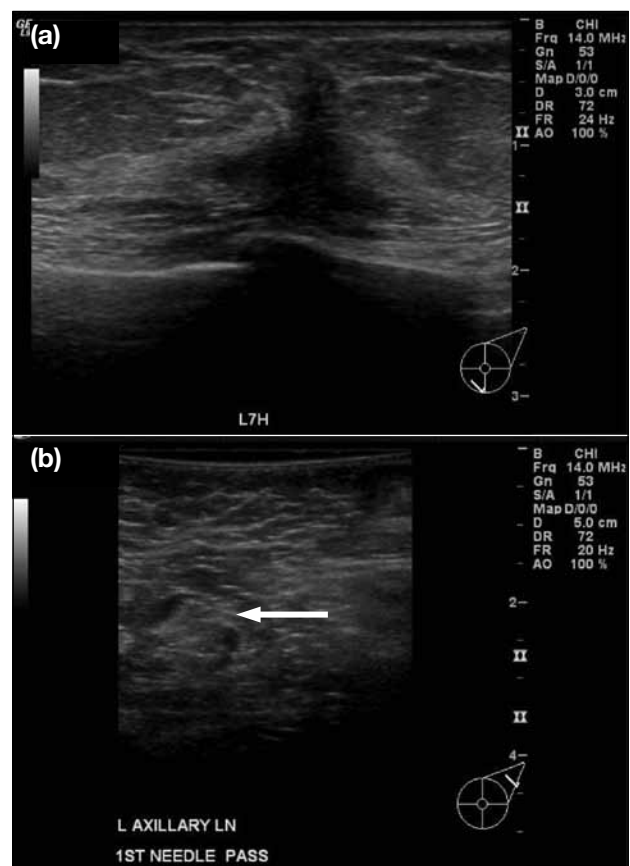


Figure 3. Transverse ultrasound-guided image of a benign axillary lymph node in a patient with carcinoma of the left breast. (a) Hypoechoic 'taller than wide' spiculated mass in left breast, biopsy confirmed invasive ductal carcinoma. (b) Image of axillary lymph node shows oval shape, thin cortex and central fatty hilum, with an arrow showing the tip of needle for aspiration.

concordant results. Thus, 23/45 (51%) were positive for metastatic carcinoma at SNB or ALND. The details in each subgroup are shown in Figure 1.

Patients with positive USG-FNAC (Figure 2) and those with negative USG-FNAC (Figure 3) were further analysed regarding their pathological results that are shown in Tables 1 to 3. Lymph nodes were more likely to be positive for metastatic disease for large-sized tumours. Thus, USG-FNAC of axillary lymph nodes for preoperative breast cancer staging was highly sensitive and specific, and yielded satisfactory 95% confidence intervals calculation using the normal approximation interval and Wilson score interval methods.

Table 1. Examination results according to pathological tumour size.*

Parameter	T1	T2	T3	T4	Total
No. of axillae	16	12	3	1	32
Final histological results					
Negative					
N0	8	4	0	0	12
Positive					
N1	4	4	0	1	9
N2	2	2	1	0	5
N3	2	2	2	0	6
USG-FNAC cytology results					
Negative	9	4	0	0	13
Positive	7	8	3	1	19

Abbreviation: USG-FNAC = ultrasound-guided fine-needle aspiration cytology.

* T1 = ≤2 cm; T2 = >2 cm and ≤5 cm; T3 = >5 cm; T4 = inflammatory carcinoma determined by positive results in the skin biopsy.

Table 2. Cytological findings according to pathological tumour size.*

USG-guided FNAC	T1		T2		T3		T4		Total	
	+ve	-ve	+ve	-ve	+ve	-ve	+ve	-ve	+ve	-ve
Positive	7	0	8	0	3	0	1	0	19	0
Negative	1	8	0	4	0	0	0	0	1	12

Abbreviation: USG-FNAC = ultrasound-guided fine-needle aspiration cytology.

* T1 = ≤2 cm; T2 = >2 cm and ≤5 cm; T3 = >5 cm; T4 = inflammatory carcinoma determined by positive results in the skin biopsy.

Table 3. Accuracy of ultrasound-guided fine-needle aspiration cytology results of axillary lymph nodes according to pathological tumour size.*

Parameter	T1	T2	T3	T4	Total
Sensitivity	87.5% (78.8-100)	100% (75.8-100)	100% (43.9-100)	100% (20.7-100)	95.0% (87.5-100)
Specificity	100% (80.6-100)	100% (75.8-100)	-	-	100% (89.3-100)

* Data in parentheses are 95% confidence intervals. T1 = ≤2 cm; T2 = >2 cm and ≤5 cm; T3 = >5 cm; T4 = inflammatory carcinoma determined by positive results in the skin biopsy.

DISCUSSION

Non-palpable axillary lymph nodes can be detected by ultrasound. Regrettably, the accuracy of this technique for the selection of node-negative or -positive patients is relatively low, with the sensitivity being 36 to 73% and the specificity between 70 and 100%.^{7,8} A simple, reliable preoperative assessment of axillary lymph node status in patients with primary breast cancer would be of great value for the patient and surgeon, especially since the introduction of the sentinel node procedure. It could save time and costs by avoiding the latter procedure if metastases were found. A combined approach using ultrasonography and USG-FNAC results appeared promising in our series and various other studies. Deurloo et al⁹ demonstrated that FNAC of axillary lymph nodes (with 56% being positive) reduced recourse to the sentinel node procedure by 14%. Kuenen-Boumeester et al¹⁰ examined 183 nodes, and although only 20% were positive, sentinel node procedures were reduced by 21%. All 19 cases showing positive FNAC in our series were true positives on histological examination, which shows that specificity and positive predictive value of USG-FNAC were both 100%. Cytologically, one of our patients had a false-negative result and was found to have micrometastases only in the histological result. The overall negative predictive value (NPV) of 92.3% in our sample was very promising compared to another study.¹⁰ In addition, the NPV under the tumour size categorisation of T2, T3, and T4 were all 100%.

Although the biological significance of these micrometastases is still being discussed, it is clear that

neither ultrasound nor cytology can replace histology in the detection of these metastases. One limit of FNAC is inadequate sampling due to technical problems, when nodes could not be reached, or there was insufficient sampling. This occurred in 13% of our samples, which is comparable to the inadequacy rate reported in other studies.⁹⁻¹¹

Screening programmes have led to an earlier diagnosis of breast cancer and therefore smaller invasive cancers.¹² Moreover, the size of the tumour is related to the number of nodes involved.¹³ In our series, USG-FNAC could identify 54% of histologically proven axillary metastases in primary breast cancer patients with pT1 and pT2 tumours. Thus, the sentinel node procedure could be avoided, saving considerable operating time as the surgeon can proceed to axillary dissection without waiting for frozen sections and avoid a second operation later.

As this was a retrospective study, there were no standard criteria to patient selection for the USG-FNAC procedure. Some of patients with a large tumour (>3 cm) and sonographically detectable lymph nodes considered as abnormal, may have been automatically excluded for the procedure and proceed directly to ALND.¹⁴ Thus, a prospective study of all patients with newly diagnosed breast cancer is needed to further define the role for USG-FNAC in the initial staging of the axilla.

CONCLUSION

Ultrasonographic evaluation of the axilla with USG-FNAC of the axilla has been shown to be a highly sensitive and specific non-surgical means for breast cancer staging. Cytology positive for metastatic disease is sufficient to replace SNB and to proceed to ALND. This can reduce the duration of anaesthesia and associated morbidity.

REFERENCES

1. Lannig C, Hoffmann J, Galatius H, Engel U. Assessment of clinical

- palpation of the axilla as a criterion for performing the sentinel node procedure in breast cancer. *Eur J Surg Oncol.* 2007;33:281-4.
2. Warmuth MA, Bowen G, Prosnitz LR, Chu L, Broadwater G, Peterson B, et al. Complications of axillary lymph node dissection for carcinoma of the breast: a report based on a patient survey. *Cancer.* 1998;83:1362-8.
3. Veronesi U, Paganelli G, Galimberti V, Viale G, Zurrida S, Bedoni M, et al. Sentinel-node biopsy to avoid axillary dissection in breast cancer with clinically negative lymph-nodes. *Lancet.* 1997;349:1864-7.
4. Jeruss JS, Winchester DJ, Sener SF, Brinkmann EM, Bilimoria MM, Barrera E Jr, et al. Axillary recurrence after sentinel node biopsy. *Ann Surg Oncol.* 2005;12:34-40.
5. Dequanter D, Hertens D, Veys I, Nogaret JM, Larsimont D, Bourgeois P [in French]. Sentinel node involvement in T0-T1 breast cancers. *Ann Chir.* 2001;126:654-8.
6. Sapino A, Cassoni P, Zanon F, Fraire F, Croce S, Coluccia C, et al. Ultrasonographically-guided fine-needle aspiration of axillary lymph nodes: role in breast cancer management. *Br J Cancer.* 2003;88:702-6.
7. Bonnema J, van Geel AN, van Ooijen B, Mali SP, Tjiam SL, Henzen-Logmans SC, et al. Ultrasound-guided aspirations biopsy for detection of nonpalpable axillary node metastases in breast cancer patients: a new diagnostic method. *World J Surg.* 1997;21:270-4.
8. de Kanter AY, van Eijck CH, van Geel AN, Kruijt RH, Henzen SC, Paul MA, et al. Multicentre study of ultrasonographically guided axillary node biopsy in patients with breast cancer. *Br J Surg.* 1999;86:1459-62.
9. Deurloo EE, Tanis PJ, Gilhuijs KG, Muller SH, Kröger R, Peterse JL, et al. Reduction in the number of sentinel lymph node procedures by preoperative ultrasonography of the axilla in breast cancer. *Eur J Cancer.* 2003;39:1068-73.
10. Kuenen-Boumeester V, Menke-Pluymers M, de Kanter AY, Obdeijn IM, Urich D, Van Der Kwast TH. Ultrasound-guided fine needle aspiration cytology of axillary lymph nodes in breast cancer patients. A preoperative staging procedure. *Eur J Cancer.* 2003;39:170-4.
11. van Rijk MC, Deurloo EE, Nieweg OE, Gilhuijs KG, Peterse JL, Rutgers EJ, et al. Ultrasonography and fine-needle aspiration cytology can spare breast cancer patients unnecessary sentinel lymph node biopsy. *Ann Surg Oncol.* 2006;13:31-5.
12. Tabar L, Duffy SW, Krusemo UB. Detection method, tumour size and node metastases in breast cancers diagnosed during a trial of breast cancer screening. *Eur J Cancer Clin Oncol.* 1987;23:959-62.
13. Carter GL, Allen C, Henson DE. Relation of tumor size, lymph node status and survival in 24,740 breast cancer cases. *Cancer.* 1989;63:181-7.
14. Management of Breast Cancer. Hospital Authority Clinical Practice Guideline 2007. Available from <http://www.ha.org.hk/visitor/>