
CASE REPORT

Radiological Features of Osteogenesis Imperfecta Type V: a Report of Two Cases

PKT Hui¹, JYL Tung², MKT To³, W Chow³, WWM Lam¹, MT Chau¹

¹Department of Radiology, and ²Department of Paediatrics and Adolescent Medicine, Queen Mary Hospital, The University of Hong Kong, Pokfulam Road, Hong Kong; ³Department of Orthopaedics & Traumatology, The Duchess of Kent Children's Hospital, Sandy Bay, Hong Kong

ABSTRACT

Osteogenesis imperfecta type V is a rare subtype of osteogenesis imperfecta with unique clinical, radiological, and histological features. Herein, we report two paediatric patients with osteogenesis imperfecta type V, both presenting with recurrent bone fractures since early childhood and the classical radiological features of osteogenesis imperfecta type V (calcified radio-ulnar interosseous membrane). One of them also developed hypertrophic callus formation. Knowledge and recognition of these specific radiographic findings can facilitate a timely diagnosis of osteogenesis imperfecta type V, which may have significant implications on management. Such consideration includes bisphosphonate use (a well-established treatment for certain disease subtypes of osteogenesis imperfecta), but may lead to progression of hypertrophic callus in osteogenesis imperfecta type V.

Key Words: Bony callus; Calcinosis; Child; Fractures, bone; Osteogenesis imperfecta

中文摘要

成骨不全症第五型的影像特徵：兩個病例報告

許其達、童月玲、杜啟峻、周宏、林慧文、周明德

成骨不全症第五型是一種罕見的成骨不全症亞型，有其獨特的臨床、影像及病理學特徵。本文報告兩名成骨不全症第五型的小兒患者，他們在年幼時經常有骨折的情況，並有成骨不全症第五型的典型影像特徵，即橈尺骨間膜鈣化。其中一名患者出現膨脹型骨痂形成。認識這些特有的影像特徵有助加快診斷成骨不全症第五型，因此對治療有重大意義。醫生可考慮的治療方法包括使用雙磷酸鹽藥物（一種對於成骨不全症一些亞型行之有效的治療），但這療法可導致患者膨脹型骨痂形成。

INTRODUCTION

Osteogenesis imperfecta (OI) is a heterogeneous condition classified into various subtypes. Clinically, the disease is characterised by bone fragility, typically manifesting as recurrent bone fractures, short stature,

hyperlaxity of joints, and presence of wormian bones. OI type V was previously a subtype of type IV, and later considered to be a distinct clinical entity with its unique clinical, radiological, and histological features and absence of COL1A 1/2 mutations.^{1,2} It has several

Correspondence: Dr Peter KT Hui, Department of Radiology, Queen Mary Hospital, 102 Pokfulam Road, Hong Kong.
Tel: (852) 2255 3284; Email: hkt012@ha.org.hk

Submitted: 11 May 2011; Accepted: 27 Jul 2011.

radiological features that allow its differentiation from other subtypes. To date, only 36 cases of OI type V have been reported in the literature,³ which accounts for around 4 to 5% of all OI patients.⁴ We report two patients with this condition, both currently under multidisciplinary care by the departments of paediatrics and orthopaedic surgery in our institution. Distinguishing OI type V from other subtypes may have important implication on patient management, particularly the consideration of bisphosphonate therapy.

CASE REPORTS

Case 1

The first patient was a 14-year-old boy, born to a non-consanguineous Chinese couple, with no family history of bone disease, hearing problem, or visual impairment. He presented at birth with bilateral clavicle and multiple rib fractures after assisted breech delivery in March 1996. A diagnosis of OI was made by an orthopaedic surgeon before the age of 3 years. Clinically the patient did not exhibit blue sclera, dental or hearing problems. Subsequently, he suffered from recurrent fractures of at least five long bones as well as collapse of multiple vertebrae. With the onset of puberty, his condition improved and the fracture frequency decreased. He was placed on conservative treatment, namely a back brace and physiotherapy.

Due to significant limb length discrepancy, he underwent an anterior closing wedge osteotomy of the right distal femur at the age of 13 years. Three months after surgery, he started to develop enlarging, painful swelling at the operative site. Radiograph of the right femur showed well-defined sclerotic masses over the distal femur (Figure 1a). Magnetic resonance imaging yielded T1-weighted hyperintense lesions at the distal femoral shaft with the appearance of tumour masses (Figure 1b). Bone biopsy of the lesion was performed seven months after surgery, which showed bony tissue featuring endochondral ossification, formation of woven bone adjacent to native bone trabeculae, and no evidence of malignancy. Overall features were suggestive of hypertrophic callus formation. Review of patient's previous radiographs showed generalised osteopenia, bowing of long bones, and calcification of the interosseous membranes in both forearms (Figure 1c). The clinical, radiological, and histological features were compatible with OI type V. The paediatricians were consulted for symptom control and bisphosphonate treatment. After due consideration,

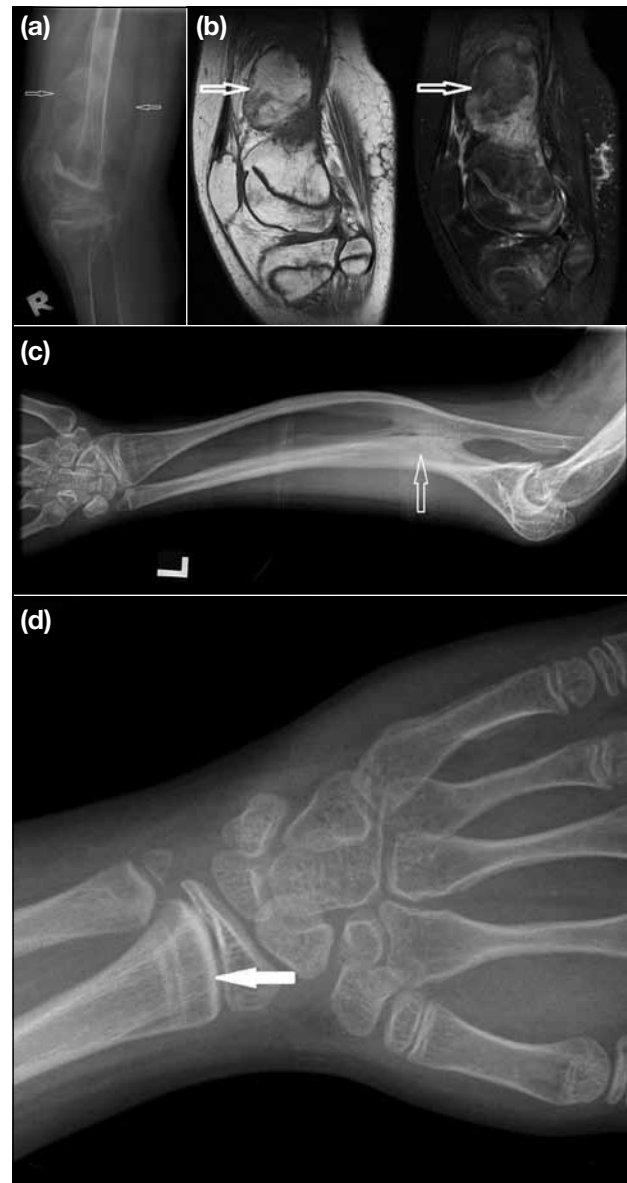


Figure 1. Patient 1: (a) A lateral radiograph of the right knee: he developed painful swelling at the right distal femur 3 months after anterior wedge osteotomy; this radiograph shows multi-lobulated, calcified masses at the right distal femur around the operative site (open arrows). (b) Corresponding magnetic resonance images of the right knee after operation: selected sagittal (left) T1-weighted (T1W) and (right) T2-weighted (T2W) images of the right distal femur demonstrated lobulated, well-defined T1W hyperintense, T2W hypointense lesions around the operative site, with the appearance of tumour mass (open arrows). Biopsy of the lesion was performed, which showed no evidence of malignancy. It was considered to represent hypertrophic callus formation. (c) A radiograph of the left forearm: there were generalised osteopenia, bowing of long bones, and grade III radioulnar interosseous membrane ossification (open arrow). (d) An anteroposterior radiograph of left distal radius showing radiodense metaphyseal band adjacent to the growth plate (solid arrow), another characteristic feature of osteogenesis imperfecta type V.

bisphosphonate was not started in view of its anti-resorption effect possibly leading to progression of the hypertrophic callus.

Case 2

A 16-year-old boy born in mainland China presented with recurrent multiple fractures over the long bones and spine since infancy in April 1993. Clinically, he had no hearing problem, blue sclera, or dental malformation. He developed contractures of multiple joints, and required a walking aid and stick, despite relatively normal muscle power. According to the patient, he was told he was suffering from some kind of “syndromal disorder”, and was taking conservative treatment including calcium supplements. He came to Hong Kong at the age of 14 years to seek medical advice, and was referred to the paediatrics department for his recurrent bone fractures. Skeletal survey showed generalised osteopenia, wormian bones in the skull, calcifications of the radioulnar interosseous membranes in both forearms (Figure 2a), and bowing of long bones. Subsequently, he also developed dislocation of the radial heads (Figure 2b). Skin biopsy showed normal histology and no COL1A 1/2 mutation was identified. Bone biopsy was also performed and showed decreased bone trabeculae and an increase in osteocytes without significant osteoclastic activity. The overall features in this patient were compatible with OI type V. He was prescribed regular doses of intravenous bisphosphonate, and has not suffered further fractures (over a period of >50 months) since commencing this treatment.

DISCUSSION

Notably, OI is one of the commonest inherited disorders of connective tissue consisting of a heterogeneous group of diseases characterised by susceptibility to bone fractures of variable severity and diverse phenotype, genotype and phenotype-genotype correlations.³ A classification was first proposed by David Sillence in 1979 (Sillence classification), there being types I to IV based on clinical and radiological findings and mode of inheritance.⁵ Classic OI is characterised by features including blue sclera, dentinogenesis imperfecta and hearing impairment, and subsequently it was appreciated that not all patients had severe (rapidly lethal) OI associated with a collagen type I mutation,⁶ which led to expansion of the original Sillence classification in 2004.⁴ By 2007, eight types of OI (I-VIII) were included in the classification.⁷

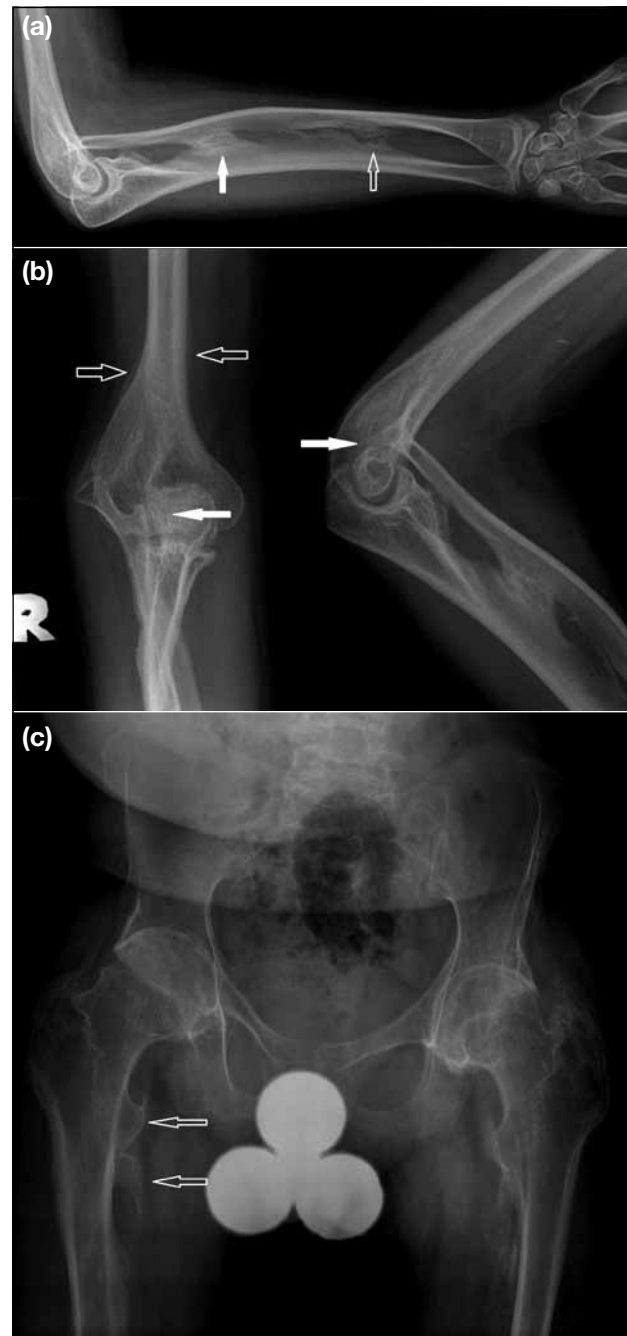


Figure 2. Patient 2: (a) A radiograph of the right forearm shows grade II (open arrow) and grade III (solid arrow) interosseous membrane ossifications. (b) (left) Frontal and (right) lateral radiographs of the right elbow: secondary dislocation of the radial head was seen due to interosseous membrane ossification (solid arrows). Smooth, undulating periosteal reactions were also noted along the medial and lateral aspects of right distal humerus (open arrows). This was a generalised feature seen along various long bones in both patients. (c) A radiograph of the pelvis shows multiple heterotopic ossifications around the pelvic bones, bilateral hip joints, and bilateral proximal femur. Some of them had a spur-like appearance (open arrows).

OI type V was first described in 2000, and considered to be a distinct clinical entity with its unique clinical, radiological, and histological features.¹ It is moderately severe, and the prognosis is similar to OI type IV in terms of frequency of fractures and the degree of skeletal deformity. Patients have normal sclera and teeth. Radiologically, diagnostic criteria include the triad of radioulnar interosseous membrane calcification, hypertrophic callus formation at fracture or postoperative sites, and radiodense metaphyseal bands adjacent to growth plates. Histologically, it was distinguished by a mesh-like pattern of lamellation evident using polarised light microscopy iliac bone samples.

Ossification of interosseous membrane of the forearm appears to be a constant and specific feature for OI type V. According to Lee et al,⁸ three grades can be recognised on anteroposterior radiographs: grade I — incomplete ossification of the interosseous membrane with a clear space ≥ 2 mm wide; grade II — incomplete ossification of the interosseous membrane with a clear space of < 2 mm wide; and grade III — definite bony connection between both forearm bones via the interosseous membrane. Both of our patients had ossification of interosseous membranes in both forearms (Figures 1c and 2a). Ossification was also present in both lower extremities of one of the patients, and in the left leg of the other. The presence of ossification severely limits movement of the forearm, and is associated with secondary dislocation of the radial head.^{1,4} This was present bilaterally in both patients (Figures 1c, 2a and b). Fassier et al⁹ reported that the frequency of radial head dislocation / subluxation was significantly higher in OI type V (86%) compared to other subtypes (0-29%). Since these anomalies appear to be specific, interosseous membrane ossification (with or without radial head dislocation) in a paediatric patient should prompt radiologists to consider OI type V as the diagnosis.

The formation of hypertrophic callus, if present, is the most conspicuous clinical abnormality in OI type V (Figures 1a and b).¹ While not all OI type V patients have hypertrophic callus formation, all those who have it can be regarded as having OI type V.^{1,10} Lesions mainly form during growth periods at sites of rapid periosteal apposition. Long bones are mostly affected, particularly in the lower extremities,¹⁰ and can be precipitated by fractures, surgery (as in our first patient), or arise spontaneously. They can become very large and

even mimic osteosarcoma.^{4,11} According to Rieker et al¹² and Dobrocky et al,¹³ magnetic resonance imaging and computed tomography may be helpful in distinguishing hypertrophic callus from sarcoma. Cheung et al^{10,14} reported that evolution of the lesion was variable, and ranged from complete radiological and clinical resolution to significant morbidity, both in the acute phase and in the long term.

The differential diagnosis of OI type V included non-accidental injury, neuropathic arthropathy, renal osteodystrophy, paralytic states, and the consequences of steroid therapy.¹⁵ Differentiation, however, should not be difficult in the presence of an appropriate patient history and other associated features.

According to the report of Glorieux et al,¹ all patients in their series of OI type V had radiodense metaphyseal bands. This feature was also present in our first patient (Figure 1d). The exact cause for this is unknown, however. Various other radiological features in our patients could be important in the understanding of OI type V. Notably, both patients developed generalised undulating periosteal reactions in multiple long bones (Figure 2b). Moreover, multiple heterotopic ossifications were noted in the proximal femur bilaterally, and in the right distal femur of patient 2 (Figure 2c). We believed that these features are also important in OI type V, and their significance awaits further assessment in the future. The presence of periosteal reactions, heterotopic ossifications, tendency to hypertrophic callus formation, and ossification of interosseous membrane likely represent a spectrum of hyperproliferative processes at the periosteal level. Whether these pathologies share the same mechanism at the cellular level, or whether there is any genetic basis to them, warrants further investigation.

Concerning management of OI, bisphosphonates (like pamidronate) constitute well-established treatment for symptomatic patients with OI types I, III, and IV. However, little information is available on its effect on OI type V, especially with regard to the progression of hypertrophic callus.¹⁶ Since pamidronate is an antiresorptive agent, it may theoretically facilitate the progression of hypertrophic callus instead of limiting its expansion or helping in its resolution. However, no established guideline on which patient should receive treatment is available to date. Therefore, any medical treatment offered must be individualised, with potential risks balanced against benefits.

CONCLUSION

OI type V is a unique subtype with characteristic radiological features that must be looked for to make a correct diagnosis. Ossification of the interosseous membrane is believed to be a highly suggestive feature, while hypertrophic callus formation is probably the most debilitating feature of OI type V. We have described other radiological features that are potentially important in the diagnosis of OI type V.

REFERENCES

1. Glorieux FH, Rauch F, Plotkin H, Ward L, Travers R, Roughley P, et al. Type V osteogenesis imperfecta: a new form of brittle bone disease. *J Bone Miner Res.* 2000;15:1650-8.
2. Roughley PJ, Rauch F, Glorieux FH. Osteogenesis imperfecta — clinical and molecular diversity. *Eur Cell Mater.* 2003;5:41-7.
3. Van Dijk FS, Pals G, Van Rijn RR, Nikkels PG, Cobben JM. Classification of Osteogenesis Imperfecta revisited. *Eur J Med Genet.* 2010;53:1-5.
4. Rauch F, Glorieux FH. Osteogenesis imperfecta. *Lancet.* 2004;363:1377-85.
5. Silience DO, Senn A, Danks DM. Genetic heterogeneity in osteogenesis imperfecta. *J Med Genet.* 1979;16:101-16.
6. Wallis GA, Sykes B, Byers PH, Mathew CG, Viljoen D, Beighton P. Osteogenesis imperfecta type III: mutations in the type I collagen structural genes, COL1A1 and COL1A2, are not necessarily responsible. *J Med Genet.* 1993;30:492-6.
7. Cabral W, Chang W, Barnes A, Weis M, Scott M, Leikin S, et al. Prolyl 3-hydroxylase 1 deficiency causes a recessive metabolic bone disorder resembling lethal/severe osteogenesis imperfecta. *Nat Genet.* 2007;39:359-65.
8. Lee DY, Cho TJ, Choi IH, Chung CY, Yoo WJ, Kim JH, et al. Clinical and radiological manifestations of osteogenesis imperfecta type V. *J Korean Med Sci.* 2006;21:709-14.
9. Fassier AM, Rauch F, Aarabi M, Janelle C, Fassier F. Radial head dislocation and subluxation in osteogenesis imperfecta. *J Bone Joint Surg Am.* 2007;89:2694-704.
10. Cheung MS, Florieux FH, Rauch F. Natural history of hyperplastic callus formation in osteogenesis imperfecta type V. *J Bone Miner Res.* 2007;22:1181-6.
11. Vieira RL, Amaral DT, Jesus-Garcia FR, Saraiva G, Fernandes AR, Resnick D. Hyperplastic callus formation in osteogenesis imperfecta type V mimicking osteosarcoma: 4-year follow-up with resolution. *Skeletal Radiol.* 2006;35:402-5.
12. Rieker O, Kreitner KF, Karbowski A. Hyperplastic callus formation in osteogenesis imperfecta: CT and MRI findings. *Eur Radiol.* 1998;8:1137-9.
13. Dobrocky I, Seidl G, Grill F. MRI and CT features of hyperplastic callus in osteogenesis imperfecta tarda. *Eur Radiol.* 1999;9:665-8.
14. Cheung MS, Azouz EM, Glorieux FH, Rauch F. Hyperplastic callus formation in osteogenesis imperfect type V: follow-up of three generations over ten years. *Skeletal Radiol.* 2008;37:465-7.
15. Davies SG. Aids to radiological differential diagnosis. Saunders: Elsevier Science; 2009. p 454-5.
16. Zeitlin L, Rauch F, Travers R, Munns C, Glorieux FH. The effect of cyclical intravenous pamidronate in children and adolescents with osteogenesis imperfecta type V. *Bone.* 2006;38:13-20.