
ORIGINAL ARTICLE

Whole-body Fluorodeoxyglucose Positron Emission Tomography–Computed Tomography for Suspected or Confirmed Brain Metastasis

RKL Lee¹, K Wang¹, AWH Ng¹, CB Ip¹, JSY Lam¹, EHY Yuen¹, TCY Cheung¹, YYP Lee¹, TM Chan²

¹Department of Imaging and Interventional Radiology; and ²Department of Neurosurgery, Prince of Wales Hospital, The Chinese University of Hong Kong, Shatin, Hong Kong

ABSTRACT

Objectives: To determine the role of whole-body fluorodeoxyglucose positron emission tomography–computed tomography (FDG PET-CT) in the diagnosis and work-up of suspected or confirmed brain metastasis and to assess its impact on clinical management and outcomes.

Methods: This was a retrospective study of patients who were suspected or confirmed to have brain metastases and had subsequent whole-body PET-CT at a local centre between 2008 and 2011. The PET-CT results were then compared with the biopsy results which were regarded as the gold standard. The clinical management and survival rate were also evaluated.

Results: In all, 58 consecutive patients with suspected or confirmed brain metastasis who underwent whole-body PET-CT were assessed. Among these, 23 patients suffered from multiple brain lesions and in the remainder it was solitary. Eight (group A) of these 58 patients had a biopsy- or resection-confirmed metastatic brain lesion (primary not proven) prior to the PET-CT scan. While the rest (group B, n = 50) had a clinically suspected brain metastasis without histological confirmation prior to the PET-CT. All patients in group A had a solitary brain lesion. Resection or biopsy of the brain lesion prior to the scan and subsequent histology confirmed its metastatic origin. The site of the extracranial primary malignancy was identified in all these patients by PET-CT. Half of them (4/8) later had biopsies of the PET-CT–suspected extracranial primary malignancies, which were all concordant with the brain biopsy results. In group B, 19 PET-CT scans revealed no suspicious uptake extracranially, so the brain lesions were presumed to be primarily of brain origin (termed group B1). Moreover, all of them were also confirmed by subsequent biopsy. Among the remaining 31 patients (termed group B2), 21 were found to have a suspected extracranial primary malignancy based on PET-CT scans that were confirmed by subsequent biopsy (18 non-small-cell lung carcinoma, 1 colonic carcinoma, 1 breast carcinoma, and 1 thymic carcinoma). For brain lesions of patients in whom the PET-CT scan suggested a metastatic origin (groups A + B2), 70% and 49% received whole-brain radiotherapy and chemotherapy, respectively. On the other hand, patients with primary brain lesions (group B1) underwent resection (74%), radiotherapy (68%), and chemotherapy (53%). The survival of the three groups differed significantly ($p < 0.001$). Group B1 showed the best survival followed by group B2 and then group A.

Conclusion: Whole-body 18F-FDG PET-CT is useful for determining whether a brain lesion is primary or metastatic in nature. It is suggested that group A patients may benefit from PET-CT scan via identification of an extracranial primary malignancy. This helps further planning of the treatment to avoid unnecessary resection or biopsy of the metastatic lesion which may not show additional survival benefit and could even result in complications.

Key Words: Brain neoplasms; Fluorodeoxyglucose F18; Neoplasms, unknown primary; Tomography, emission-computed

Correspondence: Dr Ryan KL Lee, Department of Imaging and Interventional Radiology, Prince of Wales Hospital, Shatin, Hong Kong.

Tel: (852) 2632 1247; Email: leekalok2909@yahoo.com.hk

Submitted: 22 Mar 2012; Accepted: 26 Apr 2012.

中文摘要

全身氟脫氧葡萄糖正電子發射斷層成像和CT掃描 (FDG PET-CT) 在疑似或確診腦轉移瘤病例中的角色

李嘉樂、王琪、伍永鴻、葉梓斌、林淑儀、袁學遠、張智欣、李艷萍、陳達明

目的：探討全身FDG PET-CT在診斷及檢查疑似或確診腦轉移瘤的病人中角色，以及評估這技術對於臨床處理及結果的影響。

方法：回顧2008至2011年期間在本地的一所PET-CT中心疑似或確診腦轉移瘤並接受FDG PET-CT檢查的病人。比較他們的PET-CT結果和認為是金標準的活檢結果，並評估病人的臨床處理及存活率。

結果：共58名疑似或確診腦轉移瘤並接受FDG PET-CT檢查的病人被列入研究範圍。其中23例有多發性腦腫瘤，其餘為獨立性腦腫瘤。把病人分為兩組。A組有8例，他們在進行PET-CT檢查前已從活檢或切除組織中確診為腦轉移瘤，但未能確定其原發灶位置。B組的50例在進行PET-CT檢查前臨床懷疑患有腦轉移瘤，但未得到組織學的確證。A組的所有病人均為獨立性腦腫瘤，他們在PET-CT檢查前已從活檢或切除組織以及其後的組織學確證了腦轉移瘤的原發灶位置。他們的PET-CT檢查顯示顱外原發灶的位置。A組中有4例後來在PET-CT檢查確證的顱外原發灶的位置進行活檢，結果與腦轉移瘤的活檢組織吻合。B組中有19例的PET-CT結果未發現有顱外瘤，所以認為其腦腫瘤為原發灶 (B1組)，全部其後從活檢確證。B組其餘的31例 (B2組) 中，21例的PET-CT結果發現疑似顱外原發惡性瘤，後被活檢確證，它們為18例非小細胞肺癌，另結腸癌、乳腺癌及胸腺癌各1例。所有PET-CT發現有腦轉移瘤的病人中 (A組+ B2組)，70%接受全腦放療，49%接受化療。此外，有原發性腦腫瘤的病人中 (B1組)，74%接受切除手術、68%接受放療、53%接受化療。三組病人的存活率有明顯分別：B1組有最佳的存活率，其次為B2組及A組。

結論：全身FDG PET-CT能分辨腦腫瘤的原發性還是轉移性。本研究中A組病人因接受PET-CT檢查而得知顱外原發灶的位置，從而可以進一步計劃治療方案，避免進行不必要的切除或活檢，因為在這種轉移瘤情況下無論是切除或活檢均可能導致並發症，但未必能延長病人的存活期。

INTRODUCTION

Positron emission tomography is used to evaluate patients with a variety of malignancies. Positron emission tomography-computed tomography (PET-CT) can stage the disease and identify the site of a metastasis that is not detected by conventional imaging. One of the earliest applications of fluorodeoxyglucose (FDG) PET-CT was in the evaluation of brain malignancies. Brain metastases comprise about half of all brain tumours and occur in 20 to 40% of systemic cancers.¹ The chance of encountering such metastases has been increasing due to increased longevity of cancer patients and the overall increase in the incidence of cancers.¹ PET-CT is useful for early detection of primary cancers in the presence of brain and other systemic metastases as well as for tumour staging of patients suspected to be suffering from or differentiated from such cancers.² Detection of the

primary malignancy after a brain metastasis is important in deciding appropriate treatment. It is also an important means of differentiating between primary and metastatic brain tumours, as there is significant difference in survival between these two brain tumour types.

Thus, the aim of this study was to determine the role of whole-body FDG PET-CT in the diagnosis and work-up of suspected or confirmed brain metastasis, and to assess its subsequent impact on clinical management and outcomes.

METHODS

Patient Population

This was a retrospective study performed in a local PET-CT centre. At our institution, there is a database

of all patients examined with FDG PET-CT. Records in this database from January 2008 to December 2011 were reviewed to identify patients with suspected or confirmed brain metastases who underwent 18F-FDG whole-body PET-CT as an investigation for extracranial primary malignancy. Records of 58 consecutive patients were retrieved. All patients had CT brain imaging and 71% (41/58 patients) had brain magnetic resonance imaging (MRIs) performed before their PET-CT. The mean age of these 58 patients (38 men, 20 women) was 60 (range, 30-81) years. Among these, 23 patients suffered from multiple brain lesions and the remainder had solitary brain lesions.

18F-fluorodeoxyglucose Whole-body Positron Emission Tomography–Computed Tomography

All patients were scanned on a Gemini GXL PET/CT scanner (Philips medical system) after receiving 10 mCi (740 MBq) of 18FDG intravenously. Patients fasted for six hours and then had their blood glucose checked before FDG injection. 18FDG was injected only if the haemostix gave a reading of <11 mmol/l. The patient stayed inside an isolated room with dim light for 45 to 60 minutes during the uptake phase before scanning. The patients were scanned from vertex to below knee, as a brain scan was routinely obtained in patients undergoing whole-body staging of malignancy at our institution. PET acquisition was usually covered by 15

beds of scanning. Each bed covered a length of 180 mm and was counted in 90-second segments. PET images were reconstructed into 4-mm section thicknesses in a 256 x 256 matrix. The transaxial images were realigned to yield sagittal and coronal images. Low-dose CT for attenuation correction was performed using a Philips 16-slice MDCT (30 mA, 140 kV). The raw data from the FDG PET images and low-dose CT were loaded onto a workstation (Philips Medical systems) and displayed with multiplanar reconstruction. No patient felt discomfort during the whole-body 18F-FDG PET procedure and there were no complications.

Patient Grouping

The 58 patients were divided into two groups. Group A (8 patients) all had proven metastatic brain lesion(s) either by biopsy or resection prior to PET-CT scanning. Group B (50 patients) all had suspected brain metastasis based on CT or MRI findings but without histological confirmation prior to PET-CT (Figure 1). Among group A patients with a confirmed histological diagnosis of the brain lesion before PET (Figure 2), seven were proven to be metastatic adenocarcinomas (6 with suspected lung primaries and 1 with suspected gastrointestinal tract primary). The remaining single brain lesion was proven to be a metastatic squamous cell carcinoma (origin unknown). Group B patients were further divided into B1 (n = 19, Figure 3) and B2 (n = 31, Figure 4) based on FDG PET-CT results. In group B1, all the patients

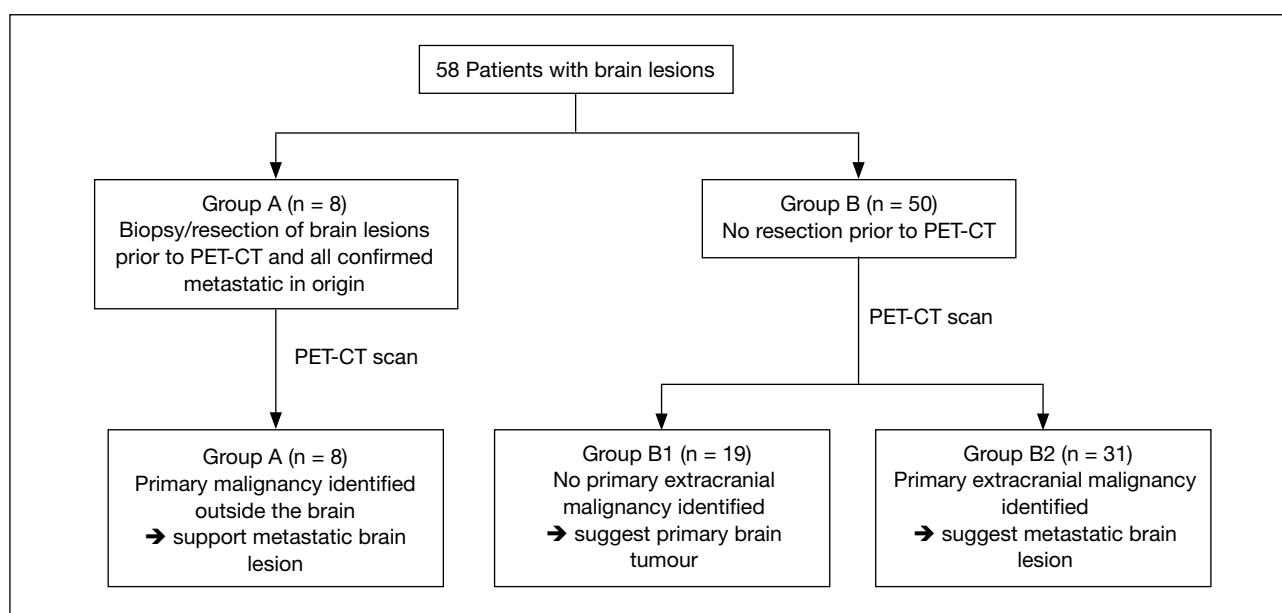


Figure 1. Patients are divided into two main groups in this study.

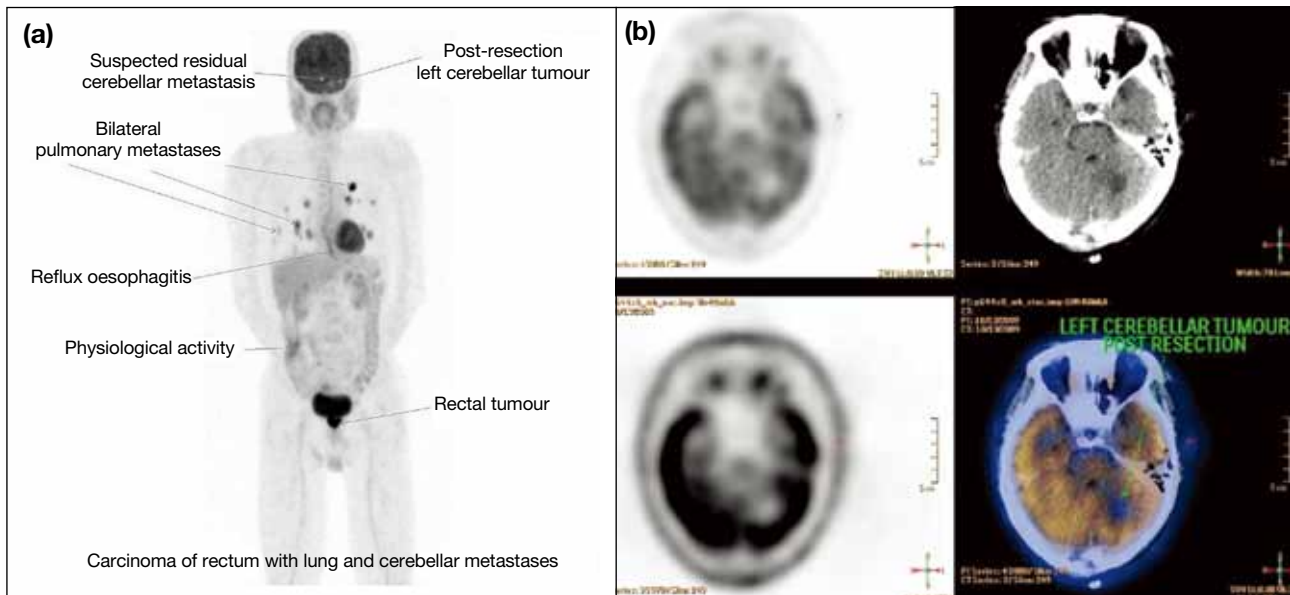


Figure 2. This patient in group A presented with a solitary left cerebellar lesion which was then resected and proven to be metastatic. (a) Subsequently, the PET scan demonstrated a primary rectal carcinoma confirmed by colonoscopy and biopsy. (b) The corresponding axial PET-CT shows area of absent FDG uptake in the left cerebellar resection site.

showed no extracranial abnormal FDG uptake in the PET-CT study and thus the brain lesions were assumed to be primary in origin. In group B2, patients showed suspicious extracranial FDG uptake, so the brain lesions were regarded as metastatic in origin.

The above FDG PET-CT results were then compared with the biopsy results, which were regarded as the gold standard. The biopsies targeted either the brain lesion or the suspicious extracranial primary malignancy shown up by PET-CT. The clinical data including subsequent clinical management and survival rate were retrieved from the electronic patient database.

Statistical analysis

SPSS was used for statistical analysis. The survival was plotted as a Kaplan-Meier survival curve. A p value of <0.05 was taken as statistically significant.

RESULTS

Fluorodeoxyglucose Positron Emission Tomography–Computed Tomography Results

The FDG PET-CTs were able to identify all the primary extracranial malignancies among patients in group A. The suspicious extracranial primary tumour included six lung carcinomas, one rectal carcinoma, and one

nasopharyngeal carcinoma. The metabolic activity of the lesions ranged from hypometabolic (25%) that was defined as having a lower standardised uptake value (SUVmax) than the contralateral side of the brain parenchyma, to hypermetabolic (75%) which was defined as having a higher SUVmax than brain grey matter. The mean SUVmax value of the brain lesions in group A was 9.3. In group B1, all patients showed no suspicious FDG PET-CT uptake outside the brain. All the brain lesions were thus regarded as primary tumour. The metabolic activity of the lesions ranged from hypometabolic (26%) to hypermetabolic (74%). The mean SUVmax value of the brain lesions was 6.4. In group B2, FDG-PET revealed 26 patients with suspected lung carcinoma, two with colorectal carcinoma, two with breast carcinoma, and one with thymic carcinoma. The metabolic activity of the lesions ranged from hypometabolic (29%) to hypermetabolic (71%). The mean SUVmax value of the brain lesions was 10.4.

Pathological and Clinical Correlation

Four patients (4/8, 50%) in group A had subsequent biopsies of suspicious extracranial primary malignancies shown up by PET-CT. All four biopsies showed concordant results with the FDG PET-CT results (3 lung and 1 colorectal carcinoma). The remaining four patients in group A had clinical and radiological features compatible with lung carcinoma and thus

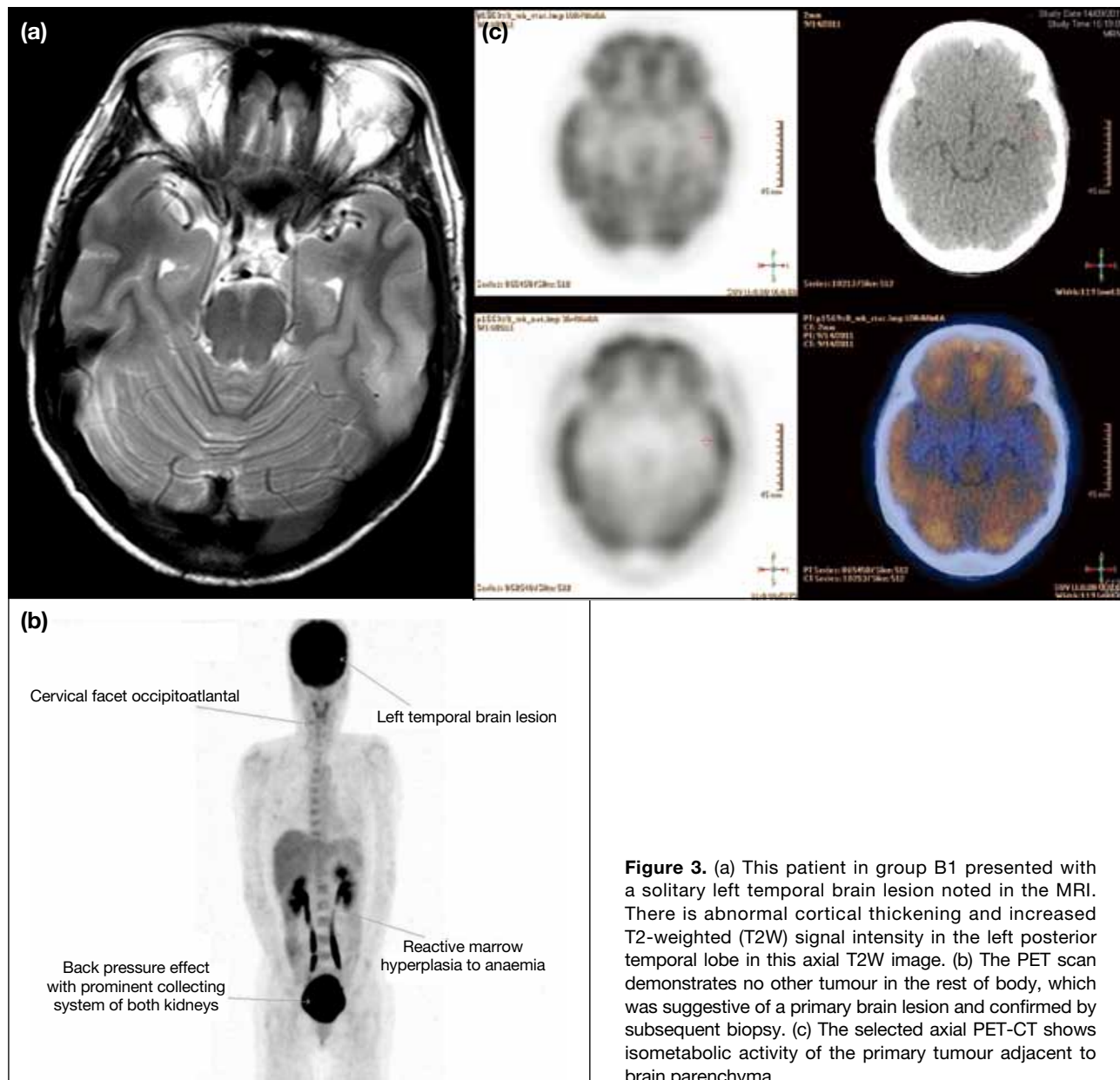


Figure 3. (a) This patient in group B1 presented with a solitary left temporal brain lesion noted in the MRI. There is abnormal cortical thickening and increased T2-weighted (T2W) signal intensity in the left posterior temporal lobe in this axial T2W image. (b) The PET scan demonstrates no other tumour in the rest of body, which was suggestive of a primary brain lesion and confirmed by subsequent biopsy. (c) The selected axial PET-CT shows isometabolic activity of the primary tumour adjacent to brain parenchyma.

further biopsies were not performed due to their poor condition.

All 19 group B1 patients underwent biopsy or resection of their brain lesions, which were confirmed to be primary in origin. Among these, there were: six high-grade gliomas, i.e. glioblastoma multiforme (World Health Organization [WHO] grade 4); four low-grade astrocytomas (WHO grade 2); three meningiomas (2 atypical, WHO grade 2; and 1 typical); two each of primary central nervous system lymphomas, haematomas, and inflammatory lesions.

Among the 31 group B2 patients, 21 had subsequent biopsies and again all the results were concordant with the FDG PET-CT results (18 non-small-cell lung carcinomas, 1 colonic carcinoma, 1 breast carcinoma, and 1 thymic carcinoma). The remaining 10 patients (8 with suspected lung carcinoma, 1 with breast carcinoma, and 1 with colon carcinoma) were not biopsied due to the poor condition of the patients. However, the clinical and other radiological findings also supported the PET-CT diagnosis.

Overall, 44 (76%) of the 58 cases had a biopsy or

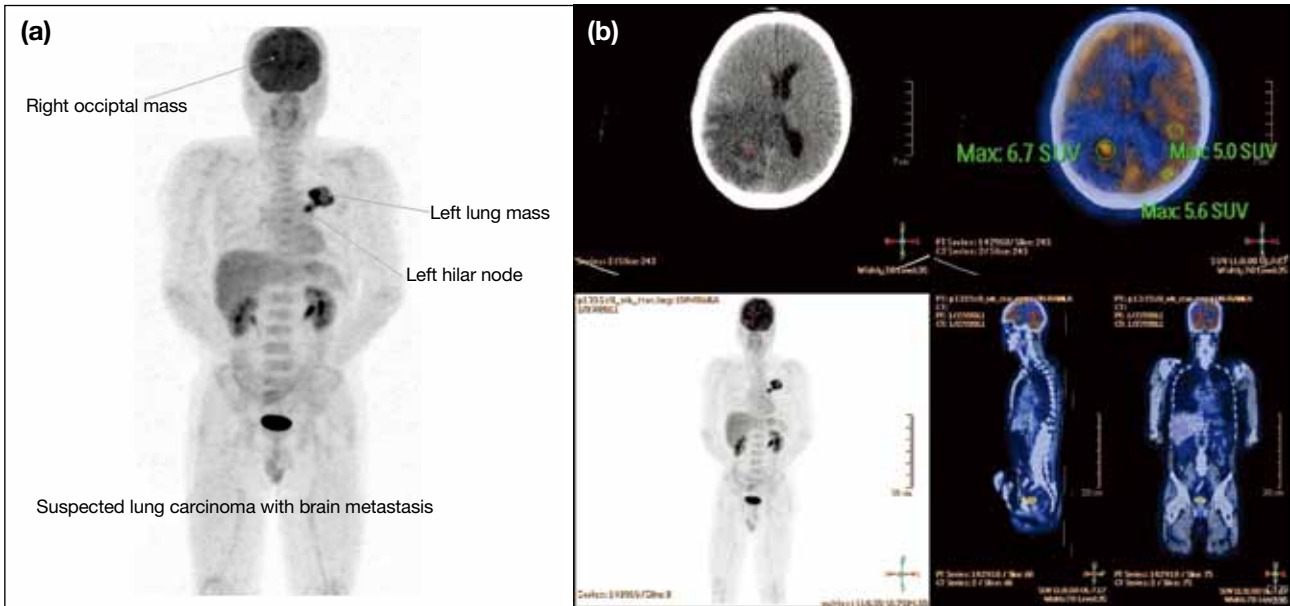


Figure 4. This patient in group B2 presented with a solitary right occipital brain lesion noted in brain CT and MRI images. (a) The PET scan demonstrates a suspicious left peri-hilar lung carcinoma, which was confirmed by subsequent biopsy. (b) The right occipital brain lesion is slightly hypermetabolic compared to the normal left cerebral parenchyma.

resection of the brain lesion. The pathology and PET-CT results showed 100% concordance among these biopsied patients.

Clinical Management and Outcome

Of the 39 patients with brain lesions suspected of being metastatic based on FDG PET-CT (groups A + B2 patients), 70% and 49% received whole-brain radiotherapy and chemotherapy, respectively. The 19 patients with a primary brain lesion (group B1) were treated by resection (74%), radiotherapy (68%), and chemotherapy (53%).

The Kaplan-Meier survival curves of the three groups are shown in Figure 5, indicating significantly different survival rates ($p < 0.001$). Pairwise comparisons between the groups also showed significant differences (between group A and B1, $p < 0.001$; between group A and B2, $p = 0.003$; between group B1 and B2, $p = 0.04$). Group B1 patients showed the best survival followed by those in group B2 and in group A.

Apparently Normal Chest Radiography in Lung Carcinoma

There were 32 suspected lung carcinomas based on FDG PET-CT findings (6 patients from group A and 26 patients from group B2). In eight (25%) of these patients, before the PET-CT, the corresponding chest

X-rays were interpreted as normal by clinicians. The mean size of these eight lung carcinomas was 1.3 cm (range, 1.0-1.8 cm) measured based on low-dose CT

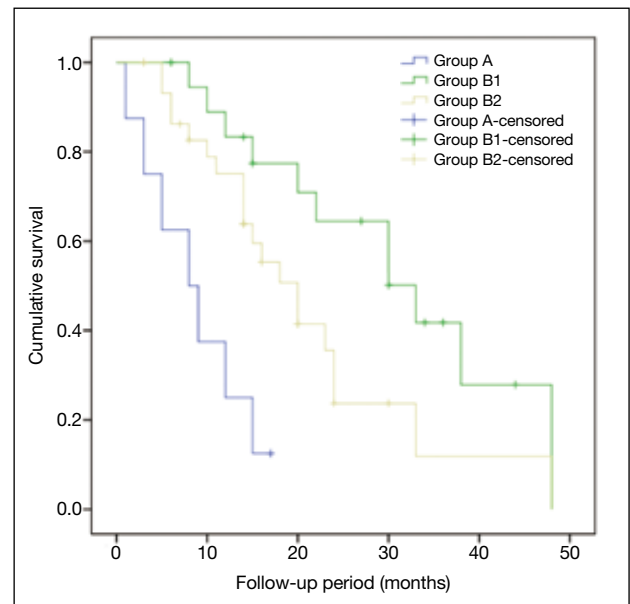


Figure 5. The Kaplan-Meier survival curves of groups A, B1, and B2 patients, showing that they differed significantly ($p < 0.001$). The pairwise comparisons between any two groups also yielded significant differences (between group A and B1, $p < 0.001$; between group A and B2, $p = 0.003$; between group B1 and B2, $p = 0.04$).

performed during the PET-CT. Half of them were retrocardiac and the rest were located at the hilar regions. All 21 histologically proven lung lesions were non-small-cell carcinomas (18 adenocarcinomas and 3 squamous cell carcinomas).

DISCUSSION

Common tumours that metastasise to brain include lung, breast, colorectal, and melanoma.¹ In about 16 to 35% of such patients, the site of the primary is unknown.¹ Studies revealed that 18F-FDG PET-CT is useful for detecting the unknown primary tumour in a variety of metastatic cancers. Especially for brain metastasis, PET-CT can localise the primary lesion in about 82% of cases.¹ In our series, PET-CT identified the extracranial primary lesion in all patients confirmed or suspected to have a brain metastasis (groups A and B2).

There is always uncertainty with metastatic or primary brain tumours, but FDG PET-CT has been shown useful in differentiating metastatic from primary brain tumours by identifying extracranial primary tumours. Our results also support this proposition, in that brain lesions assumed to be primary based on PET-CT (group B1) were all subsequently confirmed to be accurate by histology. Based on this study, PET-CT can help differentiate whether the lesion is primary or secondary and help in selecting the most suitable further investigation for evaluation of the primary origin of the brain metastasis or primary brain tumour.³ PET-CT is also proven to be useful in the initial assessment and clinical grading of gliomas including the prognostic analysis of those that are malignant,³ although this aspect was not evaluated in our study.

In group A, all the patients had resection or biopsy of the brain lesion before the PET-CT scan and were confirmed to have metastatic tumours. However, the resection or biopsy of the brain lesions is not only invasive, but can also result in complications. Resection of a brain metastasis is not necessarily associated with a better prognosis, as to a large extent management of the brain metastasis depends on the staging of the primary tumour, the patient's general condition, and neurological status.⁴ It is therefore advised that for patients in whom there is any doubt about whether the brain lesion is primary or secondary should have PET-CT before any invasive brain surgery.

Normal brain parenchyma depends on glucose as its primary energy source, and so normal brain

cortex shows high FDG uptake, which may make the identification of the brain tumour difficult and challenging. Primary and metastatic brain tumours show variable metabolic activity and could be hyper-, iso-, or hypo-metabolic. In our series, the proportion of hypometabolic to hypermetabolic brain metastases was about 1:3, and was similar to what has been reported previously.⁵ Isometabolic activity makes the identification of brain lesions difficult. This may explain why PET-CT scans miss some brain metastases.⁵

As many patients with brain metastases have advanced systemic cancer and limited life expectancy, the aim of the treatment is mainly short-term, and includes whole-brain radiotherapy or use of corticosteroids.³ The majority of our patients showed advanced stage disease at the time of their PET-CT scan, so the main treatment was palliative chemotherapy and radiotherapy. Resection of the brain lesion was thus not performed even if the patient had only a solitary brain metastasis.

According to the literature, the median survival of glioblastoma and anaplastic brain tumours are around one year and two to three years, respectively.⁶ In the presence of a low-grade glioma, 80% of the patients attain 20-year survivals. The median survival for cerebral metastases remains less than one year, which is worse than that for primary brain tumours. Our results also show a similar pattern, in that patients with primary brain tumours had significantly better survival than those with metastatic brain lesions. In our series moreover, survival was significantly better for those not undergoing resection or biopsy of the metastatic brain lesion prior to the PET-CT (group B2 patients) than those who did (group A patients). Indeed, it seems that such invasive procedures / surgery may not prolong survival and may even shorten the life expectancy. This provides further support for performing PET-CT prior to brain resection or biopsy for patients in whom there is any doubt regarding a possible extracranial malignancy.

Although conventional work-up can still identify the primary origin, it is more time-consuming and slower than PET-CT. The primary origin of some brain metastases cannot be identified after conventional investigations but may be rapidly located by PET-CT, especially if they are metabolically active.¹ In addition, PET-CT can identify nodal involvement and extent of metastases to other regions to make therapeutic decision.¹ In our series of patients with lung cancers, in about 25% their chest X-rays were interpreted as normal

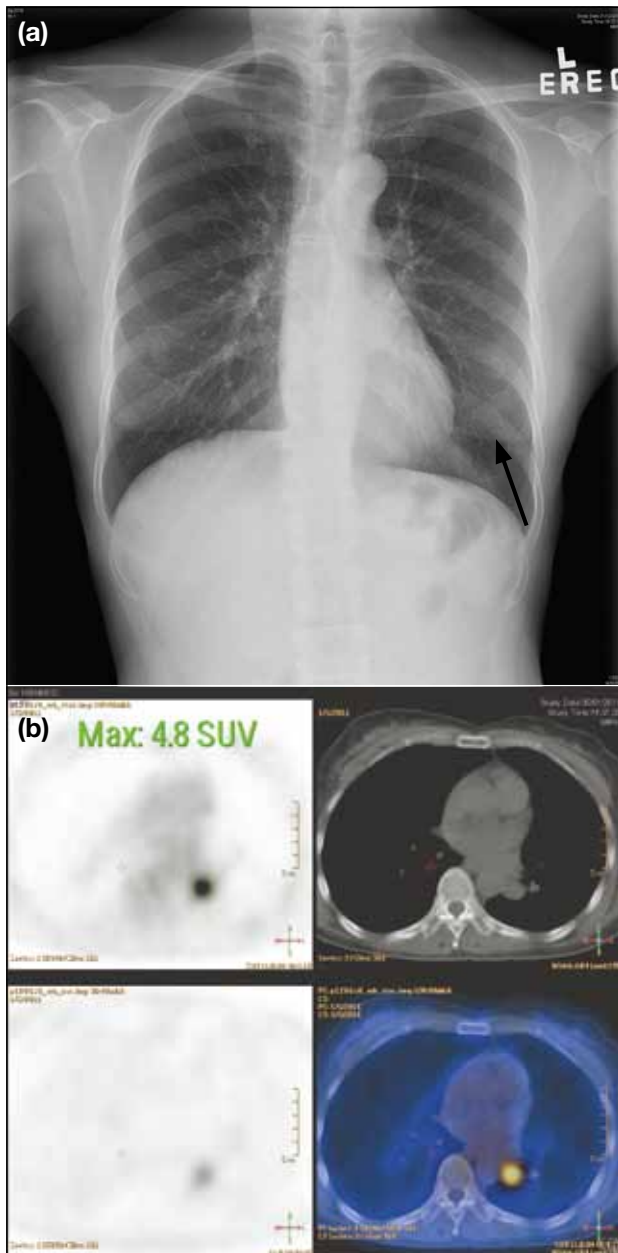


Figure 6. Example of a subtle lung carcinoma; chest radiography was interpreted as normal by clinicians before the PET. (a) Chest radiography actually shows a subtle retrocardiac lesion which was missed (arrow). (b) The corresponding PET can identify the lesion clearly and shows high metabolic activity.

before PET-CT, because of the small size of the primary and / or its retrocardiac / hilar location. Their small size and the fact that they were obscured by cardiac or hilar shadows may have contributed to the apparently normal chest radiography appearance (Figure 6). Such tumours could be identified by the FDG PET-CT, however. This observation also emphasises the importance of whole-body FDG PET-CT rather than the conventional work-

up for patients suspected or confirmed to have brain metastases.

The main drawback of PET-CT is that both physiological uptake and inflammation can increase uptake and mimic an extracranial primary and be misinterpreted as a primary tumour, thus resulting in a false-positive result.⁷ A delayed scan is said to be helpful in resolving physiological from pathological uptakes, since the latter tends to persist or even increase.⁶

The main limitation of this study was its retrospective design. Moreover, not all patients with suspected brain metastases and an extracranial primary malignancy had histological confirmation of the brain lesion. The non-biopsied cases in our series nevertheless showed 100% concordance with PET-CT results based on clinical and other radiological data, as well as subsequent follow-up.

CONCLUSION

Whole-body ¹⁸F-FDG PET-CT is an accurate, useful, and reliable initial test for work-up of patients with confirmed or suspected intracranial metastases. It is useful for differentiating primary from secondary brain lesions and the detection / localisation of the primary focus when there is a brain metastasis, and attains a high degree of histological concordance. It is also a recommended investigation before proceeding to an invasive procedure / surgery, if there is any doubt about the origin of a brain lesion.¹

REFERENCES

1. Jeong HJ, Chung JK, Kim YK, Kim CY, Kim DG, Jeong JM, et al. Usefulness of whole-body (18)F-FDG PET in patients with suspected metastatic brain tumors. *J Nucl Med.* 2002;43:1432-7.
2. Rohren EM, Provenzale JM, Barboriak DP, Coleman RE. Screening for cerebral metastases with FDG PET in patients undergoing whole-body staging of non-central nervous system malignancy. *Radiology.* 2003;226:181-7.
3. Griffith LK, Rich KM, Dehdashti F, Simpson JR, Fusselman MJ, McGuire AH, et al. Brain metastases from non-central nervous system tumors: evaluation with PET. *Radiology.* 1993;186:37-44.
4. Kim DG, Kim CY, Paek SH, Lee DS, Chung JK, Jung HW, et al. Whole-body [¹⁸F]FDG PET in the management of metastatic brain tumours. *Acta Neurochir (Wien).* 1998;140:665-73; discussion 673-4.
5. Lee HY, Chung JK, Jeong JM, Lee DS, Kim DG, Jung HW, et al. Comparison of FDG-PET findings of brain metastasis from non-small-cell lung cancer and small-cell lung cancer. *Ann Nucl Med.* 2008;22:281-6.
6. Chen W. Clinical applications of PET in brain tumors. *J Nucl Med.* 2007;48:1468-81.
7. Olivero WC, Dulebohn SC, Lister JR. The use of PET in evaluating patients with primary brain tumours: is it useful? *J Neurol Neurosurg Psychiatry.* 1995;58:250-2.