
CASE REPORT

Late Isolated Regional Lymph Node Recurrence of Dermatofibrosarcoma Protuberans of the Abdominal Wall

YK Chik, AKC Leung, KC Ngan

Department of Clinical Oncology, Queen Elizabeth Hospital, 30 Gascoigne Road, Kowloon, Hong Kong

ABSTRACT

This report is of a rare occurrence of lymph node relapse in a 46-year-old Chinese man with dermatofibrosarcoma protuberans of the abdominal wall. At initial presentation, the patient underwent wide local excision of the primary lesion. He developed local recurrences twice, at 11 months and 2 years after diagnosis, both of which were treated with wide local excision. Adjuvant radiotherapy was given to the abdominal wall after his second relapse. Subsequently he developed right groin lymph node metastasis 17 years after the initial presentation. There was no evidence of other sites of metastasis on positron emission tomography / computed tomography scan. He underwent right groin lymph node dissection followed by postoperative radiotherapy because of the presence of extracapsular extension of the nodal metastasis. He was disease-free at the last follow-up visit two months after completion of radiotherapy. Literature review for the incidence, characteristics, treatment, and outcome of lymph node relapse showed less than 20 reported cases of dermatofibrosarcoma protuberans with lymph node metastasis. Patients with repeated local recurrences were found to be at higher risk for lymph node metastasis. The prognosis for lymph node metastasis was poor for patients with concomitant distant metastasis or those in whom radical lymph node dissection was not feasible, with most patients dying of metastatic disease within 2 years. This case illustrates that the clinical course of dermatofibrosarcoma protuberans could be long, and it is important to examine the regional lymphatic system in addition to the primary site during follow-up, especially for patients with repeated local recurrences. When there is no distant metastasis, the treatment of choice for lymph node metastasis is radical lymph node dissection. Close surveillance for subsequent distant metastasis after the regional treatment is warranted.

Key Words: Dermatofibrosarcoma protuberans; Lymph nodes; Lymphatic metastasis

中文摘要

腹壁隆突性皮膚纖維肉瘤的晚期孤立性局部淋巴結復發

戚彥君、梁國璋、顏繼昌

本文報告一名46歲華籍男性，其腹壁隆突性皮膚纖維肉瘤出現罕見的淋巴結復發。首發時患者接受廣泛局部切除原發病灶。術後第十一個月及兩年後分別有局部復發，兩次均施以廣泛局部切除。第二次復發後，病人同時接受了腹壁輔助放療。病人首發十七年後出現右腹股溝淋巴結轉移。正子攝影及電腦斷層攝影均顯示未有其他部位的轉移。由於病人有淋巴腺包膜外侵犯，遂進行右腹股溝淋

Correspondence: Dr YK Chik, Department of Clinical Oncology, Queen Elizabeth Hospital, 30 Gascoigne Road, Kowloon, Hong Kong.

Tel : (852) 2958 8888; Email : cyk632@ha.org.hk

Submitted: 19 Sep 2011; Accepted: 22 Dec 2011.

巴結切除及術後放療。放療後兩個月的跟進顯示病人未有復發。記載有關淋巴結復發的病發率、特性、治療及結果的文獻中，只有20宗關於隆突性皮膚纖維肉瘤併發淋巴結復發的病例。有重復原位性復發的病人，其淋巴結轉移的風險會增加。有遠處轉移或未能接受根治性淋巴結切除的病人，其淋巴結轉移的預後會很差。大部分的病人都因轉移灶而於兩年內死亡。本病例顯示隆突性皮膚纖維肉瘤的臨床過程可以相當長，所以跟進期內檢查病人的原發及區域淋巴系統非常重要，尤其對於有多次原位復發的病人。如果沒有遠處轉移，淋巴結轉移的治療方法為根治性淋巴結切除。術後要密切監察病人是否有遠處轉移。

INTRODUCTION

Dermatofibrosarcoma protuberans (DFSP) is an uncommon locally aggressive dermal and subcutaneous neoplasm. The estimated overall incidence is 0.5 to 0.8 cases per million per year.^{1,2} The incidence in the Asian population has not been well studied. DFSP has a high rate of local recurrence after local excision, but an extremely low rate of metastasis. The tumour is commonly located on the trunk and proximal extremities of young and middle-aged adults, usually presenting in the third or fourth decade of life.³ The overall recurrence rate is 50%.⁴ Haematogenous spread is very rare and lymphatic involvement is even rarer.^{4,5} The reported incidence of metastasis is 5%, three-quarters of which is haematogenous, and one-quarter is lymphatic.⁶ Lung is the most common site of metastasis.^{4,6}

CASE REPORT

A 46-year-old Chinese man with good past health presented in October 1994 at the age of 29 years with a right lower abdominal wall nodule for the previous two years. The nodule measured 3.0 x 2.0 x 1.5 cm. Excision of the nodule showed DFSP of the subcutaneous fat with clear resection margins. The

patient subsequently had local relapse of the abdominal wall mass in September 1995, for which wide local excision was done. Pathological examination showed an 8-mm tumour with clear resection margins.

The patient presented with a second local relapse over the scar in March 1996 and underwent excision with 2-cm margins. Histopathological examination revealed a DFSP at 1.2 cm in the deep subcutis, with frequent mitosis of 15-20 per high power field. For better locoregional control, adjuvant radiotherapy was given using a 10-MeV electron beam delivering a daily fraction of 2 Gy at a depth of 2 cm, five fractions per week, up to a total 60 Gy, with a 1-cm supraflap covering the scar. Radiotherapy was completed in June 1996.

In February 2011, approximately 15 years after the radiotherapy, the patient presented with a 4-cm hard groin mass. Positron emission tomography / computed tomography showed a 1.8 x 2.3 x 2.6-cm right groin lymph node (maximum standardised uptake value [SUVmax], 6.9) and right lower abdominal wall uptake (SUVmax, 4.4) [Figure 1]. Magnetic resonance

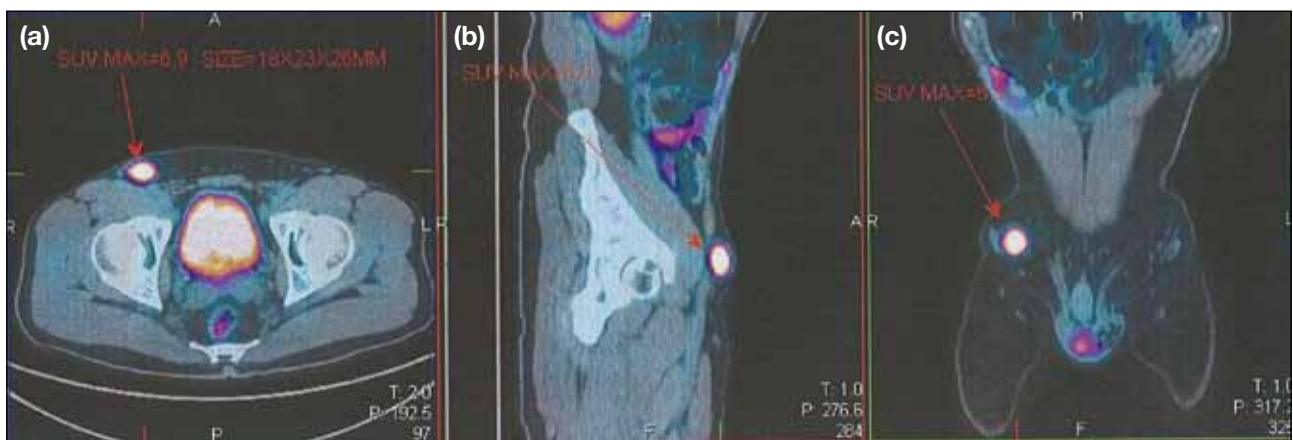

Figure 1. (a) Axial, (b) sagittal, and (c) coronal positron emission tomography / computed tomography fusion images showing a 1.8 x 2.3 x 2.6-cm hypermetabolic lymph node in the right groin. Maximum standardised uptake value = 6.9.

imaging of the abdominal wall showed ill-defined T2-weighted hyperintense signal in the deep subcutaneous region over the right abdominal wall. The images were reviewed, and the abdominal wall signals were considered to be post-treatment fibrosis. Right groin lymph node dissection was performed in February 2011. Pathological examination showed metastatic DFSP involving one of six lymph nodes with the presence of extracapsular extension (Figures 2-4). Postoperative radiotherapy to the right groin was given because of the extracapsular extension, using a 16-MeV electron beam to deliver 2.5 Gy per fraction up to 47.5 Gy. The patient remained disease-free at the last follow-up four months after completing radiotherapy. He will be regularly followed up to monitor for disease recurrence.

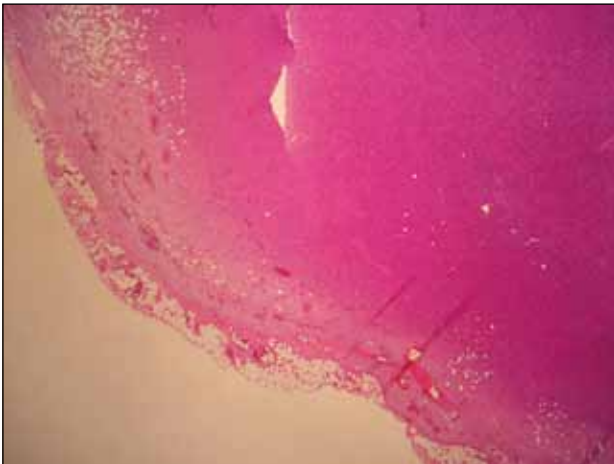


Figure 2. Dermatofibrosarcoma protuberans infiltrating a lymph node with extranodal fat invasion (x 20, H&E stain).

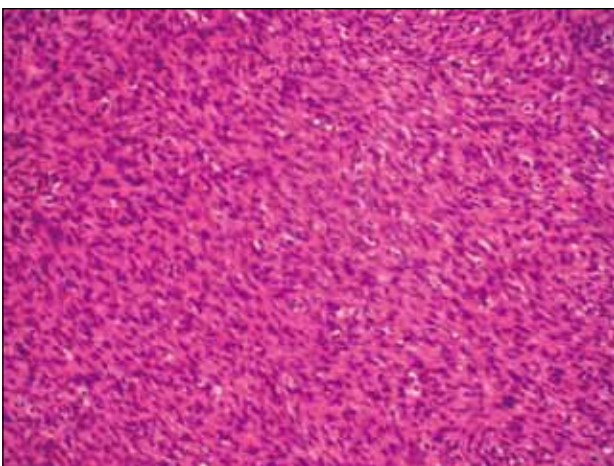


Figure 3. High-power view showing tumour cells arranged in haphazard fascicles (x 400, H&E stain).

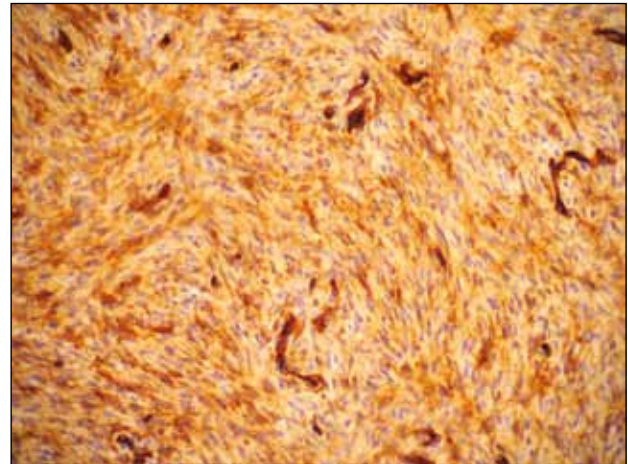


Figure 4. Tumour cells showing strong staining for CD34 (x 400, CD34 immunostain).

DISCUSSION

DFSP arises from the rearrangement of chromosomes 17 and 22 with fusion between the collagen type 1 α 1 gene (COL1A1) and platelet-derived growth factor (PDGF) β -chain expression and uncontrolled receptor activation and cell growth. This rearrangement results in the deregulation of PDGF β -chain expression and leads to continuous activation of the PDGF receptor β (Pdgfr β) protein tyrosine kinase, which promotes DFSP cell growth.^{3,7}

Lymphatic metastasis is extremely rare. Rutgers et al⁴ performed an extensive literature review of 913 patients with DFSP, of whom only 11 were found to have lymph node metastasis. From local data from the Queen Elizabeth Hospital, Hong Kong, of 36 patients with DFSP diagnosed from 1994 to 2007, one had lymph node, lung, brain, and bone metastases.⁸ Together with other reported patients,⁹⁻¹⁸ a total of 20 patients with DFSP with lymph node metastasis have been identified in the literature. To the authors' knowledge, this patient is the first Chinese patient to have isolated lymph node metastasis.

The clinical features of the other 20 patients with lymph node metastasis are shown in the Table.^{5,8-22} Analysis is limited by the small number of patients, but several observations can still be made. Lymphatic metastasis can present at any age, ranging from 17 to 82 years. The primary site for lymphatic metastasis tends to be the extremities, which is a less common primary site of DFSP than the trunk.

Table. Reports of patients with lymph node metastasis from dermatofibrosarcoma protuberans (n = 20).^{5,8-22}

Authors	Age (years)	Sex	Site of primary	Size of primary (cm)	No. of recurrences	Time from diagnosis to lymph node metastasis	Histo-logically proven	Distant metastasis	Therapy	Follow-up
Gentile, 1951 ²⁰	42	NR	Arm	NR	1	NR	No	NR	RT	9 months DOD
	82	NR	Thigh	NR	3	NR	No	NR	RT	1 months DOD
	52	NR	Chin	NR	1	NR	Yes	NR	RT / CT	2 months DOD
Wooldrige, 1957 ¹⁷	60	F	Knee	5	2	16 months	Yes	Yes* (lung, cervical lymph node)	Excision	31 months DOD
Przybora and Wojnerowicz, 1959 ¹⁹	29	M	Neck	NR	3	NR	Yes	NR	ND	13 months NED
	60	M	Arm	NR	2	NR	Yes	NR	Exarticulation	2 years DOD
Fisher and Hellstrom 1966 ¹⁶	52	M	Chin	5 x 5	1	1.5 years	Yes	Yes† (cervical, suprasternal, anterior thorax)	RT / CT	6 months DOD
Brenner et al 1975 ⁹	25	M	Foot	NR	2	5 years	Yes	No	ND	1 year NED
Kahn et al 1978 ²²	27	NR	Shoulder	NR	1	-	Yes	-	Excision	8 years DOD
Hausner et al, 1978 ¹²	40	M	Neck	0.5	0	4 months	Yes	No	ND	22 months NED
Volpe and Carbone 1983 ¹³	29	F	Scapula	NR	2	8 years	Yes	Yes* (cervical node, bone, lung)	ND + CT	5 months DOD
Petoin et al, 1985 ¹⁴	NR	NR	Shoulder	NR	NR	NR	Yes	NR	NR	NR
Waldermann and Hagedorn 1985 ²¹	NR	NR	Arm	NR	2	NR	NR	NR	RT	2 years DOD
Hirabayashi et al, 1989 ¹⁵	21	M	Scalp	NR	3	7 years	Yes	No	WLE + ND	8 months NED
Mavili et al, 1994 ⁵	53	M	Pretibial	3 x 1.5	0	10 months	Yes	No	ND	18 months NED
Lal et al, 1999 ¹⁸	NR	NR	Lower limb	NR	NR	NR	NR	NR	NR	NR
Lal et al, 2004 ¹⁰	17	M	Scalp	8 x 6 x 4	1	NR	Yes	No	WLE + ND	18 months NED
Cai et al, 2004 ¹¹	NR	NR	NR	NR	NR	NR	NR	NR	Surgery	NR
	NR	NR	NR	NR	NR	NR	NR	NR	Surgery	NR
Chan et al, 2009 ⁸	NR	NR	NR	NR	NR	NR	NR	Yes† (lung, brain, bone)	NR	NR

Abbreviations: CT = chemotherapy; DOD = died of disease; F = female; M = male; ND = nodal dissection; NED = no evidence of disease; NR = not reported; RT = radiotherapy; WLE = wide local excision.

* Distant metastasis developed subsequently.

† Concomitant lymph node and distant metastasis.

Patients with one or more recurrences appear to be more at risk for lymph node metastasis than those with no recurrence. Data on the interval between first appearance of disease to occurrence of lymph node metastasis was incomplete, varying from four months to five years. The report by Brenner et al⁹ indicates that late recurrence is possible. The patient in this report developed lymph node metastasis 17 years after the first presentation,

which probably represents one of the longest, if not the longest, disease-free interval for DFSP.

Patients with concomitant distant metastasis had a poor outcome. Two patients with known concomitant distant metastasis died within one year. Nodal dissection seemed to be important for prognosis. Patients who received non-surgical treatment with chemotherapy or

radiotherapy had a poorer prognosis, and all of them died within two years. However, this can be confounded by the possibility that patients for whom nodal dissection was not performed may have had advanced inoperable disease or concomitant distant metastasis. Patients who underwent nodal dissection appeared to be long survivors, with survival up to eight years observed. An exception was the patient reported by Volpe and Carbone,¹³ in whom distant metastasis occurred two months after radical nodal dissection, and the patient died two months after diagnosis of distant metastasis. However, there was no mention of any systemic examination before nodal dissection, and it is possible that subclinical metastases was already present at the time of surgery given the short postoperative disease-free interval.

It has been reported that DFSP with fibrosarcomatous areas has a more aggressive course than classical DFSP, with reported rates of metastasis of 14.7% and tumour-related death of 5.8%.²³ This type of histological variant was not mentioned in the 20 patients identified by the authors, and its specific association with lymph node metastasis is not known.

Other known unfavourable prognostic factors for DFSP include high mitotic rates, increased cellularity, and increased age.^{4,24} Whether these factors translate into a poorer outcome for patients with lymph node metastasis could not be concluded from the review of 20 patients. Also, no specific relationship could be observed between time to recurrence and the final outcome.

This patient had experienced two recurrences preceding the appearance of lymph node metastasis, concurring with the findings from the literature that repeated local recurrence is a risk factor for lymph node metastasis. The disease-free interval was 15 years, which is a relatively long time, and was not observed in other patients reported in the literature. Another feature that is different from those reported in the literature is that the primary site of the tumour was the trunk. As this patient developed isolated lymph node metastasis treated by radical lymph node dissection followed by postoperative radiotherapy, the patient is expected to be a long-term survivor, as inferred from the literature review.

After confirmation of diagnosis by biopsy, surgical resection remains the mainstay of treatment of primary DFSP and the key to success is clear surgical margins.³

Wide local excision with at least 2 to 3 cm margins is advocated. Where there is expertise available, Moh's micrographic surgery is the treatment of choice as it permits margin control and conservation of uninvolved tissue.^{3,25-27} Preoperative or adjuvant radiotherapy significantly reduces the risk of local recurrences where there are close or positive margins.^{3,28,29}

In view of the extreme rarity of metastasis to the regional lymph nodes, prophylactic regional lymph node dissection is not advocated. This is supported by studies that reported no lymph node invasion was found when elective prophylactic regional lymph node dissection was performed.^{27,30} When lymph node metastasis is diagnosed, it is important to examine for distant metastasis. When isolated lymph node metastasis is confirmed, radical lymph node dissection is the treatment of choice. The role of radiotherapy following nodal dissection is uncertain, but it was given to this patient because of the presence of extracapsular extension, with the aim of better regional control.

For patients with disseminated DFSP, chemotherapy is proven to be ineffective. Recently, imatinib mesylate, a selective tyrosine kinase inhibitor against the PDGF receptor tyrosine kinase, has been reported to induce complete or partial remissions in patients with advanced DFSP with t(17;22).³¹ Those patients who lack t(17;22) seem to have no response to imatinib. Imatinib has been approved by the US Food and Drug Administration for treatment of patients with unresectable, locally advanced, recurrent or metastatic DFSP.

This patient illustrates that the clinical course of DFSP can be long, and it is important to examine the regional lymphatic system in addition to the primary site during follow-up, especially for patients with repeated local recurrences. When there is no distant metastasis, the treatment of choice for the rare lymph node metastasis is radical lymph node dissection. Close surveillance for subsequent distant metastasis after regional treatment is warranted.

ACKNOWLEDGEMENT

Special thanks to Dr Kwan-Ho Yiu, Clinical and Histopathology Laboratory, St Teresa's Hospital for his generous assistance in providing the pathology slides.

REFERENCES

1. Gloster HM Jr. Dermatofibrosarcoma protuberans. *J Am Acad Dermatol.* 1996;35:355-74; quiz 375-6.

2. Chuang TY, Su WP, Muller SA. Incidence of cutaneous T cell lymphoma and other rare skin cancers in a defined population. *J Am Acad Dermatol.* 1990;23:254-6.
3. Mendenhall WM, Zlotecki RA, Scarborough MT. Dermatofibrosarcoma protuberans. *Cancer.* 2004;101:2503-8.
4. Rutgers EJ, Kroon BB, Albus-Lutter CE, Gortzak E. Dermatofibrosarcoma protuberans: treatment and prognosis. *Eur J Surg Oncol.* 1992;18:241-8.
5. Mavili ME, Gursu KG, Gokoz A. Dermatofibrosarcoma with lymph node involvement. *Ann Plast Surg.* 1994;32:438-40.
6. Laskin WB. Dermatofibrosarcoma protuberans. *CA Cancer J Clin.* 1992;42:116-25.
7. McArthur G. Molecularly targeted treatment for dermatofibrosarcoma protuberans. *Semin Oncol.* 2004;31(2 Suppl 6):30-6.
8. Chan AY, Luk NM, Lee KC. Dermatofibrosarcoma protuberans: a report of 36 cases in Hong Kong and review of the literature. *Hong Kong Journal of Dermatology and Venereology.* 2009;17:6-11.
9. Brenner W, Schaeffler K, Chhabra H, Postel A. Dermatofibrosarcoma protuberans metastatic to a regional lymph node. Report of a case and review. *Cancer.* 1975;36:1897-902.
10. Lal P, Goel A, Mandal AK. Dermatofibrosarcoma protuberans of scalp with cervical lymph node metastasis. *Sarcoma.* 2004;8:43-5.
11. Cai H, Shi YQ, Wang YN, Zhu HY, Mo SJ. [Realization of clinical diagnoses and treatment for dermatofibrosarcoma protuberans]. *Zhonghua Wai Ke Za Zhi.* 2004;42:678-82. Chinese.
12. Hausner RJ, Vargas-Cortes F, Alexander RW. Dermatofibrosarcoma protuberans with lymph node involvement. A case report of simultaneous occurrence with an atypical fibroxanthoma of the skin. *Arch Dermatol.* 1978;114:88-91.
13. Volpe R, Carbone A. Dermatofibrosarcoma protuberans metastatic to lymph nodes and showing a dominant histiocytic component. *Am J Dermatopathol.* 1983;5:327-34.
14. Peto DS, Verola O, Banzet P, Dufourmentel C, Servant JM. [Darier-Ferrand dermatofibrosarcoma. Study of 96 cases over 15 years]. *Chirurgie.* 1985;111:132-8. French.
15. Hirabayashi S, Kajikawa A, Kanazawa K, Mimoto K. Dermatofibrosarcoma protuberans with regional lymph node metastasis: a case report. *Head Neck.* 1989;11:562-4.
16. Fisher ER, Hellstrom HR. Dermatofibrosarcoma with metastases simulating Hodgkin's disease and reticulum cell sarcoma. *Cancer.* 1966;19:1165-71.
17. Wooldridge WE. Dermatofibrosarcoma protuberans; a tumor too lightly considered. *AMA Arch Derm.* 1957;75:132-4.
18. Lal P, Sharma R, Mohan H, Sekhon MS. Dermatofibrosarcoma protuberans metastasizing to lymph nodes: a case report and review of literature. *J Surg Oncol.* 1999;72:178-80.
19. Przybora LA, Wojnerowicz C. Malignancy of dermatofibrosarcoma protuberans and report of 2 cases with lymph gland metastases. *Oncologia.* 1959;12:236-54.
20. Gentele H. Malignant, fibroblastic tumors of the skin; clinical and pathological-anatomical studies of 129 cases of malignant, fibroblastic tumors from the cutaneous and subcutaneous layers observed at Radiumhemmet during the period 1927-1947. *Acta Derm Venereol Suppl (Stockh).* 1951;27:1-180.
21. Waldermann F, Hagedorn M. [Clinical picture and pathology of dermatofibrosarcoma protuberans]. *Z Hautkr.* 1985;60:1886-8, 1891-4. German.
22. Kahn LB, Saxe N, Gordon W. Dermatofibrosarcoma protuberans with lymph node and pulmonary metastases. *Arch Dermatol.* 1978;114:599-601.
23. Mentzel T, Beham A, Katenkamp D, Dei Tos AP, Fletcher CD. Fibrosarcomatous ("high-grade") dermatofibrosarcoma protuberans: clinicopathologic and immunohistochemical study of a series of 41 cases with emphasis on prognostic significance. *Am J Surg Pathol.* 1998;22:576-87.
24. Bowne WB, Antonescu CR, Leung DH, Katz SC, Hawkins WG, Woodruff JM, et al. Dermatofibrosarcoma protuberans: A clinicopathologic analysis of patients treated and followed at a single institution. *Cancer.* 2000;88:2711-20.
25. Nouri K, Lodha R, Jimenez G, Robins P. Mohs micrographic surgery for dermatofibrosarcoma protuberans: University of Miami and NYU experience. *Dermatol Surg.* 2002;28:1160-4; discussion 1064.
26. Ah-Weng A, Marsden JR, Sanders DS, Waters R. Dermatofibrosarcoma protuberans treated by micrographic surgery. *Br J Cancer.* 2002;87:1386-9.
27. McPeak CJ, Cruz T, Nicastrì AD. Dermatofibrosarcoma protuberans: an analysis of 86 cases—five with metastasis. *Ann Surg.* 1967;166:803-16.
28. Suit H, Spiro I, Mankin HJ, Efirid J, Rosenberg AE. Radiation in management of patients with dermatofibrosarcoma protuberans. *J Clin Oncol.* 1996;14:2365-9.
29. Ballo MT, Zagars GK, Pisters P, Pollack A. The role of radiation therapy in the management of dermatofibrosarcoma protuberans. *Int J Radiat Oncol Biol Phys.* 1998;40:823-7.
30. Tamoney HJ Jr. Dermatofibrosarcoma protuberans. A review of twelve cases. *Conn Med.* 1971;35:674-80.
31. McArthur GA, Demetri GD, van Oosterom A, Heinrich MC, Debiec-Rychter M, Corless CL, et al. Molecular and clinical analysis of locally advanced dermatofibrosarcoma protuberans treated with imatinib: Imatinib Target Exploration Consortium Study B2225. *J Clin Oncol.* 2005;23:866-73.