
CASE REPORT

A Multidisciplinary Approach to the Management of Unresectable Hepatocellular Carcinoma

CKK Choi

Department of Clinical Oncology, Tuen Mun Hospital, Tuen Mun, Hong Kong

ABSTRACT

With the advances that have been made in the field of radiation technology over the past decade, radiotherapy has become a feasible and promising treatment modality for hepatocellular carcinoma. One of the most influential advances in this context has been the development of sophisticated image guidance systems that allow greater precision in targeting the planned area of irradiation. A multidisciplinary team is involved in the management of patients with hepatocellular carcinoma at Tuen Mun Hospital, Hong Kong, with stereotactic radiotherapy being just one of the treatment modalities that can potentially be integrated into a comprehensive treatment plan that is tailored to each patient's clinical circumstances. This report is of the clinical outcomes of three patients with unresectable hepatocellular carcinoma who were treated with stereotactic radiotherapy.

Key Words: *Carcinoma, hepatocellular; Radiosurgery; Treatment outcome*

中文摘要

多學科整合方法治理不能切除的肝癌

蔡國強

隨著輻射技術過去十年的進步，放射治療已成為肝癌一個可行及有效的治療方法。其中最具有影響力的進展是精密的圖像引導系統，它已研發精確的定位技術以計劃出準確的放射治療位置。香港屯門醫院一個跨學科團隊為肝癌患者進行治理，根據每位病人的臨床個別情況策劃全面的治療方案，其中包括立體定向放射治療。本文報告三名不能手術切除的肝癌患者接受立體定向放射治療的臨床結果。

INTRODUCTION

Recent advances that have been made in the field of radiation technology include the use of stereotactic radiotherapy (SRT) for the treatment of hepatocellular carcinoma (HCC). Treatment can be tailored to each patient's clinical circumstances via a multidisciplinary team. This report describes three patients with unresectable HCC who were treated with SRT at Tuen Mun Hospital, Hong Kong.

CASE REPORTS

Patient 1

A 71-year-old woman, who was a hepatitis B virus carrier with a history of hypertension, presented in September 2009 with a left hepatic mass. She had an alpha-fetoprotein (AFP) level of 31 µg/l (reference range, <10 µg/l), and computed tomography (CT) scan revealed a 10 x 7-cm hypervascular left hepatic mass distending the liver capsule, with central necrosis.

*Correspondence: Dr Calvin Kwok-keung Choi, Department of Clinical Oncology, Basement, Tuen Mun Hospital, Tsing Chung Koon Road, Tuen Mun, Hong Kong
Tel: (852) 2468 5080 ; Email: choikk@ha.org.hk*

Numerous hypervascular nodules about 1 cm in size were scattered throughout the liver, but the portal vein appeared patent (Figure 1a). Her diagnosis was HCC, which was assessed as Child-Pugh score A5, T4 N0 M0, stage IIIC according to the American Joint Committee on Cancer (AJCC) system (7th edition), and stage C according to the Barcelona Clinic Liver Cancer (BCLC) classification.

The multidisciplinary team at Tuen Mun Hospital elected to use transarterial chemoembolization (TACE) and SRT as the tumour was inoperable. TACE was performed in October 2007, and SRT was administered to the main bulk of the liver tumour in November 2007, with gating and ExacTrac® image guidance (Brainlab AG, Feldkirchen, Germany) to 32 Gy in eight fractions. In February 2008, the tumour had regressed to 5 x 6 cm and the numerous nodules had resolved. At this point, the tumour was considered potentially resectable.

The patient underwent lateral segmentectomy of the liver in May 2008; a 6-cm tumour was found at the left lateral segment with a daughter nodule. Pathology detected no viable tumour. In September 2008, the patient's AFP level was 2.5 µg/l, and follow-up was recommended every three to six months. In January 2009, no residual tumour was visible on CT (Figure 1b). The patient was last seen in February 2012, when she was well and asymptomatic with an AFP within the normal range. Follow-up ultrasonography in May 2012

showed no evidence of recurrence, and she continues to attend for follow-up. To date, this patient is recurrence-free four years after SRT plus surgery.

Patient 2

A 36-year-old man underwent right hepatectomy in mainland China in July 2007 for hepatitis B serum antigen (HBsAg)-negative, hepatitis C virus antibody (anti-HCV)-negative HCC. At that time, HCC was staged as T2 Nx Mx. Although his AFP level decreased from >1000 µg/l to 100 µg/l immediately after the operation, it increased to 600 µg/l within one month. A CT scan performed in China in October 2007 revealed tumour recurrence at the right hepatic lobe with inferior vena cava (IVC) invasion. A private surgeon assessed the tumour as unresectable, and the patient could not afford targeted therapy.

When the patient presented to Tuen Mun Hospital in November 2007, the HCC was assessed as Child-Pugh score A5, AJCC T4 N0 M0 stage IIIC, and BCLC stage C. The CT scan was repeated to assess the feasibility of TACE or SRT. This scan showed liver cirrhosis and a filling defect at the intrahepatic IVC suggestive of tumour recurrence (Figure 2a). The IVC tumour was treated with SRT in December 2007, at a dose of 40 Gy/10 fractions daily, with active breath control (ABC) and ExacTrac image guidance. In February 2008, the patient's AFP levels decreased to 2.1 µg/l and then 1.8 µg/l.

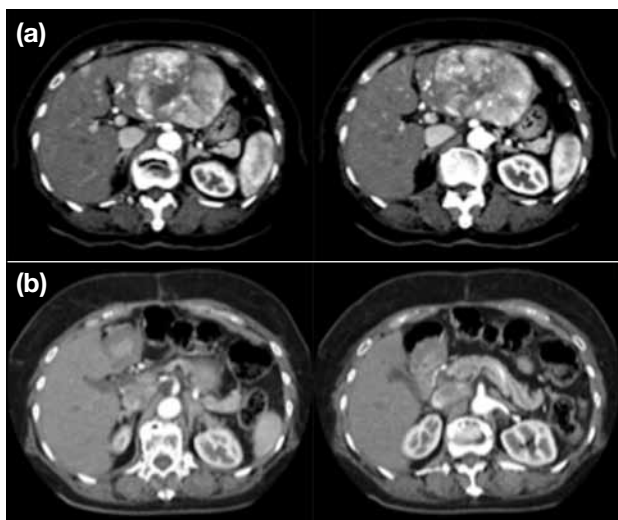


Figure 1. Abdominal computed tomography scans of a patient with hepatocellular carcinoma at (a) baseline, showing a hypervascular left hepatic mass, and (b) 14 months after stereotactic radiotherapy and surgery, with no residual tumour visible.

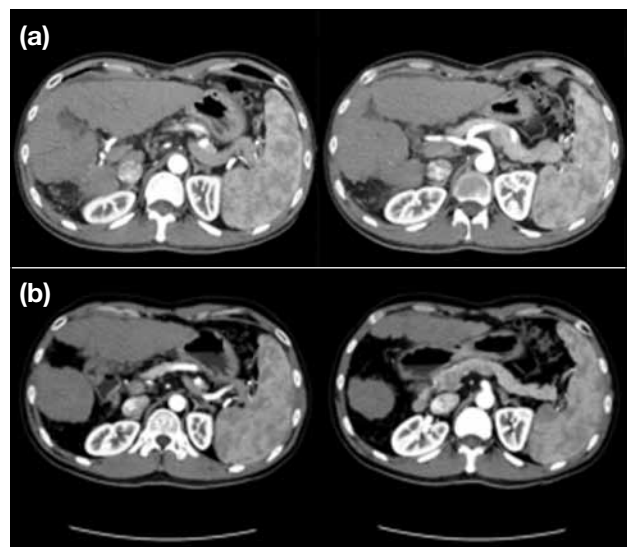


Figure 2. Abdominal computed tomography scans of a patient with hepatocellular carcinoma in (a) November 2007 and (b) 22 months after stereotactic radiotherapy.

Nine months after radiotherapy (RT) treatment, the CT scan showed a 0.4-cm tumour thrombus on the right intrahepatic IVC, but otherwise no evidence of residual tumour. On CT at 22 months post-RT, liver cirrhosis was evident, but no abnormal enhancement of a liver mass or tumour thrombus could be seen (Figure 2b). An ultrasound in April 2012 showed no evidence of recurrence, and the patient's AFP level was 1.7 $\mu\text{g/l}$. He was last seen in June 2012 when he was clinically well, still with no evidence of recurrence and an AFP of 2.5 $\mu\text{g/l}$. In this patient, recurrence-free survival is now 4.5 years since SRT following post-surgical relapse.

Patient 3

A 48-year-old man presented in November 2009 to multidisciplinary team with HBsAg-positive HCC. CT scan showed a large 23.5-cm right hepatic mass (Figure 3a). Thrombosis was present in the main portal and superior mesenteric veins, and his AFP level was $>363,000 \mu\text{g/l}$. His HCC was assessed as CP score A6, AJCC T3b N0 M0, stage IIIB, and BCLC stage C. The patient had been given limited TACE (because of tumour involvement in the portal vein) in October 2009.

The multidisciplinary team decided to proceed with SRT followed by superselective TACE. SRT was applied to the right lobe mass with 4-dimensional (4D) CT and ExacTrac image guidance at a dose of 4 Gy/fraction at the 90% isodose line daily for seven fractions. At the three-month post-SRT CT scan, the tumour size had decreased to 12 cm; however, there were increased segment 2 and 3 nodules, which were likely to be tumour foci. The patient's clinical course was observed, and monitoring of AFP levels showed appreciable decreases from three months' post-SRT, reaching about 700 $\mu\text{g/l}$ by July 2010. Although the follow-up CT scan eight months after SRT showed a static right hepatic mass and smaller lesions in segments 2 and 3 (Figure 3b), a new left lower lobe lung mass was detected.

The patient was offered a choice of sorafenib therapy, clinical trial participation, or best supportive care; he chose to join a clinical trial in July 2010, which involved combination therapy with sorafenib and a new agent, AEG35156. Serial CT scans performed throughout 2010 and 2011 all indicated a partial response to therapy. In January 2012, liver disease was static, and CT results 30 months after SRT and

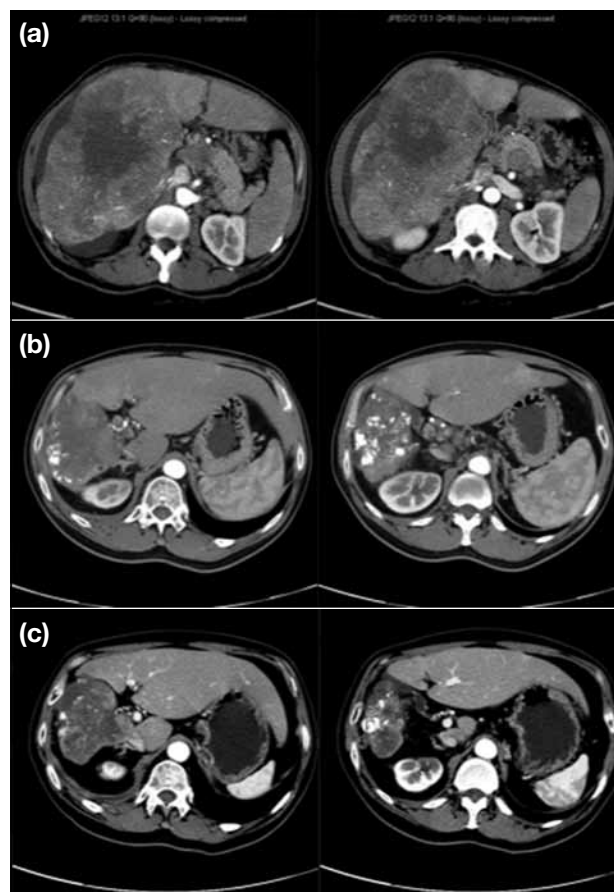


Figure 3. Abdominal computed tomography scans of a patient with hepatocellular carcinoma at (a) baseline, (b) 8 months after stereotactic radiotherapy, and (c) 22 months after targeted therapy.

22 months after the targeted therapy showed that the right liver lobe tumour was static, the segment 2 and 3 nodules had decreased in size (Figure 3c), and the left lower lobe lung metastasis had also decreased in size to 9 mm. Extended right hepatectomy was then performed, resulting in a gradual drop of AFP level. Sorafenib was resumed postoperatively and SRT was also delivered to the small residual lung nodule, providing a progression-free survival of almost three years from the SRT to the liver.

CONCLUSION

SRT for primary HCC provides at least good palliation, and it may have a potential role in neoadjuvant and even radical treatment. Above all, a multidisciplinary approach is mandatory for successful management of HCC.