
ORIGINAL ARTICLE

Endovascular Interventions for Peripheral and Central Venous Stenosis in Haemodialysis Patients with Arteriovenous Grafts

KL Siu, FNY Sin, CY Fong, B Lo, LF Cheng, JKF Ma

Department of Radiology, Princess Margaret Hospital, Laichikok, Hong Kong

ABSTRACT

Purpose: To evaluate the efficacy of percutaneous balloon angioplasty for peripheral and central venous stenosis in haemodialysis patients with arteriovenous grafts.

Methods: Retrospective review of data from January 2006 to December 2010 was performed. Patients with arteriovenous grafts with single focal site (length <2.0 cm) venous stenosis who had initial successful balloon angioplasty were selected. Follow-up was performed at the attending renal centre with repeat angiograms as clinically required.

Results: Initial technical success rates were 96% and 84% for peripheral and central stenoses, respectively. Primary patency rates at 12 months for treated peripheral and central venous stenoses were 50% and 14%, respectively. The difference in primary patency rates in the two groups was statistically significant. The location of stenosis was the only dependent factor.

Conclusion: The results are comparable to those quoted by the National Kidney Foundation Dialysis Outcomes Quality Initiative guidelines. Percutaneous angioplasty at venous anastomosis and draining veins is a safe procedure, which prolongs patency. Due to the low primary patency rate of central stenosis, resorting to other methods such as the cutting balloon and stent-assisted angioplasty should be considered for such central lesions that recur.

Key Words: Angioplasty; Arteriovenous fistula; Renal dialysis

中文摘要

血液透析患者動靜脈內瘻術後外週和中心靜脈狹窄的血管內介入治療

蕭廣樂、單雅怡、方俊仁、羅彪、鄭力輝、馬家輝

目的：評估經皮球囊血管成形術對血液透析患者動靜脈內瘻術後外週和中心靜脈狹窄的療效。

方法：回顧2006年1月至2010年12月此類病人資料。入選病人為單發局灶性（長度少於2 cm）靜脈狹窄，初次球囊血管成形術均成功。術後隨訪依據臨床要求，於腎病診療中心施以多次血管造影。

結果：外週和中心靜脈狹窄患者的初次手術成功率分別為96%及84%，術後12個月初級通暢率則分別為50%及14%。兩組病人的初級通暢率有顯著統計學差異。狹窄部位是唯一決定因素。

結論：本研究結果與美國國家腎病基金會的透析預後質量倡議指南相一致。於靜脈吻合口和引流靜

Correspondence: Dr Francesca KL Siu, Department of Radiology, HLG 1, Main Block, Princess Margaret Hospital, Laichikok, Kowloon, Hong Kong.

Tel : (852) 9045 2913 ; Email: klsiu@hotmail.com

Submitted: 15 Jun 2012; Accepted: 28 Aug 2012.

脈處行經皮血管成形術是維持血透通路開放的安全方法。由於中心靜脈狹窄初級通暢率偏低，狹窄復發時可考慮採用切割球囊血管成形術及腔內支架植入術等其他方法。

INTRODUCTION

After its introduction in 1960s, arteriovenous (AV) fistula haemodialysis has become the most common renal replacement therapy used in patients with end-stage renal failure. Although the ultimate treatment for these patients is renal transplantation, even in developed countries, the renal transplantation rate is still far from satisfactory and a few years to decades of waiting before transplantation are common.¹ Maintaining patency of the vascular access for rapid extracorporeal blood flow in patients undergoing haemodialysis is one of the major clinical challenges.

The National Kidney Foundation Dialysis Outcomes Quality Initiative (NKFDOQI) recommends early detection and treatment of stenosis at poorly functioning fistulas to extend their lifespan.² Since the advent of percutaneous angioplastic treatment of fistulae by Gordon et al,³ Hunter et al,⁴ and Gaux et al,⁵ this form of treatment for AV fistula stenosis has become more widely known and popular. This study aimed to evaluate and compare post-angioplasty 12-month patency rates of peripheral and central venous stenoses in these patients.

METHODS

Patient Selection

Patients on maintenance haemodialysis who underwent percutaneous transluminal angioplasty (PTA) between January 2006 and December 2010 at Princess Margaret Hospital were reviewed. Inclusion criteria included the use of only synthetic graft (polytetrafluoroethylene

[PTFE]; Gore-Tex; Flixene Vascular Graft, Atrium Medical Corporation, USA), and single site of stenosis involving short segments (<2 cm). The patients also had to have post-dilatation angiograms showing less than 30% residual stenosis at peripheral lesions and less than 50% residual stenosis at central lesions, and at least one successful haemodialysis after the treatment.

Peripheral stenosis was defined as stenosis occurring at the venous anastomosis affecting the proximal 4 cm on the venous side. Arterial site stenosis was excluded because there were not enough cases for statistical analysis. Central stenosis was defined as those occurring distal to the peripheral veins that affected the cephalic, basilic, axillary, subclavian, and brachiocephalic veins.

Different criteria are adopted for defining successful treatment of peripheral and central lesions, because central veins have lumens of larger calibre (usually <10 mm), for which a higher degree of residual stenosis is generally regarded as acceptable than for smaller peripheral veins.

Treatment Description

Stenoses were treated by standard angioplasty techniques using a transvenous approach. A set of pre-treatment AV fistulograms was obtained. The stenosis was negotiated through using a 0.035-inch guide-wire (Terumo, Tokyo, Japan). Standard non-compliant balloons were used (Powerflex; Cordis, Johnson & Johnson, Netherlands). Heparin was administered intravenously before balloon inflation, with dosages

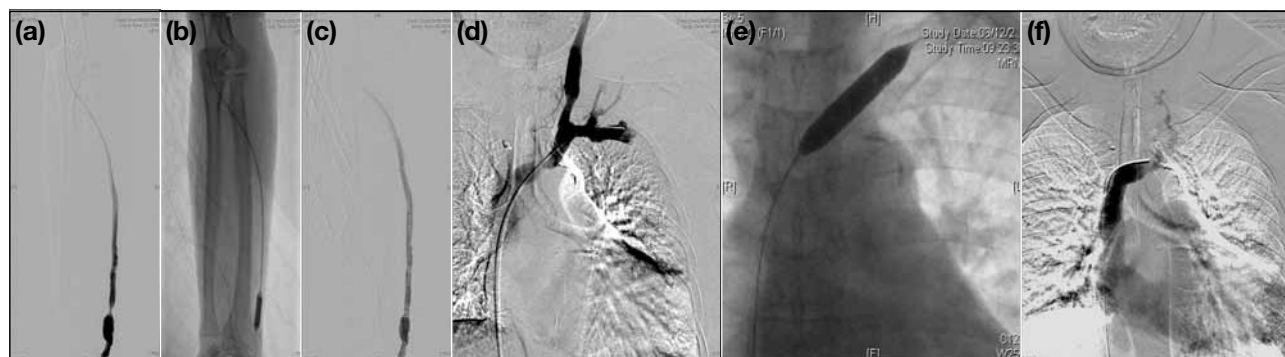


Figure 1. (a to c) Digital subtraction angiography (DSA) demonstrating peripheral stenosis, angioplasty procedure, and post-angioplasty angiogram. (d to f) DSA demonstrating central stenosis, angioplasty procedure, and post-angioplasty angiogram.

ranging from 3000 to 5000 units. After angioplasty, another set of AV fistulograms were obtained to assess treatment results (Figure 1).

The procedure was considered technically successful if there was less than 30% and 50% residual narrowing for peripheral and central lesion, respectively and that at least one successful haemodialysis could be performed after the angioplasty.

We usually prescribe clopidogrel (Plavix, clopidogrel bisulfate; Sanofi and Bristol-Myers-Squibb) 300 mg one day before angioplasty, followed by 75 mg daily for four weeks and aspirin 150 mg daily for life. We also adopt clinical surveillance for patients having abnormal dialysis pressures while undergoing elective diagnostic fistulograms for follow-up. Typically fistulograms entailed using a standard 16-gauge needle with venous dialysis pressures of 100 to 150 ml/min.

All statistical tests, including Kaplan-Meier and linear logistic analyses, were performed using Statistical Package for the Social Sciences (Windows version 16; SPSS Inc, Chicago [IL], USA).

RESULTS

Sixteen patients had peripheral stenosis, with a mean age of 56 years (Table 1). In total, they had 26 angioplasties; one had 4 angioplasties, two had 3 each, and three had 2 each. There was only one basilic vein stenosis of around 80% in our series, and the residual stenosis after angioplasty was 20%. The remaining cases of central stenosis were all subclavian and brachiocephalic. To simplify comparison, we classified all peripheral cases to be venous anastomosis affecting the proximal 4 cm on the venous side.

Fourteen patients had central stenosis, with a mean age of 59 years (Table 1). In these patients 21 angioplasties were performed; two had 3 angioplasties each and three had 2 each.

The success rates of angioplasty for peripheral and central stenosis were 96% and 84%, respectively. The primary patency rates at 3, 6, and 12 months are shown in Table 2. The median patency time for peripheral lesion was 186 days and for central lesion it was 140 days.

A Kaplan-Meier analysis was performed to compare the primary patency rates after angioplasty for peripheral

Table 1. Summary of demographic data.

Demographics	Peripheral stenosis (n=16)	Central stenosis (n=14)
Sex		
Male	4	5
Female	12	9
Age (years)	56 (39-73)	59 (48-76)
Diabetes mellitus	5	6
Ischaemic heart disease	2	9

Table 2. Primary patency rates in peripheral and central stenosis.

Follow-up (months)	Peripheral stenosis (%)	Central stenosis (%)
3	96	71
6	61	33
12	50	14

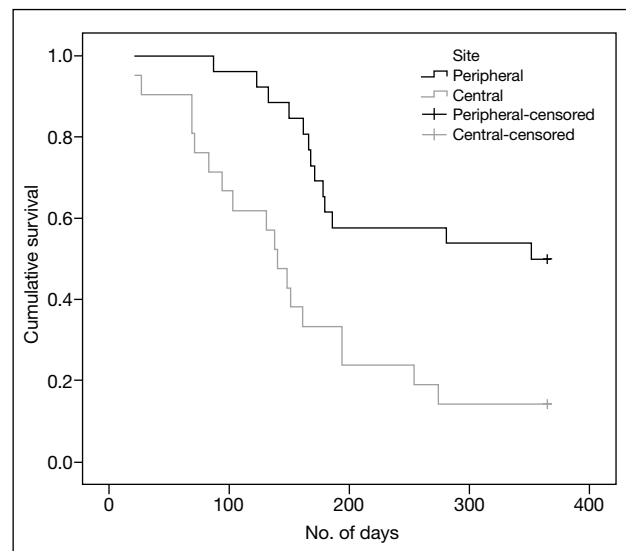


Figure 2. Kaplan-Meier curve shows primary patency of peripheral and central venous angioplasties.

and central stenosis. This yielded a statistically significant difference between the two groups (Figure 2).

A linear logistic analysis was also performed to assess the dependent factor. The location of the stenosis was shown to be the only dependent factor ($p < 0.005$).

DISCUSSION

Establishing and maintaining vascular access in haemodialysis patients are important prognostic factors affecting quality of life and survival for these patients. Zibari et al⁶ showed that the mean patency rate for PTFE graft was about 1.75 years, and the most

common cause of failure was thrombosis, which was estimated to account for around 64% of all failures. To achieve and improve long-term haemodialysis access function, PTA has been used widely.⁷ Currently, percutaneous management of AV fistula stenosis includes balloon angioplasty, stenting, and thrombolysis / thromboaspiration. The patients can be dialysed immediately after the procedure. Also, repeated treatment of the same lesion can be performed, without loss of vascular access and most importantly there is an acceptable technical success rate and can help maintain patency of the AV fistula in the long term.

The primary patency rate of peripheral graft stenosis by PTA without thrombosis was around 80% by three months. It has a clinical success rate of about 85 to 98%.^{7,8} In one series of graft stenoses with thrombosis, the success rate was about 75 to 94%, but the primary patency rate decreased to 40% by three months.⁸

Central venous stenosis and occlusion was reported to occur in around 14% of haemodialysis patients.⁹ The reported clinical success rate of angioplasty in this group of patients is above 90%.^{9,10} According to various authors, the primary patency rate after PTA was reported to be 9 to 33% at 12 months.¹⁰ Beathard¹¹ reported a 12-month patency rate of 0% after PTA for central venous stenosis. Our study shows comparable

results with the literature in terms of the initial success rate and the 12-month primary patency rate in both types of stenoses.

After PTA, central venous obstruction has a tendency to recur earlier than peripheral venous stenosis.^{12,13} The pathogenesis is still not fully understood, though neo-intimal proliferation, elastic recoil, elongation of the vein, and valvular hypertrophy have all been proposed as contributing factors.¹⁴

Various tools and methods are used to achieve a longer primary patency rate. Ultra-high-pressure balloon, cutting balloon, stents, and even mechanical thrombolysis devices are used to achieve this goal. Trerotola et al¹⁵ claimed that an ultra-high-pressure balloon had a 100% technical success rate. For the treatment of resistant haemodialysis-related venous stenosis, this entailed ultra-high-pressure angioplasty balloons at atmospheric pressures or above the manufacturer-recommended burst pressure (30 atm). Cutting balloons also improve the technical success rate in a similar way. In our experience, its technical success rate is also higher in patients who have failed balloon angioplasty (Figure 3). However, there is not yet enough evidence to suggest an improvement in primary and cumulative patency rates.¹⁶ Very recently, endovascular stent placement has been demonstrated beneficial

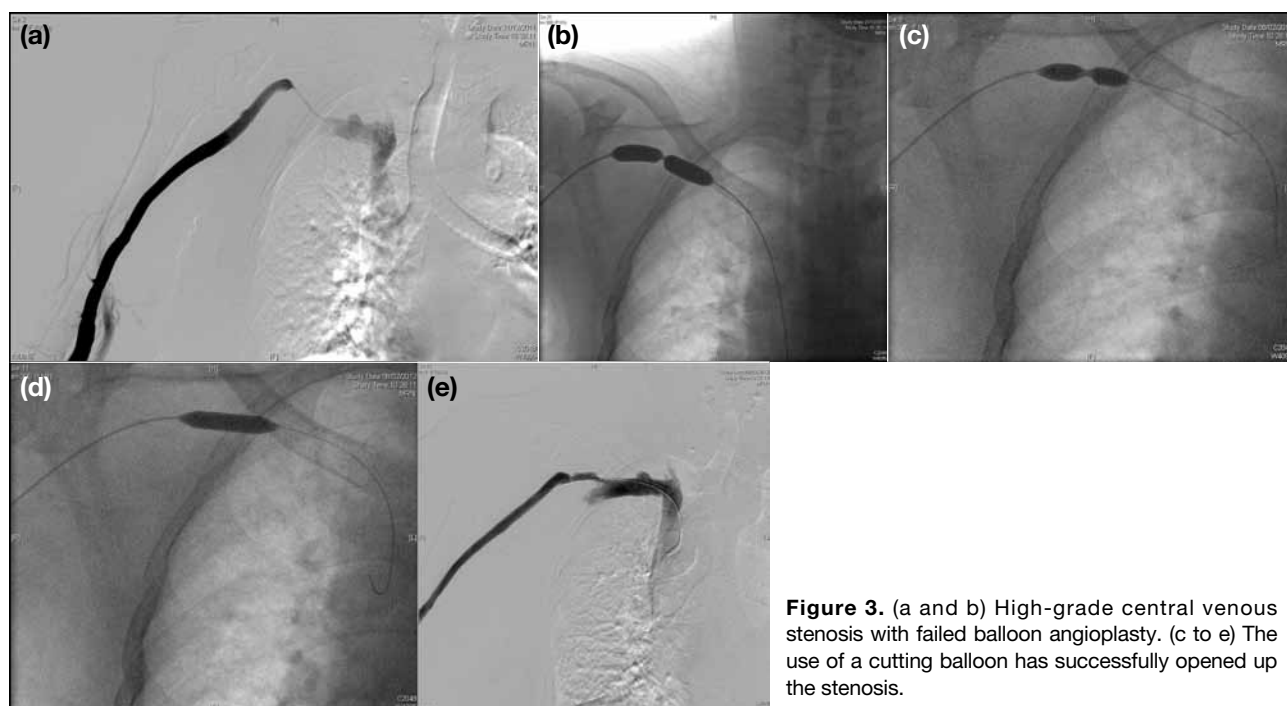


Figure 3. (a and b) High-grade central venous stenosis with failed balloon angioplasty. (c to e) The use of a cutting balloon has successfully opened up the stenosis.

in haemodialysis access grafts. Results suggest that without thrombosis, stent placement may confer a better patency rate. Stent placement patency rates at 3, 6, 12, 24 months have been reported to be 92%, 84%, 56% and 28%, respectively. In patients with failed PTA, stent placement may improve access blood flow in the short term, and may in turn translate to improved dialysis efficiency.^{11,17-19}

There are few mechanical thrombolysis devices available, including rotating baskets, rotating brushes, rotating screws, and hydrodynamic catheters. In general, mechanical thrombolysis using a macerating pulse of heparinised saline generated by crossed pulse-spray catheters followed by balloon maceration and dilation is effective and safe for the treatment of thrombosed dialysis access grafts as pharmaco-mechanical thrombolysis.

All studies show that mechanical thrombolysis devices effectively cleared the graft of enough thrombus to allow evaluation and subsequent treatment of venous stenosis. These devices yielded similar clinical success and even higher primary patency rates than espoused in the NKFDOQI guidelines, and appear to have lower liability to cause bleeding complications.²⁰⁻²²

Despite the various ways to improve the clinical success rate of PTA, there is considerable controversy about the factors affecting outcomes. These include type of lesion, patient characteristics, previous history of intervention, and quality of haemodialysis. Notwithstanding these concerns, interventionalists should try to merge their own experience and patency data with the product manufacturer's suggestions.

Complications of PTA include vein rupture, arterial embolus, pulmonary embolism, graft extravasation, small haematoma, pseudoaneurysm formation, and even death. Venous rupture is a more common one, occurring in 1.4 to 14.9% of cases; risk factors include long segment lesions and use of ultra-high-pressure balloons.²³

Arterial embolism as a complication is reported to occur in about 12% of cases. Conservative management is suggested in asymptomatic patients.²⁴ Depending on whether lung scans or lung angiography is used, in animal studies pulmonary embolism is reported in 91% and 100% of cases, respectively. However, symptomatic instances after the procedure are few, possibly up to 4.7%.²⁵

CONCLUSION

The results reported here are comparable to those quoted by the NKFDOQI guidelines. Percutaneous angioplasty at venous anastomosis and draining veins is a safe procedure which prolongs patency. Due to the low primary patency rate of central stenosis, other methods such as cutting balloon and stent-assisted angioplasty should be considered to prolong the patency rate for recurrent venous stenosis.

REFERENCES

- Rodriguez JA, Armadans L, Ferrer E, Olmos A, Codina S, Bartolomé J, et al. The function of permanent vascular access. *Nephrol Dial Transplant*. 2000;15:402-8.
- III. NKF-K/DOQI Clinical Practice Guidelines for Vascular Access: update 2000. *Am J Kidney Dis*. 2001;37(Suppl 1):S137-81.
- Gordon DH, Glanz S, Butt KM, Adamsons RJ, Koenig MA. Treatment of stenotic lesions in dialysis access fistulas and shunts by transluminal angioplasty. *Radiology*. 1982;143:53-8.
- Hunter DW, So SK, Castaneda-Zuniga WR, Coleman CE, Sutherland DE, Amplatz K. Failing or thrombosed Brescia-Cimino arteriovenous dialysis fistulas. Angiographic evaluation and percutaneous transluminal angioplasty. *Radiology*. 1983;149:105-9.
- Gaux JC, Bourquelot P, Raynaud A, Seurot M, Cattan S. Percutaneous transluminal angioplasty of stenotic lesions in dialysis vascular accesses. *Eur J Radiol*. 1983;3:189-93.
- Zibari GB, Rohr MS, Landreneau MD, Bridges RM, DeVault GA, Petty FH, et al. Complications from permanent hemodialysis vascular access. *Surgery*. 1988;104:681-6.
- Zollikofer CL, Largiader I, Bruhlmann WF, Uhlenschmid GK, Marty AH. Endovascular stenting of veins and grafts: preliminary clinical experience. *Radiology*. 1988;167:707-12.
- Beathard GA. Percutaneous angioplasty for the treatment of venous stenosis: a nephrologist's view. *Semin Dial*. 1995;8:166-70.
- Schumacher KA, Walker B, Weidenmaier W, Friedrich JM. Venous occlusions distant to the shunt as malfunction factors during hemodialysis [in German]. *Rofo*. 1989;150:198-201.
- Gray RJ. Central venous lesions: diagnosis and management. In: Gray RJ, Sands JJ, editors. *Dialysis access: a multidisciplinary approach*. Philadelphia: Lippincott, Williams & Wilkins; 2002. p 184-96.
- Beathard GA. Percutaneous transvenous angioplasty in the treatment of vascular access stenosis. *Kidney Int*. 1992;42:1390-7.
- Kovalik EC, Newman GE, Suhocki P, Knelson M, Schwab SJ. Correction of central venous stenoses: use of angioplasty and vascular Wallstents. *Kidney Int*. 1994;45:1177-81.
- Haage P, Vorwerk D, Piroth W, Schuermann K, Guenther RW. Treatment of hemodialysis-related central venous stenosis or occlusion: results of primary Wallstent placement and follow-up in 50 patients. *Radiology*. 1999;212:175-80.
- Clark TW, Hirsch DA, Jindal KJ, Veugelers PJ, LeBlanc J. Outcome and prognostic factors of restenosis after percutaneous treatment of native hemodialysis fistulas. *J Vasc Interv Radiol*. 2002;13:51-9.
- Trerotola SO, Stavropoulos SW, Shlansky-Goldberg R, Tuite CM, Kobrin S, Rudnick MR. Hemodialysis-related venous stenosis: treatment with ultrahigh-pressure angioplasty balloons. *Radiology*. 2004;231:259-62.
- Vorwerk D, Adam G, Müller-Leisse C, Guenther RW.

- Hemodialysis fistulas and grafts: use of cutting balloons to dilate venous stenoses. *Radiology*. 1996;201:864-7.
17. Vogel PM, Parise C. Comparison of SMART stent placement for arteriovenous graft salvage versus successful graft PTA. *J Vasc Interv Radiol*. 2005;16:1619-26.
 18. Maya ID, Allon M. Outcomes of thrombosed arteriovenous grafts: comparison of stents vs angioplasty. *Kidney Int*. 2006;69:934-7.
 19. Chan MR, Bedi S, Sanchez RJ, Young HN, Becker YT, Kellerman PS, et al. Stent placement versus angioplasty improves patency of arteriovenous grafts and blood flow of arteriovenous fistulae. *Clin J Am Soc Nephrol*. 2008;3:699-705.
 20. Vogel PM, Bansal V, Marshall MW. Thrombosed hemodialysis grafts: lyse and wait with tissue plasminogen activator or urokinase compared to mechanical thrombolysis with the Arrow-Trerotola Percutaneous Thrombolytic Device. *J Vasc Interv Radiol*. 2001;12:1157-65.
 21. Beathard GA, Welch BR, Maidment HJ. Mechanical thrombolysis for the treatment of thrombosed hemodialysis access grafts. *Radiology*. 1996;200:711-6.
 22. Bush RL, Lin PH, Lumsden AB. Management of thrombosed dialysis access: thrombectomy versus thrombolysis. *Semin Vasc Surg*. 2004;17:32-9.
 23. Kornfield ZN, Kwak A, Soulen MC, Patel AA, Kobrin SM, Cohen RM, et al. Incidence and management of percutaneous transluminal angioplasty-induced venous rupture in the "fistula first" era. *J Vasc Interv Radiol*. 2009;20:744-51.
 24. Soulen MC, Zaetta JM, Amygdalos MA, Baum RA, Haskal ZJ, Shlansky-Goldberg RD. Mechanical declotting of thrombosed dialysis grafts: experience in 86 cases. *J Vasc Interv Radiol*. 1997;8:563-7.
 25. Trerotola SO, Johnson MS, Schauwecker DS, Davidson DD, Filo RS, Zhou XH, et al. Pulmonary emboli from pulse-spray and mechanical thrombolysis: evaluation with an animal dialysis-graft model. *Radiology*. 1996;200:169-76.