

---

---

## CASE REPORT

---

---

# Massive Ascites in Pregnancy: Meigs' Syndrome

G Ho<sup>1</sup>, SWV Chan<sup>1</sup>, PW Lam<sup>1</sup>, J Chai<sup>2</sup>

<sup>1</sup>Department of Radiology, and <sup>2</sup>Department of Obstetrics and Gynaecology, Queen Mary Hospital, Pokfulam, Hong Kong

### ABSTRACT

*Meigs' syndrome is a rare clinical entity consisting of a triad of ascites, pleural effusion, and benign ovarian tumour. The co-existence of Meigs' syndrome and pregnancy is even more infrequent. This report is of a pregnant woman with Meigs' syndrome. The superior role of magnetic resonance imaging over ultrasonography in establishing the ovarian origin of a large pelvic mass in the presence of a gravid uterus is also presented and discussed.*

*Key Words:* Ascites; Magnetic resonance imaging; Meigs syndrome; Pregnancy; Ultrasonography

## 中文摘要

### 妊娠期中出現大量腹水：梅格斯氏綜合徵

何潔明、陳秀慧、林培榮、柴逸蘭

梅格斯氏綜合徵 (Meigs' syndrome) 很少見，病人會出現腹水、胸腔積液及良性卵巢纖維瘤的症狀。妊娠期中出現梅格斯氏綜合徵更為罕有。本文報告的病例顯示，在子宮內有胎兒的情況下能找出盆腔內腫瘤是來自卵巢的，磁共振影像比超聲更能發揮作用。

### INTRODUCTION

New rapid accumulation of ascites is rare in obstetrics, and alarming to both the patient and obstetrician. The causes can be both benign, with good prognosis, and aggressive, requiring timely treatment. The extra-abdominal distension could give much discomfort to the pregnant patient. Early diagnosis and treatment are therefore crucial.

We report on a woman with a rare benign cause of ascites complicating pregnancy, as a triad of massive ascites, pleural effusion, and benign solid ovarian

tumour (Meigs' syndrome), and its characteristic spontaneous resolution upon tumour removal.

### CASE REPORT

A 31-year-old Asian woman, gravida 1 para 0, was referred from a private obstetrician for hospital admission due to rapid abdominal distension at 17 weeks of gestation and ultrasonography findings of gross maternal ascites in July 2011. The patient had a markedly distended abdomen to the xiphoid process, but no abdominal pain, uterine contraction, or leaking. A mobile hard mass of 10 cm in the lower abdomen

---

---

*Correspondence:* Dr Grace Ho, Department of Radiology, Queen Mary Hospital, 102 Pokfulam Road, Hong Kong.  
Tel: (852) 2255 3284; Fax: (852) 2255 5497; Email: mailgraceho@gmail.com

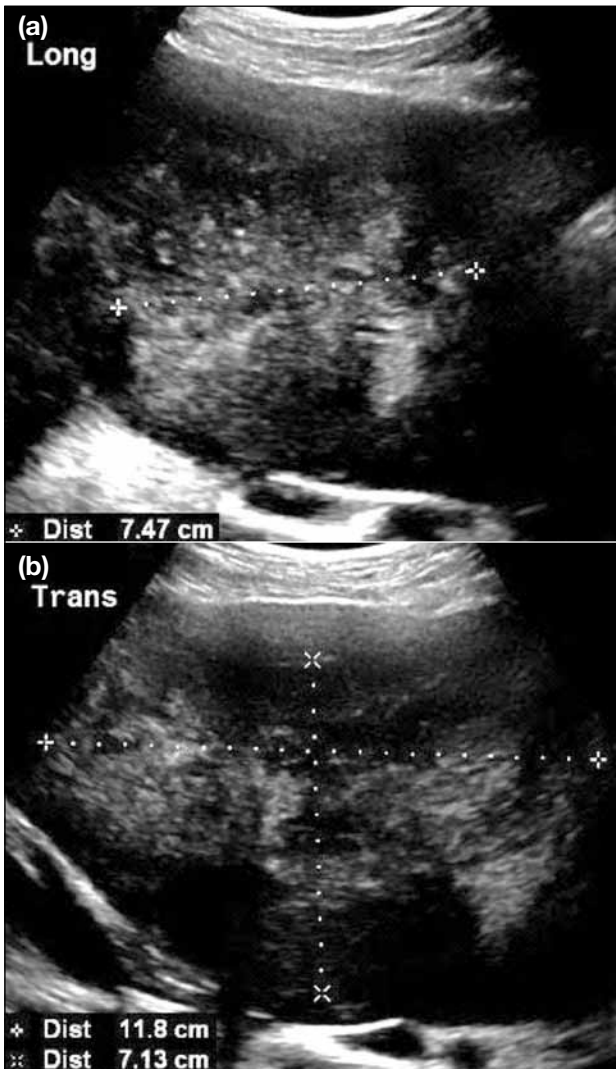Submitted: 8 Feb 2012; Accepted: 1 Mar 2012.

separated from the uterus was felt. Her past health was unremarkable.

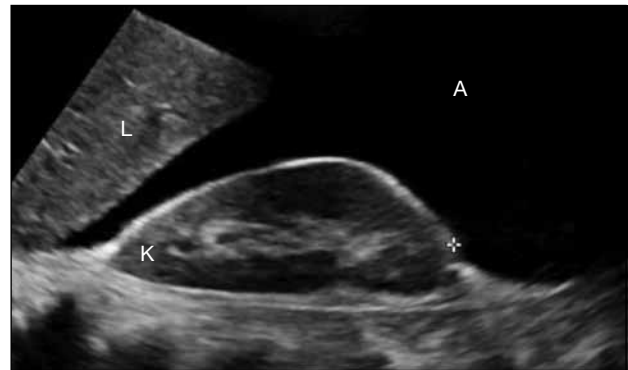Prior to referral, her antenatal dating ultrasonogram at 11 weeks of gestation incidentally showed an 11 x 7 x 9 cm heterogeneous hypoechoic mass anterior to the uterine wall, which was thought to be a large pedunculated uterine fibroid (Figure 1). No ascites was detected at that time. She did not have any symptoms, including pressure symptoms or menorrhagia prior to pregnancy.

A repeat transabdominal ultrasonogram at admission showed massive anechoic ascites (Figure 2) and a 14.0 x 10.0 x 9.4 cm heterogeneous solid hypoechoic

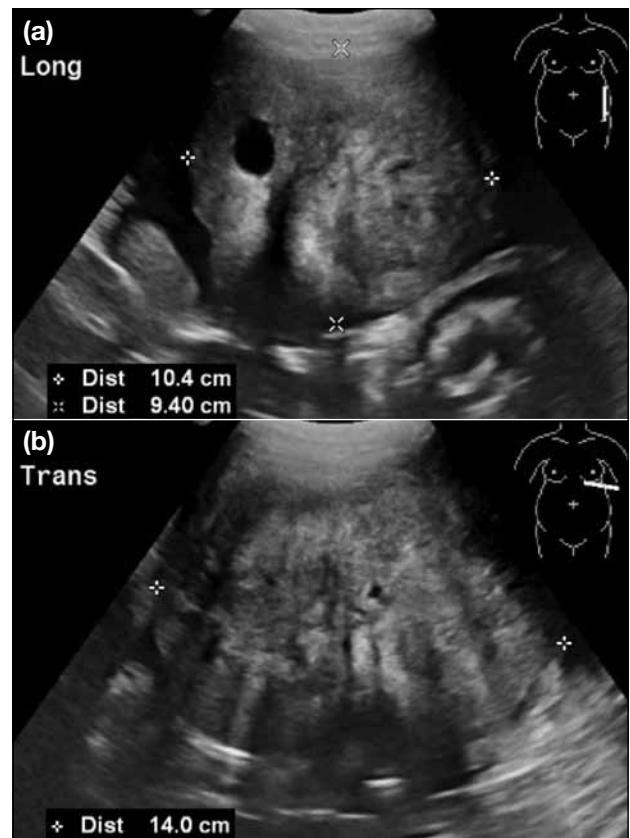
mass with acoustic attenuation and internal cystic change at the left pelvic sidewall (Figure 3). The mass could not be separated entirely from the uterus, but had an acute angle of juncture with the uterus (Figure 4). The appearance of the mass resembled that of a large degenerated uterine fibroid. The left ovary could



**Figure 1.** Transabdominal (a) sagittal and (b) transverse ultrasonograms of the pelvis at 11 weeks of gestation showing the large hypoechoic mass at the left anterior pelvis.



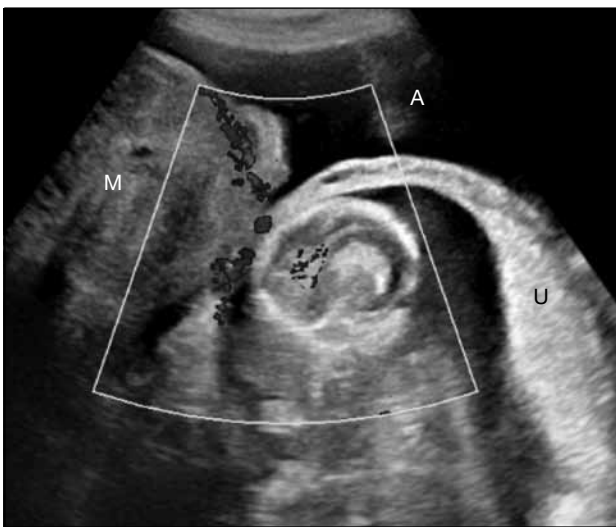**Figure 2.** A transabdominal sagittal ultrasonogram of Morrison's pouch at 17 weeks of gestation depicts gross anechoic ascites (A), liver edge (L), and right kidney (K).



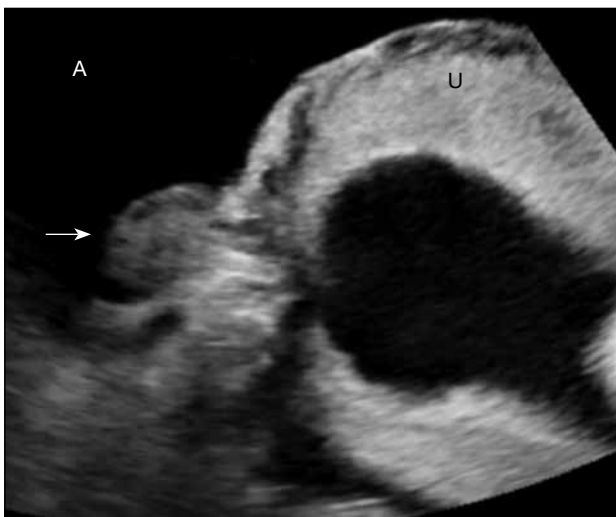
**Figure 3.** Transabdominal (a) sagittal and (b) transverse ultrasonograms at 17 weeks of gestation showing the large heterogeneous left pelvic mass with internal cystic change.

not be depicted, while the right ovary was normal (Figure 5). The foetus was unremarkable with up-to-date foetal parameters. The ascites was so large that the patient required an upright supported position during ultrasonography for easier breathing and, later, abdominal tapping of 2 litres of serous peritoneal fluid was done for relief of her discomfort. Cytology showed atypical cells.

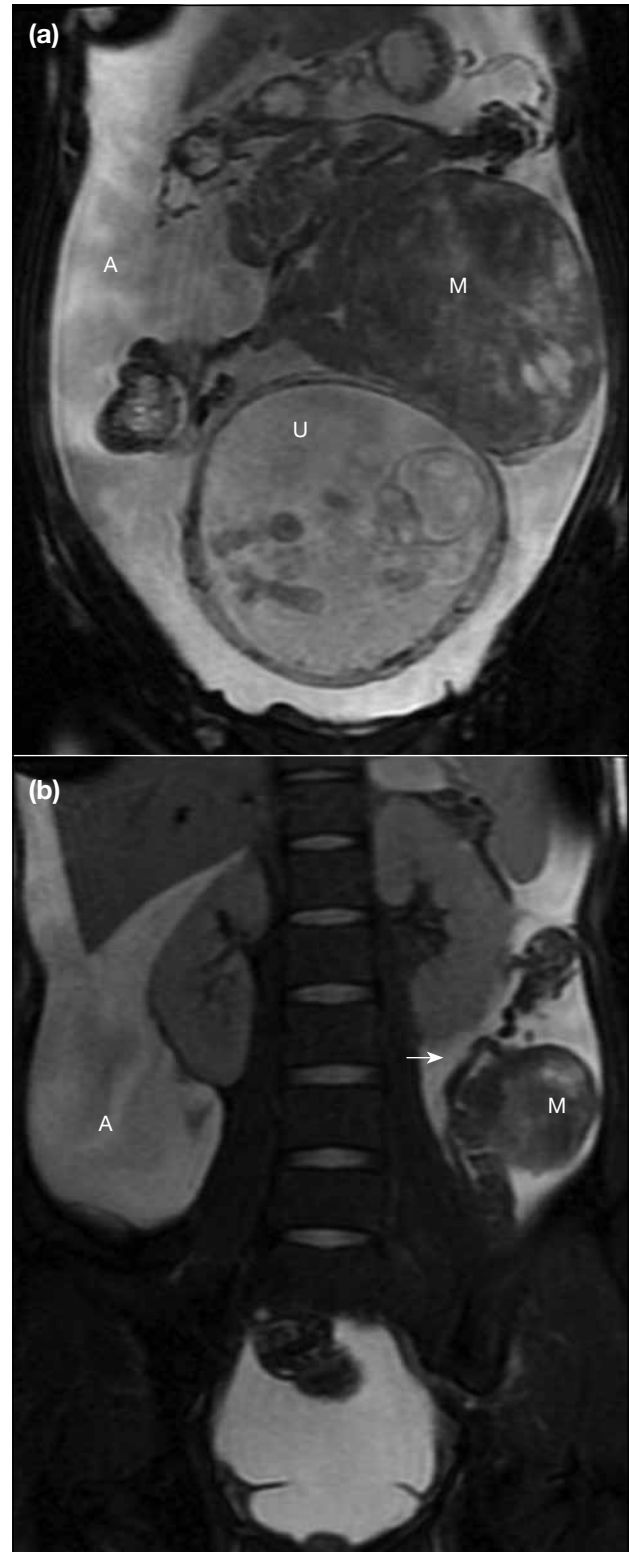
Non-contrast magnetic resonance imaging (MRI) performed 6 days after ultrasonography showed a 14-cm well-circumscribed mass that was iso-hypointense on



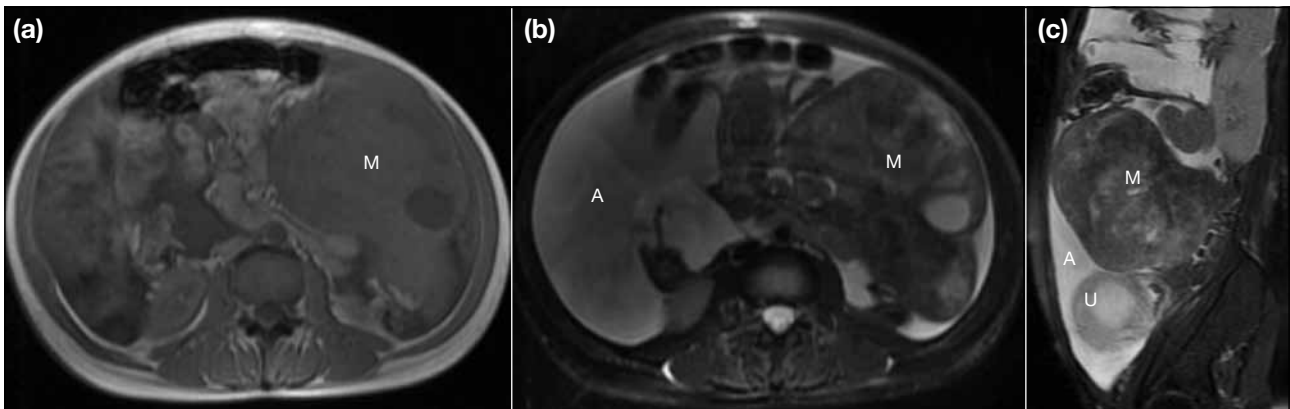
**Figure 4.** A transabdominal Doppler ultrasonogram showing the juncture of the large pelvic mass (M) forming an acute angle with the gravid uterus (U), including part of the foetal crown, and gross ascites (A) in the pelvis.



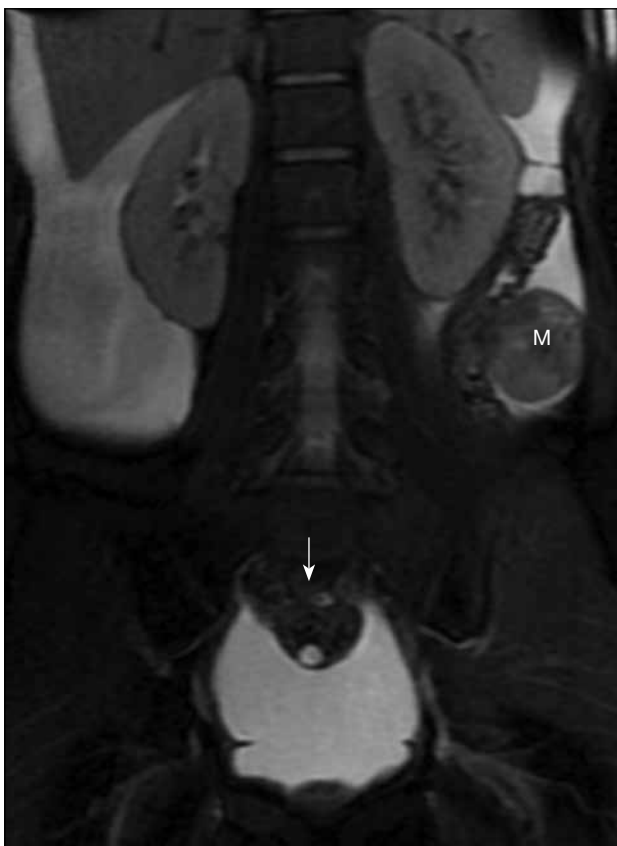**Figure 5.** A transabdominal transverse ultrasonogram showing the normal right ovary (arrow), next to the gravid uterus (U), and gross ascites (A). The left ovary could not be depicted.



**Figure 6.** Coronal T2-weighted magnetic resonance images of the abdomen showing (a) a well-defined mass (M) abutting, but not arising from, the gravid uterus (U), and of predominantly low signal intensity with patchy areas of high signal intensity suggesting cystic change; and (b) the mass (M) connecting to a tubular structure (arrow), which is likely to be the fallopian tubal complex, and gross ascites (A). (Repetition time/echo time, 2200/79.9 ms; field of view, 40 cm; matrix, 288 x 160.)



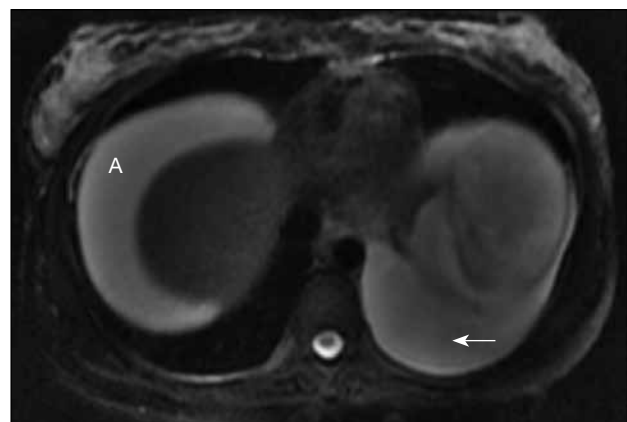
**Figure 7.** (a) Axial T1-weighted; (b) axial T2-weighted; and (c) sagittal T2-weighted magnetic resonance images of the abdomen showing the well-defined mass (M) in the left abdomen as isointense on T1-weighted and hypointense on T2-weighted, with cystic change left of the gravid uterus (U) and gross ascites (A). (Repetition times/echo times, 160/4.2, 2960/78.9, and 2900/80.4 ms, respectively; field of view, 38 cm; axial matrix, 256 x 160; sagittal matrix, 288 x 160.)



**Figure 8.** A coronal T2-weighted magnetic resonance image of the abdomen showing an ovary (arrow) in the midline of the pelvis, posterior to the gravid uterus, which can be traced back to the right adnexa, compatible with a normal right ovary. Part of the mass (M) is also noted at the left side of the lower abdomen. (Repetition time/echo time, 2200/79.9 ms; field of view, 40 cm; matrix, 288 x 160.)

T1-weighted images and hypointense to myometrium with internal cystic changes on T2-weighted images. A thin band of hypointensity on T2-weighted images was seen separating the mass from the uterus. The left ovary was replaced by the mass, compatible with a solid left ovarian mass (Figures 6 and 7). A normal right ovary was seen (Figure 8). In addition to the gross ascites, a moderate amount of left pleural effusion was also seen (Figure 9). Neither peritoneal deposits nor pelvic adenopathy was detected.

Since a malignant neoplasia could not be ruled out given the pelvic mass and sudden development of maternal ascites, an explorative laparotomy was performed



**Figure 9.** An axial T2-weighted magnetic resonance image of the lower thorax at the level of the diaphragm showing a moderate amount of left pleural effusion (arrow) and gross ascites (A) at the subphrenic region. (Repetition time/echo time, 2960/78.9 ms; field of view, 38 cm; matrix, 256 x 160.)

at 18 weeks and 6 days of gestation. Laparotomy revealed a 14-cm solid left ovarian tumour with cystic degeneration, macroscopic features analogous to degeneration of uterine fibroid, and 3 litres of straw-coloured ascites. The uterus was normal. Left salpingo-oophorectomy was done and histology confirmed an ovarian cellular fibroma with necrosis. No malignancy was identified.

A follow-up routine anomaly ultrasonogram was performed at 21 weeks of gestation, 2 weeks after the operation. There was complete resolution of both the ascites and pleural effusion, and an unremarkable foetal scan. Another follow-up ultrasonogram in the third trimester showed normal foetal growth, and persistent resolution of ascites. The subsequent antenatal course remained uneventful and the patient delivered a 3.1-kg healthy boy vaginally at 38 weeks of gestation.

## DISCUSSION

Meigs' syndrome is defined as presence of ascites with hydrothorax in association with benign ovarian tumour, and was named after Joe Vincent Meigs (1892-1963), a Harvard Medical School Professor of Gynecology.<sup>1</sup> Ovarian fibromas are most often seen in association with Meigs' syndrome and account for approximately 4% of all ovarian neoplasms.<sup>2</sup> Other tumours associated with this syndrome include granulosa cell tumours, thecomas, and Brenner tumours.<sup>3</sup> A sine qua non of Meigs' syndrome is disappearance of the effusion and ascites after resection of the ovarian tumour.<sup>4</sup> Pseudo-Meigs' syndrome is a clinically similar rare entity, except that it is characterised by the presence of other pelvic masses.<sup>4,5</sup>

To the authors' knowledge, co-existing Meigs' syndrome and pregnancy is infrequent, and not many reports have been published. Foster<sup>6</sup> reported this association in the literature in 1971 in a pregnant woman of about 18 weeks of gestation who had a 2-cm left ovarian fibroma, ascites, and left pleural effusion. Foster<sup>6</sup> commented that the size of the ovarian fibroma indicated that it antedated the pregnancy even though the ascites and hydrothorax did not become manifest until the pregnancy was well established. This author therefore felt that this was a case of Meigs' syndrome complicated by pregnancy rather than the reverse.<sup>6</sup> This postulation is applicable to this patient, as the left ovarian fibroma had enlarged between the first- and second-trimester ultrasonograms, despite allowing for inter-operator variability. Although there are no consistent data to support the hypothesis,

ovarian fibroma, as with uterine fibroid, may respond to oestrogen and enlarge during pregnancy. The pleural effusion and ascites in this patient manifested later in the pregnancy, several weeks after the initial detection of the ovarian fibroma. These factors seem to concur with Foster's conclusion of Meigs' syndrome complicated by pregnancy, rather than the reverse.

This patient illustrates that MRI may be more sensitive than ultrasonography in establishing the origin of large pelvic masses, especially in the presence of a gravid uterus. The concern would be differentiating ovarian fibroma from a pedunculated uterine fibroid, as the latter was initially suspected based on ultrasonography, and was later proven not to be the case.

The ultrasonographic appearance of ovarian fibroma is variable, but is most commonly seen as a solid hypoechoic mass with sound attenuation.<sup>2</sup> Uterine fibroids typically appear as well-defined solid masses with a whorled appearance on ultrasonography, and are usually of similar echogenicity to the myometrium, but are sometimes hypoechoic.<sup>7</sup> Ovarian fibroma may have cystic degeneration,<sup>2</sup> as seen in this patient. Degenerated fibroids may have a complex appearance with areas of cystic change.<sup>7</sup> Taking into account the similarities in ultrasonographic appearance and the limited field of view on ultrasonography, it may not be easy to differentiate ovarian fibroma from a pedunculated uterine fibroid, particularly when the mass is large. Nevertheless, ultrasonography does have the advantage of real-time scanning with manoeuvres such as assessing attachment of the mass with the adjacent structures by applying gentle pressure and compression to the region of interest. A subserosal uterine fibroid would have been expected to be inseparable from the uterus, while a pedunculated subserosal uterine fibroid would have been able to be moved about the uterine bulk independently via a stalk. In this patient, if the normal left ovary was detected on ultrasonography, which may not be easy in the presence of a gravid uterus, a mass of left ovarian origin would still have remained a consideration.

As ovarian fibroma has a large fibrous component, it can have MRI signal intensities similar to those of a pedunculated fibroid.<sup>5</sup> Typically, fibroids demonstrate very low signal intensity on T2-weighted MRI, and high signal intensity on T2-weighted MRI for cystic degeneration.<sup>2,8</sup> Ovarian fibromas characteristically show low signal intensity on T2-weighted MRI, and

intermediate-to-low signal intensity on T1-weighted MRI.<sup>3</sup> Cystic degeneration can be seen in both ovarian fibroma and uterine fibroid, and would appear as scattered high signal intensity areas on T2-weighted MRI.<sup>2,5</sup> The ability of MRI to depict the normal ovaries, even in the presence of a gravid uterus, would help to determine origin of the pelvic mass. Absence of a normal ipsilateral ovary helps distinguish fibromas from a pedunculated fibroid, as in this patient. The presence of small follicles surrounding the mass also helps identify the ovarian origin of fibromas.<sup>2</sup> On contrast-enhanced MRI, ovarian fibroma exhibits mild enhancement, while uterine fibroid may show either diffuse enhancement on early dynamic images for a cellular type of fibroid or minimal or irregular delayed enhancement for a degenerated fibroid.<sup>3,8</sup> Contrast-enhanced MRI was not performed for this patient because the safety of the contrast agent for the foetus has not yet been proven.

Ascites during pregnancy is a rare event. Aggressive causes in the literature include malignancy of the ovary and abdominal pregnancy.<sup>9,10</sup> The patient reported here had a benign cause of ascites in pregnancy — Meigs' syndrome complicated by pregnancy, with classic spontaneous resolution of ascites after removal of the ovarian fibroma. MRI may offer more accurate assessment of the origin of a large pelvic mass in the presence of a gravid uterus than ultrasonography. However, ultrasonography, with its real-time assessment, ready availability, and lower cost than MRI, remains the primary imaging modality for pelvic examination.

## ACKNOWLEDGEMENTS

We would like to express much gratitude to Dr TC Pun, Consultant, Department of Obstetrics and Gynaecology, Queen Mary Hospital, Hong Kong, for encouragement and permission to report this case; Ms Christina Lam, Senior Radiographer, and Ms Lilian Ngan, Radiographer, Department of Radiology, Queen Mary Hospital/Tsan Yuk Hospital, Hong Kong, for providing the images in the manuscript.

## REFERENCES

1. Lurie S. Meigs' syndrome: the history of the eponym. *Eur J Obstet Gynecol Reprod Biol.* 2000;92:199-204. [crossref](#)
2. Jeong YY, Outwater EK, Kang HK. Imaging evaluation of ovarian masses. *Radiographics.* 2000;20:1445-70.
3. Shanbhogue AK, Shanbhogue DK, Prasad SR, Surabhi VR, Fasih N, Menias CO. Clinical syndromes associated with ovarian neoplasms: a comprehensive review. *Radiographics.* 2010;30:903-19. [crossref](#)
4. O'Flanagan SJ, Tighe BF, Egan TJ, Delaney PV. Meigs' syndrome and pseudo-Meigs' syndrome. *J R Soc Med.* 1987;80:252-3.
5. Chourmouzi D, Papadopoulou E, Drevelegas A. Magnetic resonance imaging findings in pseudo-Meigs' syndrome associated with a large uterine leiomyoma: a case report. *J Med Case Rep.* 2010;4:120. [crossref](#)
6. Foster HW. Meigs' syndrome complicated by pregnancy. *J Natl Med Assoc.* 1971;63:372-3.
7. Wilde S, Scott-Barrett S. Radiological appearances of uterine fibroids. *Indian J Radiol Imaging.* 2009;19:222-31. [crossref](#)
8. Murase E, Siegelman ES, Outwater EK, Perez-Jaffe LA, Tureck RW. Uterine leiomyomas: histopathologic features, MR imaging findings, differential diagnosis, and treatment. *Radiographics.* 1999;19:1179-97.
9. Behtash N, Karimi Zarchi M, Modares Gilani M, Ghaemmaghani F, Mousavi A, Ghotbizadeh F. Ovarian carcinoma associated with pregnancy: a clinicopathologic analysis of 23 cases and review of the literature. *BMC Pregnancy Childbirth.* 2008;8:3. [crossref](#)
10. Ross JA, Hackett E, Lawton F, Jurkovic D. Massive ascites due to abdominal pregnancy. *Hum Reprod.* 1997;12:390-1. [crossref](#)