

---

---

## CASE REPORT

---

---

# Aorto-esophageal Fistula Complicating Thoracic Aorta Stent-graft Placement

JCM Sitt, BK Paunipagar, DD Rasalkar

Department of Imaging and Interventional Radiology, The Chinese University of Hong Kong, Prince of Wales Hospital, Shatin, Hong Kong

### ABSTRACT

*This report is of a 75-year-old man with aorto-esophageal fistula complicating aortic stent-graft placement for ruptured thoracic aneurysm. The clinical presentation, pathophysiology, imaging features, and treatment options of this condition are discussed. High clinical suspicion correlated with clinical features (massive haematemesis, new-onset fever, and raised inflammatory markers) and use of computed tomography and endoscopy are crucial for prompt diagnosis.*

*Key Words: Aortic aneurysm, thoracic; Digestive system fistula; Stents*

## 中文摘要

### 主動脈食管瘻合併胸主動脈覆膜支架置入

薛靜雯、BK Paunipagar、DD Rasalkar

本文報告一名75歲男子患有主動脈食管瘻合併因胸部動脈瘤破裂的主動脈覆膜支架置入。本文討論了其臨床表現、病理學、影像學特徵，以及該指徵的治療方案。保持對該病相關臨床症狀的高度警惕性（劇烈嘔血、突發高熱及炎症標誌物升高）及運用電腦斷層掃描、內窺鏡技術對及時診斷至為重要。

### INTRODUCTION

Aorto-esophageal fistula (AEF) is a rare complication of thoracic aortic stent-graft placement and should always be suspected in patients who have undergone thoracic aortic graft surgery / stenting and present with gastrointestinal haemorrhage. High clinical suspicion correlated with clinical features (massive haematemesis, new-onset fever, and raised inflammatory markers) and use of computed tomography (CT) and endoscopy are crucial for prompt diagnosis.

### CASE REPORT

A 75-year-old man with hypertension and diabetes mellitus presented to a hospital in mainland China in January 2011 with retrosternal chest pain. Emergency CT of the thorax showed a saccular aneurysm at the inferior aspect of the aortic arch (8.0 x 4.5 x 7.0 cm), with adjacent mediastinal haematoma and massive left pleural haemorrhagic effusion. The aorta also showed extensive background atherosclerotic change and an infrarenal aortic dissection with a thrombosed false

---

---

*Correspondence: Dr BK Paunipagar, Department of Imaging and Interventional Radiology, The Chinese University of Hong Kong, Prince of Wales Hospital, Shatin, Hong Kong.  
Tel: (852) 2632 1069; Email: drbhawan@yahoo.com*

Submitted: 28 Nov 2011; Accepted: 6 Mar 2012.

lumen. A small beak-shaped contrast leak was noted at the posterior aspect of the aneurysm. The patient was immediately transferred to the Prince of Wales Hospital, Hong Kong, for further management.

Urgent ascending thoracic aortogram confirmed the presence of a saccular aneurysm arising from the arch, with the proximal end at the root of the left common carotid artery. Carotid-carotid bypass graft, embolisation of the left subclavian artery, and ligation of the left common carotid artery were performed, and two Zenith stent grafts (28 x 200 mm and 30 x 140 mm) were placed across the aneurysm from the root of the brachiocephalic artery to the descending aorta. Post-procedure digital subtraction angiography showed no contrast leakage.

The patient's condition was stabilised and he was transferred to a convalescent hospital for rehabilitation. However, his condition was further complicated by right foot gangrene, secondary to bacterial infection, and bilateral knee arthroplasty was performed 4 months later. Shortly after operation, the patient developed hypovolaemic shock and upper gastrointestinal bleeding. Oesophagoduodenoscopy was performed twice which only revealed old blood clots in the oesophagus. A subsequent CT of the thorax demonstrated a 3-mm defect at the left lateral wall of the upper oesophagus, and an air-filled tract extending towards and terminating at the metallic stent at the posteroinferior aspect of the aortic arch (Figure), confirming the AEF. No active contrast extravasation was identified. The patient developed rebleeding and hypovolaemic shock, and died 2 days after the CT scan.

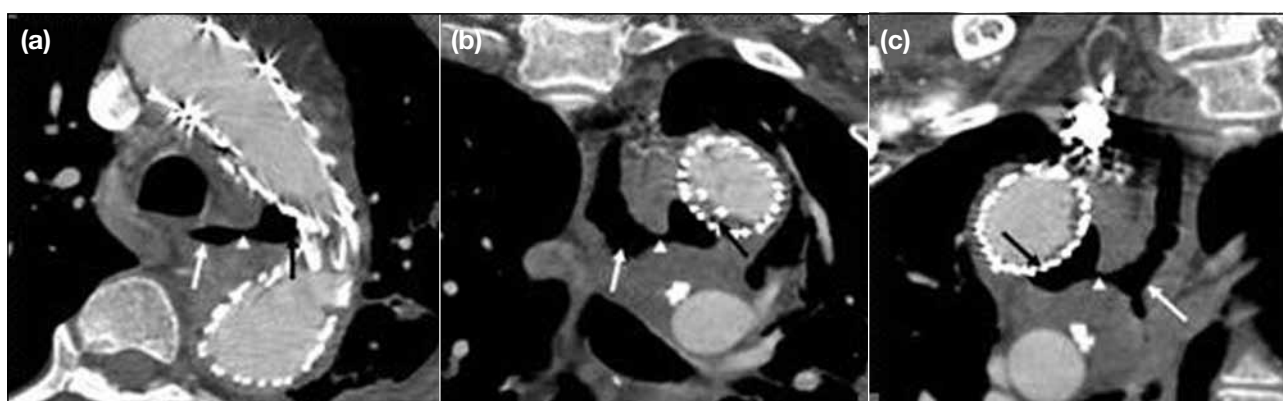
## DISCUSSION

The first case of AEF was described by Dubreuil in 1818.<sup>1</sup> AEF accounts for approximately 10% of all aortoenteric fistulas, and thoracic aneurysms are the commonest cause. Other common causes include bronchial and oesophageal neoplasms and ingestion of foreign objects.<sup>2</sup>

Secondary AEF is a rare, but known, sequela of stent-graft aortic aneurysm repair, and is a cause of massive fatal gastrointestinal bleeding. AEF has been a well-known complication of open surgical repair of thoracic aneurysms and dissections.<sup>3</sup> In recent years, AEF has also been increasingly associated with endovascular stenting of the thoracic aorta (reported incidence of 1.9%), as this method has been adopted as a less-invasive treatment for patients who are unfit for conventional open surgery.<sup>4</sup>

The exact pathophysiology of formation of a secondary AEF is still unknown. Hypotheses include direct erosion of the graft through the aorta into the oesophagus, formation of a false aneurysm after aortic wall trauma, pressure necrosis onto the oesophageal wall by self-expanding stents or misaligned rigid stents, occlusion of aortic side branches supplying the oesophagus leading to ischaemic oesophageal necrosis, infection of the stent-graft leading to wall erosion, and endoleak into the residual aneurysm sac.<sup>4</sup> Bleeding sources directly from the aorta, oesophageal vessels, and aortic vasa vasorum have been proposed.<sup>5</sup>

AEF was described by Chiari in 1914<sup>6</sup> as a triad of dysphagia / mid-thoracic pain, a short symptom-



**Figure.** Computed tomography aortograms: (a) axial, (b) coronal, and (c) sagittal images showing a thin fistulous tract (white arrowheads) from the oesophagus (white arrows) extending to and abutting the metallic stent-graft (black arrows) within the aortic arch.

free period of hours or days, and subsequent fatal haematemesis. Initial mid-thoracic pain can be caused by erosion, distension, or local dissection of the aortic wall. Spontaneous cessation of the herald haemorrhage may be explained by temporary occlusion of the fistula due to arterial wall spasm, hypotension, or a periaortic haematoma occluding the fistula. This may be detected as a blood clot along the oesophageal wall on oesophagogastroduodenoscopy (OGD).<sup>2</sup> The haematoma is then digested by infection or gastrointestinal contents, resulting in the final fatal exsanguination. In an autopsy review of 24 patients with AEF by Carter et al,<sup>7</sup> 80% had a sentinel haemorrhage prior to fatal exsanguination. AEF has also been reported to be accompanied by elevated inflammatory markers and new-onset fever, which may precede the rupture of the aorta into the oesophagus.<sup>4</sup>

Secondary AEF usually occurs in relatively early post-stenting period (range, 1-16 months; median, 2.4 months), but has been reported to occur up to 2 years after the procedure.<sup>5,8</sup> For this patient, the secondary AEF was diagnosed 4.5 months post-stenting. Although this condition has already been reported in the literature, it is regarded as a rare event. AEF is therefore often 'forgotten' by clinicians when they encounter patients presenting with gastrointestinal bleeding post-stenting, especially when the patient has not been cared for by the treating team; clinicians with little experience in stenting procedures may not be familiar with the potential complications. A delayed diagnosis leads to degradation of the patient's condition, with potential medico-legal consequences. This patient was initially investigated extensively for gastrointestinal bleeding, with upper endoscopy performed twice. Although old blood clots were noted in the oesophagus, this was regarded as a non-specific finding. When the patient later developed sepsis and loculated pleural effusions, CT of the thorax subsequently picked up the fatal complication. This patient illustrates the importance of a vigilant radiologist who should bear this rare, but important, diagnosis in mind, as it may help to alert the referring clinicians by considering this differential diagnosis early.

AEF should therefore always be suspected in patients who have undergone thoracic aortic stent-grafting and present with gastrointestinal haemorrhage. A combination of endoscopy and a prompt CT scan offers the best chance of detecting a fistula.<sup>9</sup> CT aortogram characteristically shows a new heterogeneous mass between the descending thoracic aorta and the

oesophagus, with or without air entrapment.<sup>4</sup> In certain cases, CT aortogram only demonstrates the residual aneurysm or stent-graft, but not the fistula tract because of blood clots and lack of bleeding at the time of examination. An abdominal aortogram should also be performed, as many patients also have simultaneous abdominal aneurysms.<sup>2</sup> Although the use of an oesophagogram has been described,<sup>10</sup> it is generally not recommended if AEF is already suspected.

OGD findings may range from mild erosive lesions along the oesophageal wall through a bluish polypoid lesion suggestive of an intramural haematoma or a pulsating submucosal mass to a large fistula opening with a clear view into the stent graft.<sup>2,4,11</sup> In particular, AEF should be suspected in patients with massive haematemesis if the OGD shows an insignificant amount of blood in the stomach and when no definite bleeding source can be identified.

Regarding device-specific outcomes among the various brands of stent grafts, at the time of reporting there is no publication that compares the risk of developing AEF among the various types of devices. Comparison of outcomes remains difficult as there are few comparative and no randomised studies in the literature. The decisions for treatment and selection of stents depend not only on patients' premorbid status and anatomical criteria, but also on commitment to clinical trials.<sup>12</sup> For unfavourable outcomes other than AEF (e.g. stroke, paraplegia, aneurysm rupture during the procedure), it appears that patients with favourable anatomy have good outcomes with most modern endografts. Patients with more challenging anatomies may benefit from a particular design.<sup>13</sup> However, as each stent graft has its disadvantages, no single type can be identified as the best.<sup>14</sup> At present, the long-term durability of currently available stent-graft systems is lacking, and the effects of material fatigue are still of concern both to surgeons and to radiologists.<sup>15</sup>

Although there has been one report describing successful conservative management to control rebleeding and prevent chronic mediastinitis,<sup>16</sup> this reported a single case only, and it is generally recognised that untreated cases are invariably fatal. Equally, conservative management has been reported to be unsuccessful. Embolisation of the AEF may be adopted as a bridge to definitive surgery. Use of stent grafts for treatment of secondary AEF is now being explored, but conclusive data are still lacking. The current literature supports the

use of more aggressive surgical treatments, including oesophageal resection, debridement, and aortic graft interposition as the definitive treatment, providing the best chance of survival.<sup>2,8,17,18</sup> Nevertheless, operative management of AEF is associated with considerable mortality and is frequently complicated by mediastinitis, sepsis, and haemorrhage<sup>3</sup>; aggressive treatment is withheld for many patients because of their poor general health status and comorbidities. Therapeutic options are therefore generally limited and mortality remains high. At present, surgical repair, rather than repeat endovascular repair, remains the mainstay of treatment.<sup>5,17</sup>

## REFERENCES

1. Dubreuil O. Observations sur la perforation de l'oesophage et de l'aorte thoracique par une portion d'os avale: avec de reflexions. *J Univ Sci Med.* 1818;9:357-63.
2. Amin S, Luketich J, Wald A. Aortoesophageal fistula: case report and review of literature. *Dig Dis Sci.* 1998;43:1665-71. [cross ref](#)
3. Isasti G, Gó mez-Doblas J, Olalla E. Aortoesophageal fistula: an uncommon complication after stent graft repair of an aortic thoracic aneurysm. *Interact Cardiovasc Thorac Surg.* 2009;9:683-4. [cross ref](#)
4. Eggebrecht H, Mehta RH, Dechene A, Tsagakis K, Kuhl H, Huptas S, et al. Aortoesophageal fistula after thoracic aortic stent-graft placement: a rare but catastrophic complication of a novel emerging technique. *JACC Cardiovasc Interv.* 2009;2:570-6. [cross ref](#)
5. Sager HB, Wellhöner P, Wermelt JA, Schunkert H, Kurowski V. Lethal hemorrhage caused by aortoesophageal fistula secondary to stent-graft repair of the thoracic aorta. *Cardiovasc Intervent Radiol.* 2011;34 Suppl 2:S60-3. [cross ref](#)
6. Chiari H. Ueber fremdkorperverletzung des oesophagus mit aortenperforation. *Berlin Klin Wschr.* 1914;51:7-9.
7. Carter R, Mulder GA, Synder EN Jr, Brewer LA 3rd. Aortoesophageal fistula. *Am J Surg.* 1978;136:26-30. [cross ref](#)
8. Engelhardt H, Paul A, Niebel W, Dechêne A, Przyborek M, Tsagakis K, et al. Successful treatment of secondary aortoesophageal fistula after thoracic endovascular aortic repair [in German]. *Dtsch Med Wochenschr.* 2010;135:2076-80. [cross ref](#)
9. Gourtosoyiannis N, Papanikolaou N, Daskalogiannaki M. The duodenum and small intestine. In: Adam A, Dixon A K, Grainger R G, Allison D J, editors. *Diagnostic radiology.* Philadelphia: Elsevier Churchill Livingstone; 2008. p 659.
10. Naschitz JE, Bassan H, Lazarov N, Grishkan A. Upper gastrointestinal bleeding, aneurismatic dilatation of the thoracic aorta and filling defect on the esophagogram: a diagnostic triad suggesting aorto-esophageal fistula. *Radiologe.* 1982;22:283-5.
11. Santo KC, Guest P, McCafferty I, Bonser RS. Aortoesophageal fistula secondary to stent-graft repair of the thoracic aorta after previous surgical coarctation repair. *J Thorac Cardiovasc Surg.* 2007;134:1585-6. [cross ref](#)
12. Nevelsteen A, Maleux G. Endovascular abdominal aortic aneurysm treatment: device-specific outcomes. *J Cardiovasc Surg (Torino).* 2004;45:307-19.
13. Bastos Goncalves F, Rouwet Ellen V, Metz R, Hendriks JM, Vrancken Peeters M, Muhs BE, et al. Device-specific outcomes after endovascular abdominal aortic aneurysm repair. *J Cardiovasc Surg (Torino).* 2010;51:515-31.
14. Gawenda M, Brunkwall J. Device-specific outcomes with endografts for thoracic aortic aneurysms. *J Cardiovasc Surg (Torino).* 2005;46:113-20.
15. Thurnher SA, Grabenwöger M. Endovascular treatment of thoracic aortic aneurysms: a review. *Eur Radiol.* 2002;12:1370-87. [cross ref](#)
16. Kasai K, Ushio A, Tamura Y, Sawara K, Kasai Y, Oikawa K, et al. Conservative treatment of an aortoesophageal fistula after endovascular stent grafting for a thoracic aortic aneurysm. *Med Sci Monit.* 2011;17:CS39-42. [cross ref](#)
17. Czerny M, Zimpfer D, Fleck T, Gottardi R, Cejna M, Schoder M, et al. Successful treatment of an aortoesophageal fistula after emergency endovascular thoracic aortic stent-graft placement. *Ann Thorac Surg.* 2005;80:1117-20. [cross ref](#)
18. Topel I, Stehr A, Steinbauer MG, Piso P, Schlitt HJ, Kasprzak PM. Surgical strategy in aortoesophageal fistulae: endovascular stentgrafts and in situ repair of the aorta with cryopreserved homografts. *Ann Surg.* 2007;246:853-9. [cross ref](#)