

Outcomes of Patients with No Calcium Yield in Stereotactic-guided Breast Biopsy for Microcalcifications: Ten-year Experience

KML Wong¹, CY Lui², HS Lam²

¹Department of Radiology and Organ Imaging, United Christian Hospital, Kwun Tong, Kowloon, Hong Kong;

²Department of Radiology, Kwong Wah Hospital, 25 Waterloo Road, Kowloon, Hong Kong

ABSTRACT

Objectives: To look at the outcomes of patients who underwent stereotactic-guided breast biopsy for microcalcifications without specimen yielding calcium, so as to facilitate management.

Methods: In this retrospective study, records of all patients who underwent stereotactic-guided breast biopsy for microcalcifications from 2001 to 2010 in the Department of Radiology, Kwong Wah Hospital, were reviewed. Information including radiological grading, pathology, and outcomes in those without calcium in their specimen was retrieved.

Results: In all, 2028 stereotactic-guided biopsies for microcalcifications were performed in the relevant period. The number of biopsy specimens with radiography showing calcium was 60 (3%), whereas 32 (53%) of the latter specimens also yielded no calcium when examined pathologically. Regarding these patient specimens without calcification, pathologically 4 (13%) showed malignancy, 2 (6%) showed atypical ductal hyperplasia, 23 (72%) showed a benign pathology, and 3 (9%) were reported as specimen insufficient. The six patients with biopsy showing malignancy or atypical ductal hyperplasia underwent surgery. Regarding the 23 patients with benign pathology, 10 had microcalcifications radiologically graded as R2 (probably benign), 6 were of R3 (indeterminate) grade, and 7 were of R2-3 grade. Two patients graded R3 had surgery that yielded malignant pathology. Among patients with insufficient specimens, one had R2 microcalcifications and two were graded R3; one of the latter had surgery that yielded malignancy. For the remaining 23 patients, they either had follow-up mammograms establishing stability, or surgical excision or repeat biopsy showing benign pathology. False-negative rate in R3 group without specimen calcification was high (38%).

Conclusion: For R3 (indeterminate) microcalcifications without specimen yielding calcium in the stereotactic biopsy, repeat biopsy is advised even if the initial pathology appears benign. For R2 and R2-3 microcalcifications without specimen yielding calcium, follow-up mammography is advised.

Key Words: Biopsy; Breast neoplasms; Calcinoses; Female; Mammography

中文摘要

立體定向引導下乳腺活檢微小鈣化的檢查中病人無鈣化的結果： 十年工作經驗分享

黃嘉敏、呂振英、林漢城

目的：探討接受立體定向引導下乳腺活檢微小鈣化病變但標本無鈣化的病人結果，以幫助病人

Correspondence: Dr KML Wong, Department of Radiology and Organ Imaging, Basement 1, Main Block, United Christian Hospital, Kwun Tong, Kowloon, Hong Kong.

Tel: (852) 3513 4156; Fax: (852) 2635 0692; Email: wkm306@ha.org.hk

Submitted: 27 Dec 2012; Accepted: 4 Jun 2013.

治療。

方法：回顧研究2001至2010年期間在廣華醫院放射科，所有接受立體定向引導下乳腺活檢微小鈣化的患者紀錄。從中篩取標本中無鈣化的患者紀錄，並找出其放射學等級、病理和結果。

結果：研究期間共有2028個立體定向引導下乳腺活檢微小鈣化病變的標本。X光檢查過的標本中60例（3%）有鈣化，其中32例（53%）病理結果無鈣化。在這些無鈣化的標本中，病理學結果顯示惡性腫瘤有4例（13%）、導管非典型增生2例（6%）、良性病變23例（72%）、標本不足3例（9%）。6例惡性腫瘤和導管非典型增生的患者接受手術治療。23例良性病變中，經影像學證實出現微小鈣化而屬R2級別（可能良性）的有10例，屬R3級別（不確定）的有6例，屬R2-3級別的有7例。兩名R3級別的患者接受手術後發現有惡性腫瘤。標本不足的患者中，1例有R2級微小鈣化，2例有R3級，其中一例R3級手術發現為惡性腫瘤。其餘23名患者中，部份有跟進乳房X線攝影檢查以確定其穩定性，或者進行手術切除或重複活檢以確定為良性病變。沒有標本鈣化的R3級別的假陰性率偏高（38%）。

結論：對於微小鈣化屬R3級別（不確定）但立體定向活檢標本中無鈣化的病例來說，即使最初病理學結果呈良性，仍建議重複活檢。至於微鈣化屬R2和R2-3級別但標本中無鈣化的病例，則建議作乳房攝影X線檢查隨訪。

INTRODUCTION

Since its introduction by Parker et al in 1990,¹ stereotactic-guided breast biopsy has become the main method for biopsy of non-palpable breast lesion. It has been reported to be a reasonably accurate, non-invasive investigation.²⁻⁸ The failure rate of retrieving targeted non-palpable breast lesions varies from 2 to 21%.⁹⁻¹³ Optimal results for core biopsy of breast microcalcifications can be achieved with the use of 14G core biopsy needles, an increase in the number of core biopsy specimens obtained from any given lesion, and with increased experience with the procedure.^{2,3,6,14}

The objective of our study was to retrospectively determine the outcome of patients who underwent stereotactic-guided breast biopsy in the Department of Radiology, Kwong Wah Hospital, Hong Kong, in search of microcalcifications, but with the absence of calcium in the biopsied specimens. In addition, we aimed to provide recommendations on the appropriate management on this group of patients.

METHODS

Retrospective review of the electronic records of all patients who underwent stereotactic-guided core biopsy for breast microcalcifications in the Department of Radiology, Kwong Wah Hospital between January 2001 and December 2010 was performed. Biopsies for breast density and architectural distortion were excluded. Those with biopsies performed in search of

breast microcalcifications but without calcium in their specimens were included in this study. Information including radiological grading of the mammogram based on the National Screening System, UK (R1: normal / definitely benign; R2: probably benign; R3: indeterminate; R4: probably malignant; R5: malignant), technical factors of the biopsy, pathology, and the outcomes of patients were analysed.

The lesions were biopsied on a dedicated stereotactic prone biopsy table using a digital imaging system (Lorad, Danbury, USA). In challenging cases where the target microcalcifications were too faint or too posteriorly situated, lesions were biopsied on erect table (StereoLoc, Hologic, USA) instead. Core biopsies were performed with a 14G long-throw (22- or 25-mm excursion) automatic biopsy needle and gun (ProMag 2.2 or 2.5; Manan Medical Systems, Northbrook, USA) or 14G short-throw (14-mm excursion) automatic biopsy needle and gun (ProMag 1.4).

Biopsied tissues underwent immediate radiography to detect the presence of calcium. If the specimen appeared radiographically negative for calcium, the corresponding pathological report was reviewed for the presence of calcium. For cases with negative specimen calcium after pathological examination, the radiological grading of the targeted microcalcifications, technical factors about the core biopsy, and specimen pathology were discussed in a joint mammography meeting to

reach a final decision on subsequent management, such as repeat biopsy, surgery, or follow-up mammogram. The follow-up period ranged from 1.5 to 11.5 years.

RESULTS

The total number of stereotactic-guided biopsies for breast microcalcifications during the 10-year study period (2001 to 2010) was 2028. The number of biopsy specimens without radiographically detected calcium was 60 (3%). During the study period, there was a significant rise in number of stereotactic-guided core biopsies in search of breast microcalcifications in

Kwong Wah Hospital (Figure 1), along with a reduced failure rate for the retrieval of breast microcalcifications (Figure 2).

Regarding the 60 patients without radiographically detected calcium in their specimens, their mean and median ages were 49 (range, 36-60) years. The radiological grading of the targeted microcalcifications ranged from R2 to R3; 29 were classified as R2 (probably benign), 12 as R2-3, and 19 cases as R3 (indeterminate). All core biopsies were performed with a 14G needle, but the number of cores obtained from each patient showed diversity, varying from 2 to 30 (Table 1). The duration of the procedure ranged from 3 to 150 (mean, 65) minutes. The breast thicknesses ranged from 15 to 64 (mean, 34) mm. In all, 54 (90%) of the patients had the procedure on the prone table, while 6 (10%) had it performed on the erect table.

The results of pathological examination were reviewed for specimens reported as radiographically negative for calcium. Notably, 32 (53%) of the patients had no calcium detected even after pathological examination of their specimens, whereas it was detected in the remaining 28 specimens. The latter group was considered to have microcalcifications which were too faint to be detected by radiography. Regarding the 32 patient specimens devoid of calcium by radiography and pathological examination, 23 (72%) had a benign pathology, 4 (13%) showed malignancy, 3 (9%) were reported as specimen insufficient, and 2 (6%) had atypical ductal hyperplasia (Table 2).

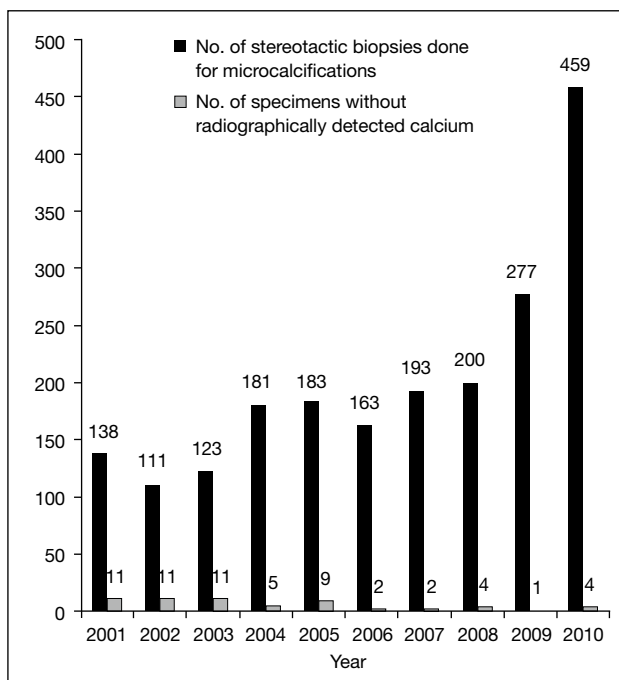


Figure 1. The number of cases biopsied in 2001 to 2010 and the number with specimens radiographically negative for calcium.

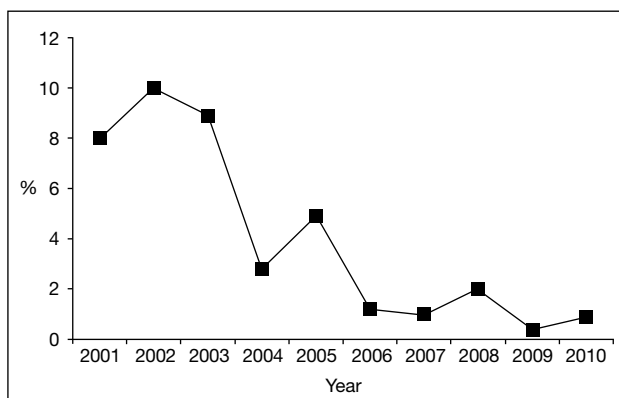


Figure 2. The percentage of specimens without radiographically detected calcium in 2001 to 2010.

Table 1. Number of core biopsies obtained in the 60 patients with absence of specimen radiograph calcium.

No. of specimens	No. of patients (n=60)
2	1
3	1
5	9
6	8
8	4
9	7
10	6
11	3
14	2
15	7
16	2
18	2
20	3
25	2
26	1
27	1
30	1

Table 2. Pathology of the 32 patients with specimens negative for calcium.

Pathology of initial stereotactic biopsy	Final pathology indicated by repeat biopsy or surgery	No. of patients
Malignancy or atypical ductal hyperplasia	Invasive ductal cancer	2
	Intraductal cancer	2
	Atypical ductal hyperplasia	2
Benign	Fibrocystic change	8
	Atrophy	1
	Fibrosis	1
	No malignancy	13
Insufficient	-	3

Table 3. R category and outcomes of the 32 patients with specimens negative for calcium.

Pathology of initial stereotactic biopsy	Radiological grading	Management plan and outcome	No. of patients
Malignancy or atypical ductal hyperplasia	R2	Surgery confirming malignancy	2
	R3	Surgery confirming malignancy or showing upgrade in cases initially diagnosed with atypical ductal hyperplasia	4
Benign	R2	Follow up-mammography: static	9
		Re-biopsy: normal, specimen negative for calcium	1
	R2-3	Follow-up mammography: static	6
		Surgery showing fibrocystic change	1
	R3	Follow-up mammography, followed by surgery, showing malignancy	2
		Follow-up mammography: static	1
		Re-biopsy: no malignancy, specimen positive for calcium	2
Insufficient	R2	Inframammary-fold microcalcifications	1
		Follow-up mammography: static	1
	R3	Follow-up mammography, followed by surgery, showing malignancy	1
		Re-biopsy: normal, specimen negative for calcium	1

Surgery was performed on the six patients with malignancy or atypical ductal hyperplasia; the final pathology confirmed the presence of cancer in four and ductal cancer in the two with atypical ductal hyperplasia. In the 23 patient specimens reported as having benign pathology, mammography showed 10 (43%) were of R2 grade, 7 (30%) were of R2-3 grade, and 6 (26%) were of R3 grade. Further management plans were decided in the joint mammogram meeting, where the clinical histories, features of microcalcifications in the mammograms, and technical aspects of the stereotactic biopsy were taken into account. Of the 10 patients in the R2 group, nine had microcalcifications at followed up mammography; the appearance of which remained static. The remaining patient had a repeat biopsy showing normal pathology that was also negative for calcium. In the R2-3 category, 6 out of 7 patients had follow-up mammography showing static microcalcifications over at least 4 years. The remaining patient in this group had surgery because of fibrocystic change. The management plans and outcomes of the six patients with the R3-categorised specimens were as follows: two had repeat biopsies

showing no malignancy and were positive for calcium; three had follow-up mammograms done, two of whom subsequently underwent surgery (based on a radiology report) and both yielded invasive ductal cancer. The third patient had static microcalcifications noted in a follow-up mammogram. The remaining patient in this group had no repeat biopsy or mammography as the microcalcifications were located at the inframammary fold and upon review considered to be in the skin. There were three patients with no calcium detected after mammography in whom the initial stereotactic biopsy yielded insufficient tissue for pathology. One of these had been categorised as R2 and the follow-up mammogram was static. The other two patients were of R3; one of them had surgery (suggested by the reporting radiologist based on the follow-up mammogram) and turned out to have intraductal cancer. The other had a repeat biopsy yielding normal pathology devoid of calcium (Table 3).

In summary, of the 32 patients with specimens that were radiographically and pathologically calcium-negative specimen out of the 2028 stereotactic breast biopsies for

microcalcifications in the 10-year study period, eight (25%) had repeat biopsies or surgery. The remaining 24 (75%) of these patients (with no repeat biopsy or surgery) were followed up for 1.5 to 11.5 years. None of these patients had malignant breast pathology diagnosed during their follow-up. Of the eight patients who had repeat biopsies or surgery finally, three had a malignant pathology, all of whom had R3 breast microcalcifications. The false-negative rate in patients with R3 mammograms and negative specimen for calcium was 38%.

DISCUSSION

Breast microcalcifications are found incidentally during screening of asymptomatic patients or are associated with other abnormalities in patients with symptoms. While some microcalcifications show typical shapes and distributions suggesting their benign or malignant nature, the remainder show non-specific features and create diagnostic problems for radiologists. Radiologists are responsible for categorising microcalcifications according to the risk of malignancy so as to provide directions on management plans. During the study period, we categorised microcalcifications with regard to the National Screening System, UK — R2 (probably benign) is equivalent to Breast Imaging Reporting and Data Systems (BIRADS) category 3 (probably benign) while R3 (indeterminate) is equivalent to BIRADS category 4 (suspicious abnormality). Since non-specific microcalcifications have an overall malignancy rate of 22-37%,¹⁵⁻¹⁸ further biopsy and histological evaluation appears mandatory.

Stereotactic-guided core biopsy offers several advantages over fine-needle aspiration cytology, which had been frequently used in the past. For core biopsy, it is rare for specimens to be insufficient due to the larger-bore needle used. Such needles enable more complete characterisation of the target lesions by pathologists,¹⁹ and differentiation of intraductal from invasive carcinoma. With core biopsy, the interpretation can be rendered by pathologists who do not have special training in cytopathology.

Studies in the United States in the 1990s showed that the sensitivities and specificities of stereotactic-guided core biopsy of non-palpable breast lesions ranged from 70-100% and 85-100%, respectively.²⁰⁻²⁴ To minimise the chance of sampling error in stereotactic biopsy, taking an immediate specimen radiograph to assure the presence of calcium is a routine practice in our hospital.

Studies have shown that the presence of calcium on specimen radiographs significantly increases the chance that a histopathological diagnosis will be made.²⁵⁻³⁷ It also assists the pathologist in choosing tissue samples for histological evaluation if multiple cores are obtained.³⁸ On the other hand, our study shows that a radiograph is not sensitive enough in detecting specimen microcalcifications, causing a high false-negative rate of 47%. This is especially true for microcalcifications that are faint in density to begin with. Another reason is that the microcalcifications are shattered during the machine gun-assisted core biopsy. Other factors associated with unsuccessful calcification retrieval include significant bleeding, patient movement, use of short-throw needles limited by a thin breast and technical error.³⁹

As there is a large discrepancy between specimen radiographs and pathological examination in detecting calcium, we recommend reviewing all pathological reports for presence of calcium in cases with negative specimen for calcium in radiographs. The microscopic foci of calcifications that are below the resolution of radiography could be detected histologically. Cases with specimens negative for calcium on radiographs but positive for calcium on pathological examination should be considered positive for calcium in the target lesion.

The percentage of specimens radiographically negative for calcium decreased from up to 10% in the earlier years of the study to less than 1% near the end. Given that the same machine had been used on all specimens, this reflects an overall improvement in the performance of biopsies in our unit. This is likely related to building of expertise of our breast team, together with continuous training, regular auditing, and employment of special techniques such as drop shoulder, rolling, and air gap manoeuvres. The overall percentage of specimens radiographically negative for calcium in the 10-year study period was 3%, which is much lower than 9% in another large-scale 5-year study conducted in the 1990s by a hospital in the United States.¹¹

Benign or insufficient stereotactic biopsy results with specimens negative for calcium create a management planning challenge. Repeat biopsy for all these cases is not practical, whilst also causing unnecessary patient anxiety, wasting of resources, and prolonging waiting times for other patients. Besides, detection of specimen calcium cannot be guaranteed in the second biopsy, especially if the microcalcifications are faint or in suboptimal position, such as in the retroareolar region,

high axillary tail, and closed to the chest wall.

In our hospital, the decisions on the management plan for these patients were made in the joint mammogram meeting, attended by radiologists, surgeons, and pathologists specialised in breast disease. During the meeting, cases were analysed individually and holistically. The risk factors (patient history and family history of breast cancer, age), imaging features (mammographic grading, accessibility of microcalcifications), and initial pathological reports (breast pathology and presence of specimen calcium) were reviewed and discussed. Consensus on the management plan was then reached by these specialists. Repeat biopsies or surgery were arranged for high-risk patients while follow-up mammograms (after 6 months, 1 or 2 years) were arranged for lower-risk patients. If there was an interval change in number, extent, or pattern of involvement, or higher radiological grading was detected in follow-up mammograms, intervention could be suggested again by the radiologists.

Of the 32 patients with specimens negative for calcium, eight had a repeat biopsy or surgery (decided in joint mammogram meeting), which resulted in the detection of three additional malignancies. All three of these cases were R3 mammographically. The false-negative rate for malignancy in this group (R3 without calcium in their specimens) was 38%. This finding has huge implications for managing patients with R3 mammographic features and benign initial stereotactic biopsy pathology but with specimen negative for calcium. The discordant benign pathological findings could have resulted from unsuccessful retrieval of target tissue as indicated by lack of calcium. Therefore, re-biopsy to confirm the presence of calcium is strongly recommended for such patients so as to avoid missing the diagnosis of malignancy. For patients with specimens radiographically negative for calcium but in the R2 and R2-3 category, microcalcifications generally remain static. Based on this observation, we recommended follow-up mammograms for this group of patients.

CONCLUSION

Stereotactic-guided core biopsy is a non-invasive and reliable method to sample for breast microcalcifications by histological evaluation. The reliability of the test may be further increased with confirmation of calcium in the specimens by radiography and reviewing the pathological report for the presence of

calcium. In patients' specimens devoid of calcium, we reached a consensus on management plan in our joint mammography meetings. Based on the results of this study, we recommend repeat biopsies to look for the presence of specimen calcium in patients with R3 mammographic features, and follow-up mammography for patients with R2 and R2-3 mammographic features.

REFERENCES

1. Parker SH, Lovin JD, Jobe WE, Luethke JM, Hopper KD, Yakes WF, et al. Stereotactic breast biopsy with a biopsy gun. *Radiology*. 1900;176:741-7.
2. Gisvold JJ, Goellner JR, Grant DS, Donohue JH, Sykes MW, Karsell PR, et al. Breast biopsy: a comparative study of stereotactically guided core and excisional techniques. *AJR Am J Roentgenol*. 1994;162:815-20. [cross ref](#)
3. Dowlatshahi K, Yaremko ML, Kluskens LF, Jokich PM. Nonpalpable breast lesions: findings of stereotactic needle-core biopsy and fine-needle aspiration cytology. *Radiology*. 1991;181:745-50.
4. Dronkers DJ. Stereotactic core biopsy of breast lesions. *Radiology*. 1992;183:631-4.
5. Elvecrog EL, Lechner MC, Nelson MT. Nonpalpable breast lesions: correlation of stereotactic large-core needle biopsy and surgical biopsy results. *Radiology*. 1993;188:453-5.
6. Parker SH, Lovin JD, Jobe WE, Burke BJ, Hopper KD, Yakes WF. Nonpalpable breast lesions: stereotactic automated large-core biopsies. *Radiology*. 1991;180:403-7.
7. Parker SH, Burbank F, Jackman FJ, Aucreman CJ, Cardena G, Cink TM, et al. Percutaneous large-core breast biopsy: a multi-institutional study. *Radiology*. 1994;193:359-64.
8. Pfarl G, Helbich TH, Riedl CC, Wagner T, Gnant M, Rudas M, et al. Stereotactic 11-gauge vacuum-assisted breast biopsy: a validation study. *AJR Am J Roentgenol*. 2002;179:1503-7. [cross ref](#)
9. Greenberg D, Johnston J, Hart R, Weston M, Benson-Cooper D. Stereotactic breast biopsy: an audit of 18 months at BreastScreen Auckland. *Australas Radiol*. 2003;47:261-7. [cross ref](#)
10. Fahrback K, Sledge I, Cella C, Linz H, Ross SD. A comparison of the accuracy of two minimally invasive breast biopsy methods: a systematic literature review and meta-analysis. *Arch Gynecol Obstet*. 2006;274:63-73. [cross ref](#)
11. Margolin FR, Leung JW, Jacobs RP, Denny SR. Percutaneous imaging-guided core breast biopsy: 5 years' experience in a community hospital. *AJR Am J Roentgenol*. 2001;177:559-64. [cross ref](#)
12. Jackman FJ, Rodriguez-Soto J. Breast microcalcifications: retrieval failure at prone stereotactic core and vacuum breast biopsy — frequency, causes, and outcome. *Radiology*. 2006;239:61-70. [cross ref](#)
13. Brenner RJ, Bassett LW, Fajardo LL, Dershaw DD, Evans WP 3rd, Hunt R, et al. Stereotactic core-needle breast biopsy: a multi-institutional prospective trial. *Radiology*. 2001;218:866-72. [cross ref](#)
14. Brenner RJ, Fajardo L, Fisher PR, Dershaw DD, Evans WP, Bassett L, et al. Percutaneous core biopsy of the breast: effect of operator experience and number of samples on diagnostic accuracy. *AJR Am J Roentgenol*. 1996;166:341-6. [cross ref](#)
15. Egan RL, McSweeney MB, Sewell CW. Intramammary calcifications without an associated mass in benign and malignant diseases. *Radiology*. 1980;137:1-7.
16. Roses DF, Harris MN, Gorstein F, Gumport SL. Biopsy for microcalcification detected by mammography. *Surgery*.

- 1980;87:248-52.
17. Hall FM, Storella JM, Silverstone DZ, Wyshak G. Nonpalpable breast lesions: recommendations for biopsy based on suspicion of carcinoma at mammography. *Radiology*. 1988;167:353-8.
 18. Hall JA, Murphy DC, Hall BR, Hall KA. Mammographic abnormalities and the detection of carcinoma of the breast. *Am J Obstet Gynecol*. 1993;168:1677-80;discussion 1680-2.
 19. Carty NJ, Ravichandran D, Carter C, Mudan S, Royle GT, Taylor I. Randomized comparison of fine-needle aspiration cytology and Biopsy-Cut needle biopsy after unsatisfactory initial cytology of discrete breast lesions. *Br J Surg*. 1994;81:1313-4. [crossref](#)
 20. Mikhail RA, Nathan RC, Weiss M, Tummala RM, Mullangi UR, Lawrence L, et al. Stereotactic core needle biopsy of mammographic breast lesions as a viable alternative to surgical biopsy. *Ann Surg Oncol*. 1994;1:363-7. [crossref](#)
 21. Janes RH, Bouton MS. Initial 300 consecutive stereotactic core-needle breast biopsies by a surgical group. *AM J Surg*. 1994;168:533-6. [crossref](#)
 22. Doyle AJ, Murray KA, Nelson EW, Bragg DG. Selective use of image-guided large-core-needle biopsy of the breast: accuracy and cost-effectiveness. *AJR Am J Roentgenol*. 1995;165:281-4. [crossref](#)
 23. Israel PZ, Fine RE. Stereotactic needle biopsy for occult breast lesions: a minimally invasive alternative. *Am Surg*. 1995;61:87-91.
 24. Meyer JE, Christian RL, Lester SC, Frenna TH, Denison CM, DiPiro PJ, et al. Evaluation of nonpalpable solid breast masses with stereotaxic large-needle core biopsy using a dedicated unit. *AJR Am J Roentgenol*. 1996;167:179-82. [crossref](#)
 25. Lee CH, Egglin TK, Philpotts I, Mainiero MB, Tocino I. Cost-effectiveness of stereotactic core needle biopsy: analysis by means of mammographic findings. *Radiology*. 1997;202:849-54.
 26. Liberman L, LaTrenta LR, Dershaw DD, Abramson AF, Morris EA, Cohen MA, et al. Impact of core biopsy on the surgical management of impalpable breast cancer. *AJR Am J Roentgenol*. 1997;168:495-9. [crossref](#)
 27. Smith DN, Christian R, Meyer JE. Large-core needle biopsy of nonpalpable breast cancers. The impact on subsequent surgical excisions. *Arch Surg*. 1997;132:256-9. [crossref](#)
 28. March DE, Raslavicus A, Coughlin BF, Klein SV, Makari-Judson G. Use of breast core biopsy in the United States: results of a national survey. *AJR Am J Roentgenol*. 1997;169:697-701. [crossref](#)
 29. Liberman L, Dershaw DD, Rosen PP, Giess CS, Cohen MA, Abramson AF, et al. Stereotaxic core biopsy of breast carcinoma: accuracy at predicting invasion. *Radiology*. 1995;194:379-81.
 30. Liberman L, Cohen MA, Dershaw DD, Abramson AF, Hann LE, Rosen PP. Atypical ductal hyperplasia diagnosed at stereotaxic core biopsy of breast lesions: an indication for surgical biopsy. *AJR Am J Roentgenol*. 1995;164:1111-3. [crossref](#)
 31. Berg WA. When is core breast biopsy or fine needle aspiration not enough? *Radiology*. 1996;198:313-5.
 32. Dershaw DD, Morris EA, Liberman L, Abramson AF. Nondiagnostic stereotaxic core breast biopsy: results of rebiopsy. *Radiology*. 1996;198:323-5.
 33. Liberman L, Dershaw DD, Glassman JR, Abramson AF, Morris EA, LaTrenta LR, et al. Analysis of cancers not diagnosed at stereotactic core breast biopsy. *Radiology*. 1997;203:151-7.
 34. Liberman L, Evans WP 3rd, Dershaw DD, Hann LE, Deutch BM, Abramson AF, et al. Radiography of microcalcifications in stereotaxic mammary core biopsy specimens. *Radiology*. 1994;190:223-5.
 35. Feig SA. Localization of clinically occult breast lesions. *Radiol Clin North Am*. 1983;21:155-71.
 36. Snyder RE. Specimen radiography and preoperative localization of nonpalpable breast cancer. *Cancer*. 1980;46:950-6.
 37. Rosen PP, Snyder RE, Robbins G. Specimen radiography for non-palpable breast lesions: procedures and results. *Cancer*. 1974;34:2028-33.
 38. Meyer JE, Lester SC, Frenna TH, White FV. Occult breast calcifications sampled with large-core biopsy: confirmation with radiography of the specimen. *Radiology*. 1993;188:581-2.
 39. Kwok KM, Lui CY, Fung PY, Chan LK, Lam HS. Incidence, causes, and implications of unsuccessful calcification retrieval at stereotactic breast biopsy — 5 years' experience. *Hong Kong J Radiol*. 2009;11:154-60.