
CASE REPORT

Stercoral Perforation of the Sigmoid Colon with Faecal Peritonitis: Report of Two Cases

CH Lam¹, LW Lo², KF Ma², LK Chan¹

¹Department of Radiology, Kwong Wah Hospital, Yaumatei, Hong Kong; ²Department of Radiology, Princess Margaret Hospital, Laichikok, Hong Kong

ABSTRACT

Stercoral colonic perforation is one of the causes of 'spontaneous' colonic perforation. Stercoral colonic perforation is well reported in the surgical and gastroenterology literature, yet little has been published in the radiology literature. This report describes two patients with stercoral perforation of the sigmoid colon and faecal peritonitis. The aetiology, pathophysiology, and imaging findings of this rare, but fatal, condition are reviewed.

Key Words: Colonic diseases; Fecal impaction; Intestinal perforation; Peritonitis

中文摘要

乙狀結腸糞性穿孔伴糞便性腹膜炎：兩宗病例報告

林卓恆、羅麗雲、馬嘉輝、陳立堅

結腸糞性穿孔是結腸自發性穿孔的病因之一。外科和胃腸病學文獻已對結腸糞性穿孔充分報道，但放射學文獻極少發表該病。本文報告兩宗乙狀結腸糞性穿孔伴糞便性腹膜炎的病例；並回顧這種罕見致命病症的病因學、病理生理學和影像學表現。

INTRODUCTION

Stercoral colonic perforation is one of the causes of 'spontaneous' colonic perforation. Stercoral colonic perforation is often fatal due to sepsis associated with faecal peritonitis. The first case was reported by Berry in 1894.¹ Berry¹ classified spontaneous perforation into 'stercoral' and 'idiopathic' on the basis of the aetiological cause of the lesion.¹ The pathogenesis is related to formation of a faecaloma, which causes distension of the colon, and the increased intraluminal

pressure causes ischaemic necrosis of the colonic wall, ulcer formation and, subsequently, perforation.² Approximately 74% of stercoral colonic perforations occur in the sigmoid and rectosigmoid colon, with 47% occurring in the sigmoid colon and 21% occurring at multiple sites.³ Possible reasons include the sigmoid colon being the narrowest segment of the entire colon, prolonged presence of a faecaloma with the resultant solid consistency, and a precarious blood supply to the region known as Sudeck's point.⁴

*Correspondence: Dr CH Lam, Department of Radiology, Kwong Wah Hospital, 25 Waterloo Road, Kowloon, Hong Kong.
Email: summylamsjc@yahoo.com.hk*

Submitted: 27 Jul 2012; Accepted: 8 Oct 2012.

CASE REPORTS

Patient 1

An 87-year-old woman presented with generalised abdominal pain and fever in October 2009. She had a regular use of antacid. She also had a history of constipation requiring regular laxative use. On admission, her blood pressure was 140/70 mm Hg and her pulse was 110 beats per minute. On physical examination, there was generalised abdominal tenderness with guarding and rebound tenderness. Her white cell count was $20 \times 10^9 / l$ (reference range, 4.5-11.0 $\times 10^9 / l$). Computed tomography (CT) of the abdomen and pelvis showed pneumoperitoneum and free fluid in the pelvis. A focal defect was noted at the sigmoid colon, with faeces protruding through the defect (Figure 1). Urgent laparotomy was performed. Intra-operatively,

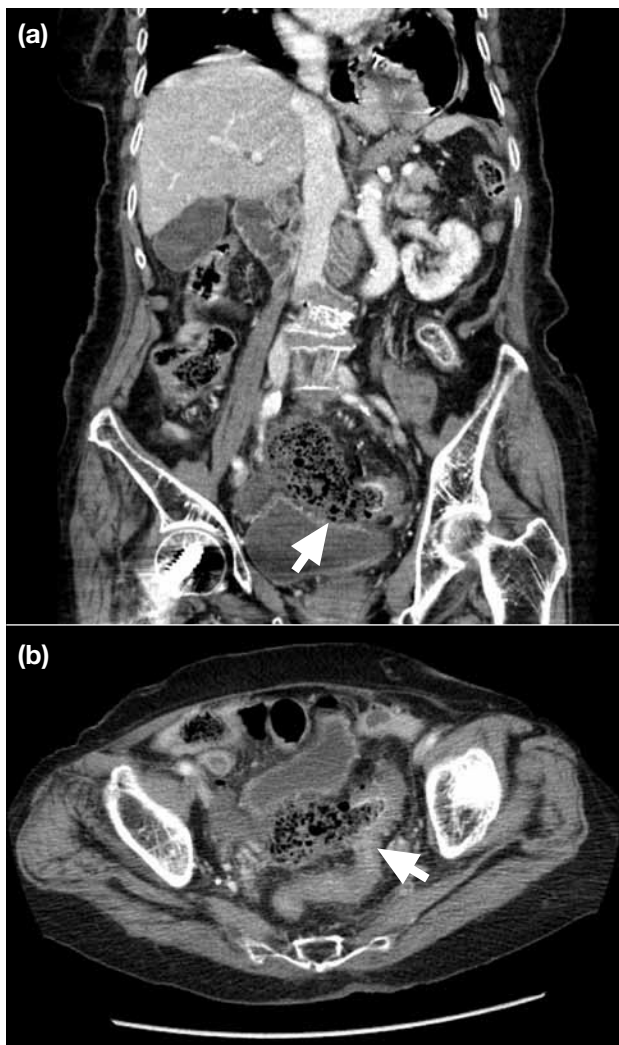


Figure 1. Reconstructed coronal computed tomography shows a faecaloma protruding through the perforation site (arrows): (a) coronal and (b) axial views.

pus was noted in the lower abdomen. There was a 2-cm perforation at the rectosigmoid junction. No tumour or diverticulitic changes were noted. The colon mucosa looked normal. There were faeces in the lower abdomen and pelvis. Distal resection of the rectosigmoid junction and Hartmann's operation were performed. The patient recovered uneventfully and was discharged.

Patient 2

A 65-year-old woman presented with colicky abdominal pain with fresh per rectal bleeding in July 2012. She had a history of hiatus hernia and gastritis requiring regular use of antacids. On physical examination, her abdomen was distended with tenderness and guarding. Her white cell count was normal ($4.1 \times 10^9 / l$) on admission. She developed respiratory distress after admission. CT of the abdomen and pelvis revealed pneumoperitoneum. Bowel wall thickening was noted over the distal sigmoid colon and rectum, where intramural gas was detected. An

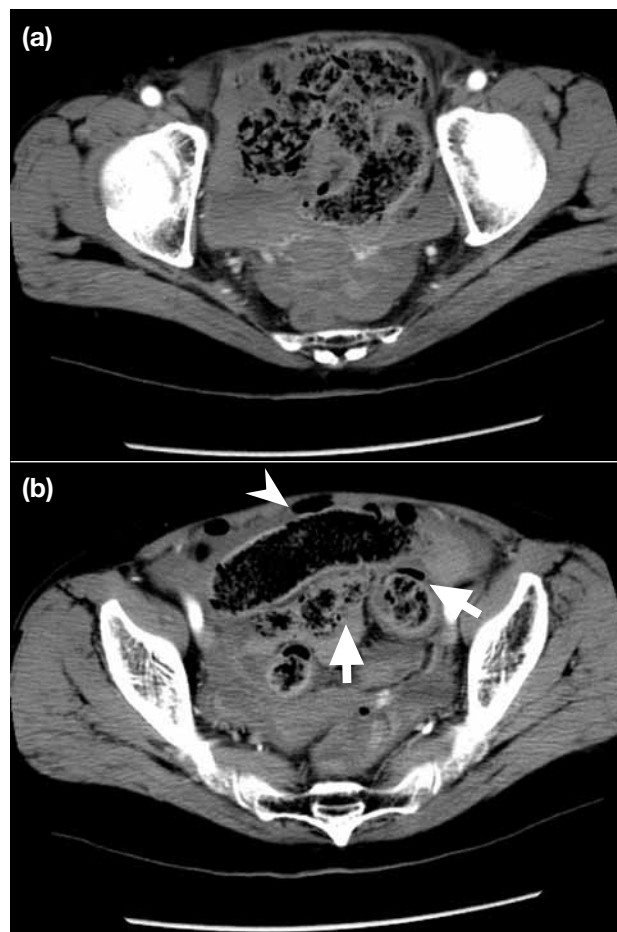


Figure 2. Axial contrast computed tomography of the pelvis shows pneumoperitoneum, pneumatosis coli and free-lying faeces in the pelvis. Axial scans show (a) free-lying faeces and (b) pneumoperitoneum (arrowhead) and pneumatosis coli (arrows)

approximately 1.5-cm mucosal defect was noted at the distal sigmoid colon with leakage of faeculent material into the peritoneal cavity (Figure 2). Urgent laparotomy was performed. Intra-operatively, there was gross faecal peritonitis with solid faeces collected in pelvis. A 2.5-cm perforation was noted at the distal sigmoid. There was no underlying tumour, diverticulitic change, gangrene, or mucosal ischaemic change seen. Sigmoidectomy and double barrel colostomy were performed. She recovered uneventfully and was discharged.

DISCUSSION

There are a few risk factors for stercoral colonic perforation, and these include constipation and the use of non-steroidal anti-inflammatory drugs, antacids, steroids, or opioids.⁵ Both of the patients described in this report had a history of regular use of these medications.

Different CT findings and diagnostic criteria have been described in the literature. One of the most characteristic features is the presence of a faecaloma within the colon, either protruding through the perforation site or lying free within the intra-abdominal cavity. The perforation is usually more than 1 cm and antimesenteric in location. Other features include focal mural thickening, dense mucosa, mucosal slough, and pneumatosis, but these are non-specific.^{2,6,7} Differential diagnoses include complicated diverticulitis, tumour, or inflammatory bowel disease. However, there are usually secondary signs such as the presence of a diverticulum, fibrofatty proliferation of mesentry, or a tumour mass. After excluding the differential diagnoses, the diagnosis of primary stercoral perforation of colon should be considered.

Timely intervention to prevent and / or treat associated sepsis is crucial. Two review articles describing optimal clinical outcomes relating to the treatment recommended resection of the perforated segment

with an end colostomy and either mucous fistula or Hartmann's procedure of the rectum.^{8,9} In this report, one patient was treated with sigmoidectomy with Hartmann's procedure and the other was treated with sigmoidectomy with double barrel colostomy. Both patients recovered uneventfully.

CONCLUSION

Stercoral colonic perforation should be considered for patients with severe chronic constipation or a history of regular use of non-steroidal anti-inflammatory drugs, antacids, steroids, or opioids, particularly if the patient is an elderly. Demonstration of a faecaloma within the colon, either protruding through the perforation site or lying free within the intra-abdominal cavity on CT scan after excluding diverticulitis and tumour, will be highly suggestive of this condition. If stercoral colonic perforation is not treated promptly, it can be fatal with a high mortality rate due to sepsis associated with faecal peritonitis.²

REFERENCES

1. Berry J. Dilation and rupture of the sigmoid flexure. *Br Med J.* 1894;i:301.
2. Heffernan C, Pachter HL, Megibow AJ, Macari M. Stercoral colitis leading to fatal peritonitis: CT findings. *AJR Am J Roentgenol.* 2005;184:1189-93. [cross ref](#)
3. Serpell JW, Nicholls RJ. Stercoral perforation of the colon. *Br J Surg.* 1990;77:1325-9. [cross ref](#)
4. Chen JH, Shen WC. Rectal carcinoma with stercoral ulcer perforation. *Hepatogastroenterology.* 2000;47:1018-9.
5. Patel VG, Kalakuntla V, Fortson JK, Weaver WL, Joel MD, Hammami A. Stercoral perforation of the sigmoid colon: report of a rare case and its possible association with nonsteroidal anti-inflammatory drugs. *Am Surg.* 2002;68:62-4.
6. Kumar P, Pearce O, Higginson A. Imaging manifestations of faecal impaction and stercoral perforation. *Clin Radiol.* 2011;66:83-8. [cross ref](#)
7. Wu CH, Huang CC, Wang LJ, Wong YC, Wang CJ, Lo WC, et al. Value of CT in the discrimination of fatal from non-fatal stercoral colitis. *Korean J Radiol.* 2012;13:283-9. [cross ref](#)
8. Durrans D, Redmond EJ, Marshman L. Stercoral perforation of the colon. *Br J Surg.* 1991;78:1148. [cross ref](#)
9. Guyton DP, Evans D, Schreiber H. Stercoral perforation of the colon. Concepts of operative management. *Am Surg.* 1985;51:520-2.