

---

---

## CASE REPORT

---

---

# Mucinous Cystadenoma of the Appendix: a Rare Cause of Right Lower Abdominal Mass

YS Luk<sup>1</sup>, LRS Lam<sup>2</sup>, JSF Shum<sup>1</sup>, JLS Khoo<sup>1</sup>

<sup>1</sup>Department of Radiology, <sup>2</sup>Department of Pathology, Pamela Youde Nethersole Eastern Hospital, Hong Kong

### ABSTRACT

*Mucinous cystadenoma is a rare tumour of the appendix and is associated with mucocele formation as well as an increased risk of adenocarcinoma of the colon and ovaries. Preoperative imaging is important for diagnosing mucocele formation, associated complications, and malignancies. A rare case of mucinous cystadenoma and a review of the clinical and radiological features of mucinous cystadenoma are presented.*

*Key Words:* Appendectomy; Appendiceal neoplasms; Appendix; Cystadenoma, mucinous

## 中文摘要

### 闌尾粘液性囊腺瘤：右下腹腫塊的罕見病因

陸嬈、藍睿熙、岑承輝、邱麗珊

粘液性囊腺瘤是闌尾的一種罕見腫瘤；與粘液囊腫形成相關，同時患結腸和卵巢腺癌的風險增加。術前影像對於診斷粘液囊腫、相關的併發症和惡性腫瘤相當重要。本文報告一宗粘液性囊腺瘤的罕見病例，並回顧粘液性囊腺瘤的臨床和影像學特徵。

### INTRODUCTION

Mucinous cystadenoma of the appendix is a rare neoplasm.<sup>1</sup> It can lead to complications such as rupture or intussusception and is associated with an increased risk of adenocarcinoma of the colon and ovaries.<sup>2</sup> We present a rare case of mucinous cystadenoma and a review of the clinical and radiological features of tumour of the appendix.

### CASE REPORT

A 61-year-old-woman presented with a right lower abdominal mass that she had had for a few months in October 2011. She had no per rectal bleeding or weight

loss, but did have a history of liver cirrhosis and a total abdominal hysterectomy for uterine fibroids. Physical examination revealed a non-tender tubular mass at the right lower quadrant of the abdomen. The preliminary diagnoses were carcinoma of the ascending colon, adnexal tumour, and mucocele of the appendix.

Computed tomography (CT) of the abdomen and pelvis was performed and showed a 12 cm x 3 cm x 3 cm blind-ended, thin-walled tubular mass in the right lower abdomen (Figure 1a). The centre of the mass was non-enhancing and showed fluid attenuation. The mass was seen to extend from the caecum along the expected

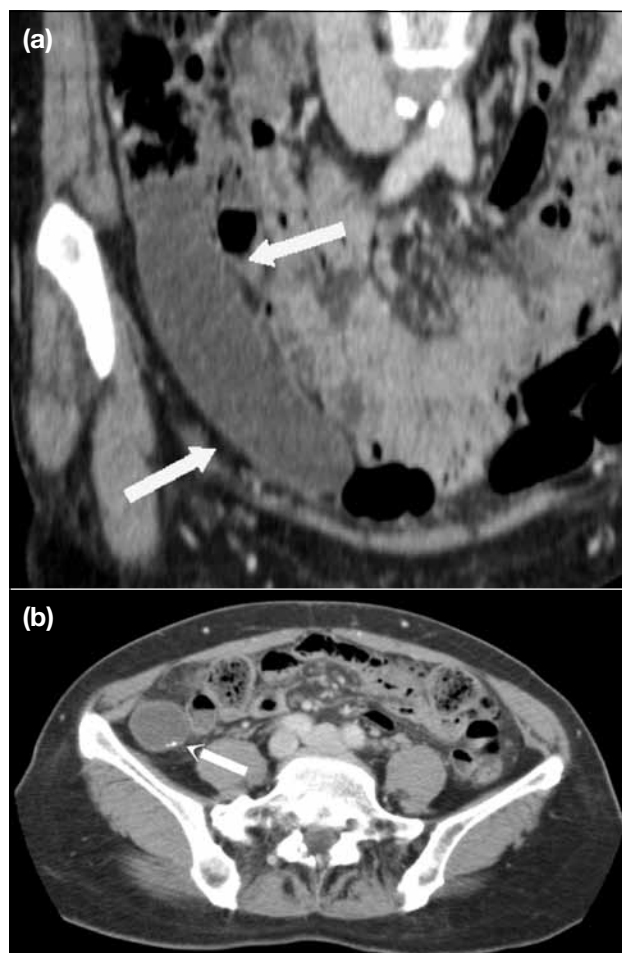
---

---

*Correspondence:* Dr YS Luk, Department of Radiology, Pamela Youde Nethersole Eastern Hospital, 3 Lok Man Road, Chai Wan, Hong Kong.

Tel: (852) 6460 0376; Email: lys177@ha.org.hk

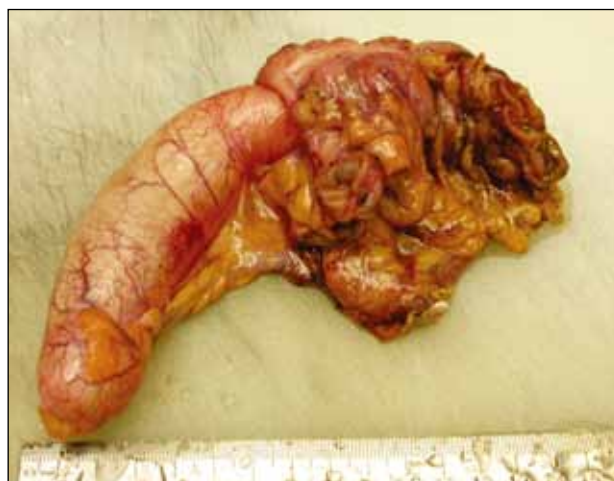Submitted: 17 May 2012; Accepted: 5 Dec 2012.



**Figure 1.** (a) A coronal image of computed tomography of the abdomen and pelvis shows a tubular mass that contains central area of fluid attenuation in the right lower abdomen (arrows). (b) An axial image of the wall of the mass contains foci of calcification (arrow).

location and course of an appendix. Few foci of wall calcification were noted (Figure 1b). There was no wall thickening or internal gaseous density, and no desmoplastic reaction, mesenteric or retroperitoneal lymphadenopathy, or ascites. The CT features were suggestive of mucocele of the appendix.

A colonoscopy was performed but showed no intraluminal mass lesion. Extra-luminal compression on the ileo-caecal region was noted. The patient subsequently underwent laparoscopy, which confirmed the appendix to be grossly enlarged. A limited right hemicolectomy was performed. Pathological examination confirmed gross dilatation of the appendix which was filled with mucin (Figure 2). Histological examination revealed that part of its epithelial lining was replaced by mucin-containing granulation tissue and macrophages. The



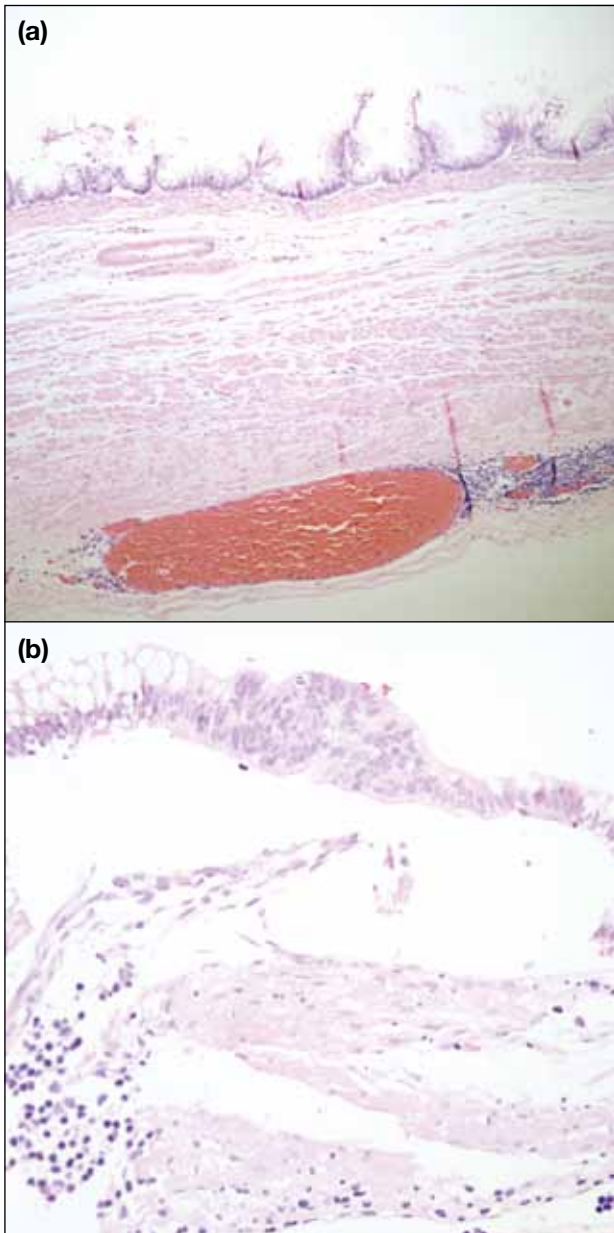
**Figure 2.** The tumour specimen shows the grossly dilated appendix.

remnant intestinal type columnar epithelium displayed short villopapillary structures with mild nuclear stratification (Figure 3). There was no evidence of dysplasia or an infiltrative growth. The features were consistent with mucinous cystadenoma of the appendix with mucocele formation.

## DISCUSSION

Mucinous cystadenoma is a rare neoplasm of the appendix.<sup>1,3,4</sup> It often demonstrates circumferential mucosal involvement and produces viscous mucus that accumulates and distends the appendix to form mucocele.<sup>5,6</sup> The point prevalence of appendicular mucoceles has been reported to be only 0.2 to 0.3% in appendectomy specimens, and 63 to 84% of mucoceles are caused by mucinous cystadenoma.<sup>4,5,7-9</sup> Mucinous cystadenoma is one of the four histological subtypes of mucocele. The other three include simple mucocele (caused by an obstructing lesion), focal or diffuse mucosal hyperplasia, and mucinous cystadenocarcinoma.<sup>10</sup> They most commonly occur in middle-aged patients, and there is a slight female predominance.<sup>9-11</sup>

The most common presentation of mucinous cystadenoma is a palpable mass in the right lower quadrant of the abdomen. It can also present as an incidental finding on imaging or as appendicitis.<sup>1,2,8-11</sup> In about 20% of cases, the tumour may perforate, leading to pseudomyxoma peritonei. Other complications include ileo-colic intussusception, right ureteral obstruction, bowel torsion with gangrene and haemorrhage.<sup>2-4,8-11</sup> Compression on the external iliac



**Figure 3.** (a) A photomicrograph of the mucocoele demonstrates villopapillary structures of the intestinal type columnar epithelium (H&E; original magnification, x 10). (b) A photomicrograph shows nuclear stratification and atypia of the intestinal type columnar epithelium (H&E; original magnification, x 40).

vein causing deep venous thrombosis of the lower limb has also been reported.<sup>5</sup> Mucinous cystadenoma is associated with an increased risk of irritable bowel disease, as well as colonic and ovarian neoplasms. One study has shown that about 21% of patients with mucinous cystadenoma have an associated colonic carcinoma.<sup>3,4,10,11</sup>

Laboratory findings for mucinous cystadenoma are non-

specific, but elevated levels of tumour markers may indicate associated carcinoma.<sup>2</sup> Fine-needle aspiration of the dilated appendix is not recommended due to the risk of pseudomyxoma peritonei.<sup>2,7,9</sup> Extrinsic compression or mass protrusion of the appendiceal orifice has been reported to be a helpful colonoscopic finding. Discharge of mucus from the appendiceal opening may also be noted during colonoscopy examination.<sup>3,9</sup>

Radiographic findings in patients with mucinous cystadenoma of the appendix include a soft tissue mass in the right lower abdomen with mass effect on surrounding bowel loops. Wall calcifications may also be evident on plain radiographs.<sup>4</sup> Barium enema may show failure of the appendix to fill with contrast and features of extra-luminal compression in the ileocaecal region.<sup>2,4</sup>

Ultrasonography (USG) features include a well-encapsulated anechoic or hypoechoic tubular structure in the right lower abdomen adjacent to the caecum. Acoustic shadowing from calcifications is sometimes encountered. Multiple echogenic layers along a dilated appendix have been reported as a specific feature for mucoceles.<sup>2,4,7,8,10</sup> The size of the mucocele caused by mucinous cystadenoma usually exceeds 2 cm.<sup>7</sup>

On CT, mucinous cystadenoma with formation of mucocele appears well defined with central areas of homogeneous low attenuation, with a Hounsfield value similar to that of water. Calcifications can be detected in the appendiceal wall in about 50% of cases. Mass effect on the surrounding bowel loops may also be noted.<sup>4,7-10</sup> CT is superior to USG in demonstrating the anatomical relationship of the mucocele with the caecum and in detecting wall calcification. Contrast-enhancing nodules have been reported as a CT feature suggesting mucinous cystadenocarcinoma.<sup>3,8</sup>

On magnetic resonance imaging (MRI), central hyperintensity on T2-weighted images can be demonstrated. Signal intensity on T1-weighted images is variable depending on the mucin concentration. A peripheral rim with low signal intensity may represent calcification.<sup>5,10</sup> Differentiation between the different histological subtypes of mucocele based on radiological features is difficult. Role of preoperative imaging is to diagnose mucocele and its associated complications and even carcinomas. The differential diagnoses of a mucocele include acute appendicitis, peri-appendiceal

abscess, enteric duplication cyst, cystic ovarian neoplasm or tubo-ovarian abscess.<sup>3,7,9,10</sup> The absence of appendiceal wall thickening of greater than 6 mm on ultrasound examination is an important feature to differentiate the lesion from acute appendicitis. Lack of infiltration of surrounding fat on CT and MRI helps to differentiate it from peri-appendiceal abscess or tubo-ovarian abscess.<sup>4,5,10</sup>

Pathological examination helps to differentiate the histological subtypes of mucocele. Gross pathological findings include enlargement of the appendix with luminal distention by mucin. Progressive mucocele formation may result in thinning of the appendiceal wall with fibrosis. Villous architecture of the mucin-rich epithelium is demonstrated in mucinous cystadenoma. Mucinous cystadenomas tend to show circumferential involvement.<sup>5,6,9</sup> Differentiation from mucinous cystadenocarcinoma on histological examination relies on a lack of stromal invasion and absence of marked nuclear atypia.<sup>3</sup>

Appendectomy is a recommended treatment for mucinous cystadenoma. It is important to prevent rupture of the mucocele during the operation to prevent dissemination.<sup>1,2,10,11</sup> Intra-operatively, differentiation between mucinous cystadenoma and mucinous cystadenocarcinoma is difficult unless there are features of local invasion and peritoneal implants. Intra-operative assessment for colonic and ovarian neoplasms have been recommended.<sup>3,10</sup> Follow-up colonoscopy and pelvic examination have also been recommended.<sup>3</sup>

A 5-year survival of 25 to 65% in patients with pseudomyxoma peritonei has been reported, whereas a figure of 91 to 100% has been reported in those without such dissemination.<sup>8,10</sup>

## REFERENCES

1. Velusamy A, Saw S, Gossage J, Bailey S, Schofield J. Combined adenocarcinoid and mucinous cystadenoma of the appendix: a case report. *J Med Case Rep.* 2009;3:28. [cross ref](#)
2. Djuranovic SP, Spuran MM, Kovacevic NV, Ugljesic MB, Kecmanovic DM, Micev MT. Mucinous cystadenoma of the appendix associated with adenocarcinoma of the sigmoid colon and hepatocellular carcinoma of the liver: report of a case. *World J Gastroenterol.* 2006;12:1975-7.
3. Zagrodnik DF 2nd, Rose DM. Mucinous cystadenoma of the appendix: diagnosis, surgical management, and follow-up. *Curr Surg.* 2003;60:341-3. [cross ref](#)
4. Lo RH, Kan PS. Appendiceal mucinous cystadenoma presenting as “porcelain” appendix with mysoglobulosis — a rare cause of a right lower quadrant mass. *Singapore Med J.* 1998;39:174-6.
5. Persaud T, Swan N, Terreggiani WC. Giant mucinous cystadenoma of the appendix. *Radiographics.* 2007;27:553-7. [cross ref](#)
6. Gibbs NM. Mucinous cystadenoma and cystadenocarcinoma of the vermiform appendix with particular reference to mucocele and pseudomyxoma peritonei. *J Clin Pathol.* 1973;26:413-21. [cross ref](#)
7. Gupta S, Sharma R, Attri A, Kaur R. Mucinous cystadenoma of appendix. *Indian J Surg.* 2008;70:254-5. [cross ref](#)
8. Krieg A, Esch JS 2nd, Poll LW, Braunstein S, Knoefel WT. Mucinous cystadenoma of the appendix misdiagnosed as cystic hydatid disease of the liver: a case report. *J Med Case Rep.* 2008;2:218. [cross ref](#)
9. Sierra-Montenegro E, Sierra-Luzuriaga G, Leone-Stay G, Quiñonez-Auria C, Salazar-Menéndez V. Mucinous cystadenoma of the appendix. Case report. *Cir Cir.* 2010;78:255-8.
10. Honnef I, Moschopoulos M, Roeren T. Appendiceal mucinous cystadenoma. *Radiographics.* 2008;28:1524-7. [cross ref](#)
11. Alese OB, Irabor DO. Mucinous cystadenoma of the appendix: a case report. *Afr Health Sci.* 2010;10:99-100.