

---

---

## CASE REPORT

---

---

# Inoperable Adenoid Cystic Carcinoma of Trachea: Complete Remission after Multi-modality Treatment

WL Chan, VHF Lee, SWK Siu, TW Leung

Department of Clinical Oncology, Queen Mary Hospital, The University of Hong Kong, Pokfulam, Hong Kong

### ABSTRACT

*Adenoid cystic carcinoma is a malignant tumour commonly originating from the salivary glands, but can rarely arise from the upper airway and be life threatening when the central airway is compromised. While surgical resection is considered the definitive treatment, adenoid cystic carcinoma of the airway is frequently unresectable for a variety of reasons including tumour size, location, local extension, or patient comorbidities. There is no consensus on the best treatment for locally advanced inoperable adenoid cystic carcinoma of trachea. This case report describes a 32-year-old woman with inoperable adenoid cystic carcinoma of trachea successfully managed in our institution using a multimodality approach: endoscopic stenting followed by 3-dimensional conformal radical radiotherapy. Previous literature on the management of this rare disease is also reviewed.*

**Key Words:** Airway obstruction; Carcinoma, adenoid cystic; Radiotherapy; Trachea

## 中文摘要

### 不能以手術切除的氣管腺樣囊性癌：多模式治療後完全緩解

陳穎樂，李浩勳，蕭偉君，梁道偉

腺樣囊性癌是一種惡性腫瘤，通常源於唾液腺；但也可罕見地源於上呼吸道，當累及中央氣道時，患者便會有生命危險。縱然手術切除被認為是規定治療，可惜氣管上的腺樣囊性癌大多不能切除。原因有多種，包括腫瘤大小、位置、局部擴散或病人的合併症。關於不能以手術切除的局部進展性氣管腺樣囊性癌的最佳治療方案，尚未達成共識。本文報告本中心成功治療的一名患有氣管腺樣囊性癌但不能以手術切除的32歲女性；方案為多種方式聯合治療，即以內鏡下支架置入後再以三維適形根治性放療。本文同時回顧以往有關這種罕見疾病治療方法的文獻。

### INTRODUCTION

Adenoid cystic carcinoma (ACC) is a malignant tumour commonly found in the salivary glands. Cases of ACC of the trachea are very rare. The incidence of tracheal tumour only accounts for 0.09% to 0.2% of all cancers

and most of them are squamous cell carcinomas; only 10% of the cases are ACCs.<sup>1,2</sup>

Most patients with ACC of trachea present with dyspnoea and wheezing. Long latency is usually

---

---

**Correspondence:** Dr WL Chan, Department of Clinical Oncology, 1/F Professorial Block, Queen Mary Hospital, 102 Pokfulam Road, Pokfulam, Hong Kong.  
Tel: (852) 2255 3111; Fax: (852) 2255 4609; Email: lokwingin@hotmail.com

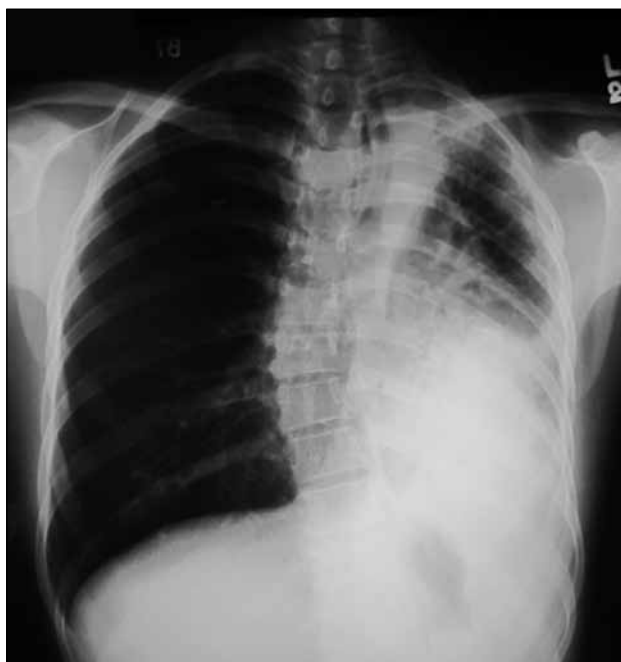Submitted: 12 Aug 2013; Accepted: 5 Nov 2013.

observed between symptom presentation and diagnosis due to its slow pace of growth. Despite its slow progression, it can be locally infiltrative and life-threatening when causing central airway obstruction which may necessitate emergency management. Surgical excision is usually the mainstay of treatment. Unfortunately, it is frequently unresectable for a variety of reasons like tumour size, location, local extension, or patient comorbidities. The standard treatment for locally advanced inoperable ACC of trachea is yet to be defined.

Here we present a case of inoperable ACC of trachea managed with multimodality treatment in our institution.

### CASE REPORT

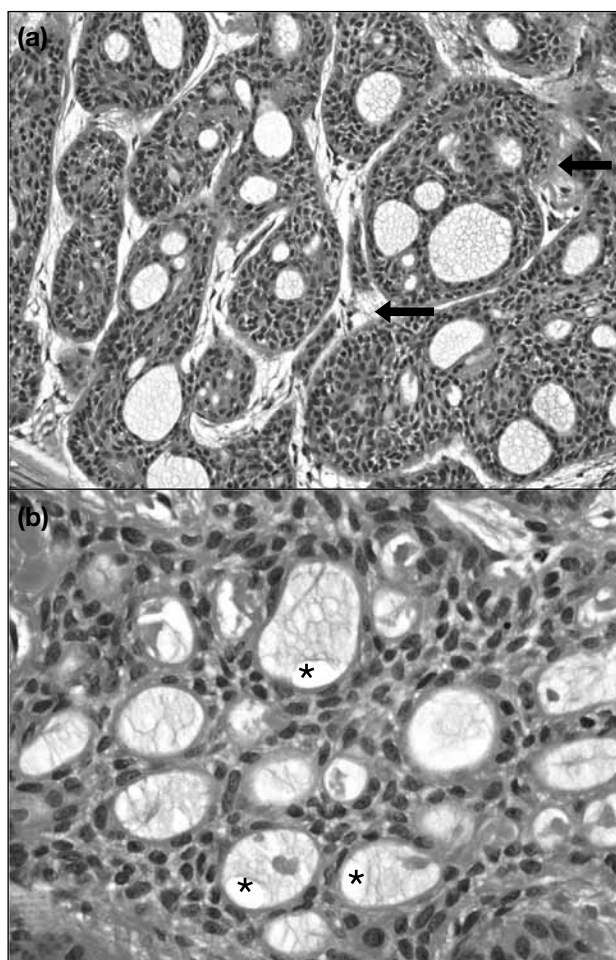
A 32-year-old Chinese female presented with chronic cough for 1 year in March 2011. She had worsening of symptoms with copious sputum and increasing shortness of breath. Her exercise tolerance gradually decreased to being able to climb just three flights of stairs. Chest X-ray showed collapse of the left lung with tracheal deviation (Figure 1). Computed tomography (CT) scan of the thorax and abdomen showed a soft tissue mass in the left subcarinal region compressing the lumen of left main bronchus and abutting the right main pulmonary artery and superior vena cava. There was no regional lymph node involvement or distant metastasis.



**Figure 1.** A chest X-ray shows collapse of left lung in the patient with adenoid cystic adenocarcinoma in the left subcarinal region.

Flexible bronchoscopy found a tumour extending from the carina down to the left main bronchus with complete obstruction. Biopsy confirmed ACC (Figure 2). While undergoing these investigations, she had deterioration with increasing dyspnoea and required oxygen therapy. Arterial blood gas, while on 50% oxygen mask, revealed type I respiratory failure ( $pO_2 = 4.24$  kPa; reference range, 10.7-13.3 kPa). Transluminal placement of tracheobronchial stent was urgently performed and symptoms were immediately relieved; oxygen was weaned off later. Results of arterial blood gas checked post-stenting were normalised.

Surgical resection was contraindicated in view of its extensive local invasion from the carina down to the left main bronchus, and close proximity to the major vessels. Even pneumonectomy with excision of the tumour would be of R2 resection with macroscopic



**Figure 2.** Tracheal biopsy shows the adenoid cystic carcinoma. (a) The tumour has a cribriform (arrows) and tubular architecture (H&E, x 10). (b) The pseudoglandular spaces contain basophilic basement membrane-like material (asterisks) [H&E, x 20].

residual disease and would put the patient at high risk of postoperative complications. Our patient then received 3-dimensional (3D) conformal radical radiotherapy with 60 Gy in 30 fractions over 6 weeks. The treatment was well-tolerated with only grade 1 odynophagia; she completed the whole treatment.

Post-treatment serial CT scans did not show any disease progression or metastasis. The 24-month post-treatment CT scan also revealed complete remission with re-expansion of the left lung (Figures 3 and 4). The patient resumed work and was enjoying a normal life.

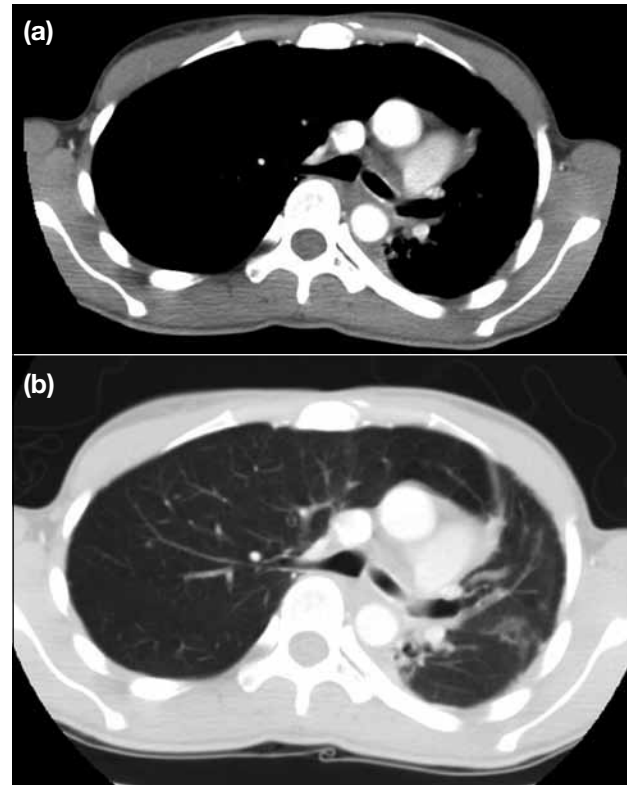
## DISCUSSION

The incidence of tracheal tumours is less than 0.2 per 100,000 people per year. There is no sex predilection and smoking is not associated with this disease.<sup>1,2</sup>

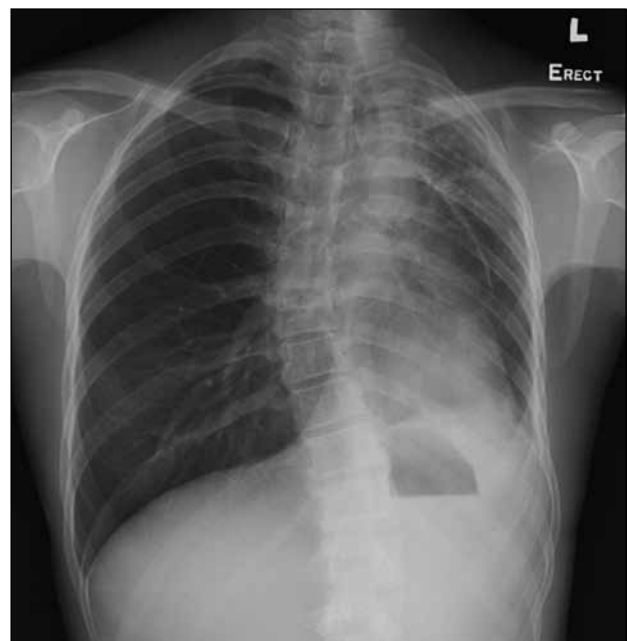
Complete surgical resection is usually the definitive treatment for tracheal ACC. The median survival time of patients after operation has been reported to range from 7.5 to 118 months. The complete resection rates reported range from 42% to 57%. Gaissert et al<sup>3</sup> published the largest series of tracheal ACC, including 135 patients in 40 years. Of these, 71% were treated with resection and the 5-year overall survival was 52%. They demonstrated that long-term survival was significantly associated with complete resection and negative airway margins.<sup>3</sup>

Unfortunately, ACC tends to infiltrate along the airways, making it difficult for complete resection. Alternative treatments are needed but sparingly reported in the literature. Definitive radiotherapy has produced mixed results, with a local control rate ranging from 20% to 70%. Maziak et al<sup>4</sup> reported good results in six patients who received primary radiotherapy for inoperable ACCs, with a mean survival of 74 months (range, 1-172 months). The majority of cases treated with definitive radiotherapy died later from local recurrence.<sup>4</sup>

Contouring and planning for radiotherapy, nonetheless, take some time to complete. Some patients may develop life-threatening airway obstruction while awaiting radiotherapy. In addition, radiotherapy may not provide immediate symptom relief for patients with ACC as the tumour is not very radiosensitive. Early intervention with bronchoscopic guidance can solve this problem and allow more time for complete investigation and comprehensive and sophisticated radiotherapy planning. There are various kinds of bronchoscopic interventions



**Figure 3.** Axial computed tomography: (a) mediastinal window and (b) lung window in July 2012 (24 months after completion of treatment) show complete remission.



**Figure 4.** A chest X-ray of the patient with adenoid cystic carcinoma 24 months post-treatment.

including mechanical dilatation with rigid tube, ballooning, minimally invasive debulking surgery, stent insertion, and laser resection.<sup>5</sup> Tracheobronchial stent insertion was found to be helpful for our patient in relieving dyspnoeic symptoms before starting radiotherapy.

Despite the fact that there are few publications on radiotherapy in ACC, different approaches are being explored in an attempt to improve treatment outcomes. These new approaches are focused on the dose of radiotherapy, new radiation techniques, and use of concurrent chemoradiotherapy.

### **Dose of Radiotherapy**

There may be a dose-response relationship between dose of radiotherapy and treatment outcomes of ACC. Some retrospective series demonstrated a more favourable treatment outcome when more than 60 Gy was given.<sup>6,7</sup> Kanematsu et al<sup>6</sup> reported the outcomes of five patients who received definitive radiotherapy at a median dose of 60 Gy (range, 50-70 Gy). One patient had complete response while the others had partial response.<sup>6</sup> Recently, Bonner Millar et al<sup>7</sup> also reported the outcomes of two patients with tracheal ACC treated with definitive radiotherapy with a dose up to 80 Gy. The two patients continued to show complete response during their 11-month and 5-year follow-up scans, respectively,<sup>7</sup> suggesting that such a high dose was feasible and safe when highly conformal treatment techniques are implemented.

Our patient showed complete remission on her 24-month post-treatment scan. This demonstrates that a dose of 60 Gy could provide long-term control in inoperable ACCs.

### **New Radiotherapy Technique**

Studies have shown that intensity-modulated radiation therapy (IMRT) and / or image-guided radiation therapy (IGRT) improves the overall survival and local control while simultaneously decreases the risk of radiation pneumonitis in stage III non-small-cell lung cancer when treated with concurrent chemotherapy.<sup>8</sup> Compared with 3D conformal technique, IMRT plans provide superior tumour coverage and better sparing of critical normal structures. Use of IMRT and / or IGRT with dose escalation may be the new approach for treating ACC in the near future.

In addition, particle radiotherapy has become more

popular and been under research for treatment of various malignancies. Bittner et al<sup>9</sup> described 20 cases with unresectable ACCs treated with upfront neutron therapy. The 5-year actuarial survival rate was 89.4%, median survival was 97 months, and 5-year local control rate was 54.1%.<sup>9</sup> However, only a few established institutions have such facility which is also costly. Larger studies are needed to elucidate the role of this modality for treating this rare disease.

Stereotactic hypofractionated radiotherapy for inoperable, early-stage non-small-cell lung cancer has been well-established. It has a high local control rate of more than 90% at 3 years.<sup>10</sup> However, most of the ACCs of airways lie in the 'no fly zone' defined as within 2 cm of the tracheobronchial tree. Thus, the practicability and safety of stereotactic hypofractionated radiotherapy for tracheal ACC remain unanswered questions.

### **Concurrent Chemoradiotherapy**

Concurrent platinum-based chemoradiotherapy has been the standard treatment of locally advanced non-small-cell lung cancer. The 2004 Cochrane review reported a significant reduction in risk of death at 2 years (relative risk, 0.93; 95% confidence interval [CI], 0.88-0.98;  $p = 0.01$ ) for concurrent chemoradiotherapy compared with radiotherapy alone.<sup>11</sup> Moreover, a meta-analysis using individual patient data in 2007 reported a significant overall survival benefit of concurrent chemoradiotherapy compared with sequential chemoradiotherapy (hazard ratio, 0.83; 95% CI, 0.73-0.94;  $p = 0.0026$ ). There was an absolute survival benefit of 6.6% at 3 years (from 18.2% with sequential treatment to 24.8% with concomitant treatment).<sup>12</sup>

Although there is not much evidence on radical chemoradiotherapy for ACC of the airway, Allen et al<sup>13</sup> reported the case of a patient who underwent chemoradiotherapy using weekly carboplatin and paclitaxel. That patient showed complete response in his 3-month post-treatment CT scan with tolerable side-effects. Longer surveillance and further research are needed to compare chemoradiotherapy with radiotherapy alone, and to derive the most suitable chemotherapy regimen.

### **CONCLUSION**

Although ACC of the airway can be locally invasive and inoperable, this does not preclude a patient from receiving radical treatment. Further studies are warranted to investigate room for improvement in

treatment outcome.

## REFERENCES

1. Gaissert HA, Mark EJ. Tracheobronchial gland tumors. *Cancer Control*. 2006;13:286-94.
2. Molina JR, Aubry MC, Lewis JE, Wampfler JA, Williams BA, Midthun DE, et al. Primary salivary gland-type lung cancer: spectrum of clinical presentation, histopathologic and prognostic factors. *Cancer*. 2007;110:2253-9. [cross ref](#)
3. Gaissert HA, Grillo HC, Shadmehr MB, Wright CD, Gokhale M, Wain JC, et al. Long-term survival after resection of primary adenoid cystic and squamous cell carcinoma of the trachea and carina. *Ann Thorac Surg*. 2004;78:1889-96; discussion 1896-7.
4. Maziak DE, Todd TR, Keshavjee SH, Winton TL, Van Nostrand P, Pearson FG. Adenoid cystic carcinoma of the airway: thirty-two-year experience. *J Thorac Cardiovasc Surg*. 1996;112:1522-31; discussion 1531-2. [cross ref](#)
5. Lee JH, Jung EJ, Jeon K, Koh WJ, Suh GY, Chung MP, et al. Treatment outcomes of patients with adenoid cystic carcinoma of the airway. *Lung Cancer*. 2011;72:244-9. [cross ref](#)
6. Kanematsu T, Yohena T, Uehara T, Ushijima C, Asoh H, Yoshino I, et al. Treatment outcome of resected and nonresected primary adenoid cystic carcinoma of the lung. *Ann Thorac Cardiovasc Surg*. 2002;8:74-7.
7. Bonner Millar LP, Stripp D, Cooper JD, Both S, James P, Rengan R. Definitive radiotherapy for unresected adenoid cystic carcinoma of the trachea. *Chest*. 2012;141:1323-6. [cross ref](#)
8. Liao ZX, Komaki RR, Thames HD Jr, Liu HH, Tucker SL, Mohan R, et al. Influence of technologic advances on outcomes in patients with unresectable, locally advanced non-small-cell lung cancer receiving concomitant chemoradiotherapy. *Int J Radiat Oncol Biol Phys*. 2010;76:775-81. [cross ref](#)
9. Bittner N, Koh WJ, Laramore GE, Patel S, Mulligan MS, Douglas JG. Treatment of locally advanced adenoid cystic carcinoma of the trachea with neutron radiotherapy. *Int J Radiat Oncol Biol Phys*. 2008;72:410-4. [cross ref](#)
10. Lagerwaard FJ, Versteegen NE, Haasbeek CJ, Slotman BJ, Paul MA, Smit EF, et al. Outcomes of stereotactic ablative radiotherapy in patients with potentially operable stage I non-small cell lung cancer. *Int J Radiat Oncol Biol Phys*. 2012;83:348-53. [cross ref](#)
11. Rowell NP, O'rourke NP. Concurrent chemoradiotherapy in non-small cell lung cancer. *Cochrane Database Syst Rev*. 2004;(4):CD002140.
12. Aupérin A, Le Péchoux C, Pignon JP, Koning C, Jeremic B, Clamon G, et al. Concomitant radio-chemotherapy based on platin compounds in patients with locally advanced non-small cell lung cancer (NSCLC): a meta-analysis of individual data from 1764 patients. *Ann Oncol*. 2006;17:473-83. [cross ref](#)
13. Allen AM, Rabin MS, Reilly JJ, Mentzer SJ. Unresectable adenoid cystic carcinoma of the trachea treated with chemoradiation. *J Clin Oncol*. 2007;25:5521-3. [cross ref](#)