
HOW I DO IT

What to Do and What Not to Do in Radiology Viva Voce

SN Keshava, SM Prabhu, A Irodi

Department of Radiology, Christian Medical College, Vellore 632004, India

ABSTRACT

Examinations are necessary rites of passage before a postgraduate radiology student becomes a full-fledged radiologist. Radiology viva voce examination requires candidates to possess thorough knowledge of the subject as well as the ability to express themselves in front of the examiners. It is frequently noted that candidates, despite possessing good subject knowledge, fail to clear their viva voce owing to their inability to articulate and impress the examiners with their strengths and knowledge. This article attempted to address this issue by providing some helpful hints to radiology students on how to prepare and handle the radiology viva voce examinations.

Key Words: Clinical competence; Educational measurement; Radiography

中文摘要

放射科口試：該做與不該做

SN Keshava, SM Prabhu, A Irodi

放射科研究生必須通過考試才能獲得放射科醫生資格。放射科口試不但要求考生深入掌握專業知識，還須有在考官面前良好的自我表達能力。可惜很多情況下，縱然考生掌握良好的學科知識，卻缺乏清晰連貫的語言表達和以自身優勢及學識打動考官的能力，以致口試失敗。本文嘗試解決這個問題，在如何最佳準備及應考放射科口試方面為考生提供指引。

INTRODUCTION

An examination is a necessary rite of passage that evaluates the knowledge and skills of a postgraduate radiology student before he / she becomes a full-fledged radiologist. In India, a radiology postgraduate student faces a comprehensive theory examination followed by a practical examination. Although it seems pretty straightforward, there is always a sensation of dread that plagues the students, especially with regard to the

practical examination.

A practical viva voce is aimed to test the candidate's knowledge using verbal communication which is essential in clinical practice. However, in many cases, despite possessing good knowledge in the subject, students fail because they are unable to articulate the answers or fail to show the examiners their strengths during the viva voce. This failure may result in an

*Correspondence: Dr SN Keshava, Department of Radiology, Christian Medical College, Vellore 632004, India.
Tel: 0416-2282027; Email: aparna_sbyam@cmcvellore.ac.in*

Submitted: 15 Oct 2013; Accepted: 8 May 2014.

aftermath of self-doubt and dejection which can be detrimental to further career development.

Outcome from an examination may depend on many factors including the triad of candidate, examiner, and environment. It is essential that the candidate understands and devises a strategy, taking into consideration of various components of the examination, namely, spotters, case presentations, and table viva voce. An 'ideal candidate' is expected to be knowledgeable, humble, smart, quick, and possess a pleasant personality. This article attempted to provide a few strategies or hints on how to prepare and handle a radiology viva voce, and to avoid common errors. For the sake of clarity, this paper is divided into two sections — before the examination and in the examination hall.

BEFORE THE EXAMINATION

During the preparatory phase, the candidate should learn to strike a balance between knowledge and expression. This can be illustrated by the iceberg analogy. The tip of the iceberg visible above the water surface constitutes merely 20% of the iceberg whilst 80% is submerged. Likewise, the examiner only sees what the student expresses (the tip of the iceberg) and is otherwise unaware of the student's understanding, comprehension or intelligence, which correspond to the submerged portion of the iceberg.

The viva voce does not only evaluate the comprehension of the candidates on the subject, but it also evaluates their expressive dexterity. This is a process of introspection and the candidate should spend sufficient time to scrutinise those portions of subject material and to revise them thoroughly prior to the examination. Revision should include information prioritisation, case analysis, and answering follow-up questions.

Revision can be tailored in the following ways:

- Prepare answers to potential viva voce questions in advance;
- Practise interactive sessions with seniors who have previously succeeded in the examination;
- Study the viva voce books;
- Actively participate in online radiology forums offering an extensive repository of radiology cases;
- Involve in study groups;
- Present a case to senior faculty members, especially those who may have been previous examiners.¹

Museum cases both in local and neighbouring

institutions and cases collected through the years by senior colleagues may also be of use to the candidates. "Aunt Minnies" can be easily tackled by seeing as many case examples as possible to reduce the chance of unfamiliarity.

Various institutions offer postgraduate refresher courses that give exposure to a large number of cases in a short time and provide an opportunity to assess the progress of individual preparation in comparison to other candidates.²⁻⁴ These could equip the candidate with the much-needed self-confidence to face the examination board.

IN THE EXAMINATION HALL

On the day of the examination, the candidate is expected to be well groomed and formally dressed to create a good first impression on the examiner. It is prudent to reach the examination centre at least an hour before the examination; this gives time to familiarise oneself with the surroundings and calm the nerves. It is helpful if the candidate can develop the rapport with the examiners within this short period of time. A simple greeting with a smile can go a long way. Identifying a friendly examiner among the group will also prove advantageous as he / she may guide the candidate through the examination.

What to Do When a Film / Case is Shown?

A case discussion is analogous to DNA synthesis and involves a sequential process of initiation, elongation, and termination.

In the initiation phase, when the film is given for discussion, the candidate should begin by describing the film without delay. Start with the modality, area covered, view, etc, and avoid staring at the film in silence. By initiating the discussion instantly, the candidate's mental faculties are warmed up and running, and this facilitates remembrance of certain facts. Remember, the highest marks are given for description or diagnosis without 'clues'. While describing a case, the candidate should, preferably, face the film instead of looking at the examiner. Only after completion of the case description and concluding the case, should the candidate turn to face the examiners for further remarks and questions. If the history is provided, it is wise to try to anticipate the topic that the examiner may want to discuss — congenital conditions, infection, malignancy, etc.

Generally, examiners do not provide misleading

clinical data. If no history is provided, extract as much information as is available from the film. Mentioning the age / age-group and gender will prevent making an unusual diagnosis (e.g. misdiagnosing fibrous dysplasia in young patients as Paget's disease).

In the elongation phase of case discussion, describe all the main findings, associated findings, and relevant negative findings which aid in coming to a conclusion. Start the description with the most important finding; even if a particular sequence is used by the candidate for viewing every film, the presentation should be in order of importance of findings. For example, when reviewing a chest radiograph, the candidate must start by describing the lung lesion if the abnormality is in the lungs.

If multiple investigations have been performed, the candidate should note the temporal sequence. Begin with the first investigation, mention findings, possible differentials and move to the next investigation. Generally, examiners do not favour candidates 'jumping' to higher diagnostic modalities, without describing the findings in the baseline modality.

The process of analysing the case and reaching a diagnosis resembles the shape of a pyramid (Figure). Detection of findings (e.g. enlarged hila with lobulated contour) forms the base; analysis and interpretation for a morphological diagnosis (e.g. lymphadenopathy) the middle; and then, finally, reaching an aetiological

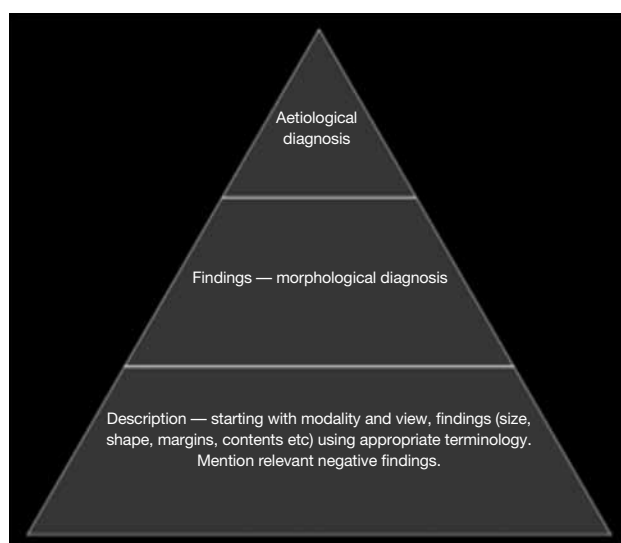


Figure. Pyramidal approach to case analysis. Detection of findings forms the base of the pyramid. Analysis and interpretation for a morphological diagnosis forms the middle. Reaching an aetiological diagnosis forms the tip of the pyramid.

diagnosis (e.g. sarcoidosis) forms the tip of the pyramid.

Any differential diagnosis, complication, and management can be expanded further, depending upon the scope of discussion. The focus of the case description should be on the main findings. Avoid giving undue importance to small unrelated incidental findings (e.g. hypoplastic 12th ribs), especially when summarising the findings; this can cause dilution of the discussion when differentials are asked.

Lastly, in the termination phase, summarise the findings. Correlate age and sex of the patient with the given clinical details and imaging findings and reach a conclusion. Link multiple findings, for instance, a lung lesion with a lytic, expansile lesion in the scapula could represent a primary in the lung with bone metastasis. Do not mention incidental findings like azygous fissure at this point of time. If a single diagnosis is not possible, list differentials; the most common condition should be mentioned first.

Conclusion should be presented with a plan for further management of the case. This gives the examiner an all-round view of the candidate's skills of deduction and decision-making capacity. In cases related to acute emergencies (e.g. aortic aneurysm with impending rupture), the candidate should promptly note that he / she would inform the referring clinician about the findings. This tells the examiner that the candidate is oriented towards patient care.

During the discussion, listen keenly and understand the examiner's line of questioning. An intelligent, structured cognitive answer to the question asked is expected by examiners.¹ Giving a reply that is not well thought out, without understanding what is being asked or unrelated to the question, can only irritate the examiner and result in more questions. Excelling in this phase requires prior focused case discussions in the preparatory phase which cannot be stressed enough. It is important to understand that examiners do want the candidate to pass. During the course of the examination, the examiner may drop hints if the candidate seems to be going down a wrong path. It is vital to catch such 'life lines' and change one's line of thought, and answer accordingly.

When the Diagnosis Is Not Known / When Stuck in a Case

In situations when one fails to arrive at a diagnosis, it may be useful to start thinking aloud, saying that one

is looking at certain parts, e.g. I am now looking at the lung, I am now looking at the cardiac shadow, etc. Try to pick up the findings while talking, instead of waiting to get the diagnosis. Even if one cannot come up with an aetiological diagnosis, it is possible that, while discussing with the examiner and listening intently to the guiding question, one will strike upon the diagnosis.

How It Is Done

- (1) Use correct terminology and definitions during case presentation and while answering specific questions. If the examiner says “plain radiograph”, the candidate may use the same terminology.
- (2) Use of the phrase “I cannot remember” is preferable to “I do not know” when the candidate does not know the answer to a certain question.
- (3) If the question was not clearly heard, politely request the examiner to repeat the question.
- (4) It is absolutely necessary to detach oneself from worries or expectations, especially with regard to fellow candidates, just before the examination.
- (5) If the diagnosis is obvious, ‘spear the case’ by using appropriate terminologies or signs described in the textbook. In such situations, avoid unnecessary differentials.
- (6) Listen carefully, answer appropriately to the questions asked, especially when the examiners are giving clues. For example, if an examiner asks “Is there any pneumothorax?” it is quite likely that it is present, and candidate should carefully search for one.
- (7) Justify any request for other relevant diagnostic modalities. For example, if a ring-enhancing lesion in the brain is suspicious for an abscess, ask for diffusion-weighted images and provide the justification. In some examinations, candidate must ‘earn’ their next film.
- (8) Truthfulness is important in the examination.

What Not to Do

- (1) Do not criticise the quality of the film (underexposed, overexposed, poor quality of film) unless specifically asked to do so. Treat every film with merit. The film displayed will have enough positive findings to make a diagnosis. In addition, the examiner will compare the candidate’s performance with previous performances. Sometimes the examiner may have sentimental attachments with the film and may be offended by comments on its quality.
- (2) Avoid touching the film or using the tip of a pen

as a pointer while describing findings of a case. Any such actions, which could damage the film, should be avoided. Remember, the particular examiner may have been safeguarding the film for many years. Give precise descriptions, including location; do not point out findings unless specifically asked to do so; when necessary, use a pointer (like a plastic ruler) rather than the finger.

- (3) Do not count numerous lesions; instead use neutral terminologies like “multiple lesions”. Counting specific numbers will delay and give scope for errors. For instance, if a mid-thoracic vertebral body is collapsed, mention it as “mid-thoracic” and count the exact number only if asked. A wrong level should not be mentioned in a hurry. Similarly, when asked differentials, causes or types, do not say that there are ‘x’ number of differentials, as the candidate may not remember them all.
- (4) Try to avoid steering the discussion towards an area or topic that one may be unsure about, thus, avoiding further questions on that topic.
- (5) Nobody expects a candidate to be perfect. Do not allow a single misdiagnosis to affect the rest of the examination.
- (6) Do not ask questions, such as “Is there any history of trauma?” Instead, make complete sentences like “If there is any history of trauma...” Asking a question will reduce the marks and it will be difficult to continue if there is no answer or the answer is “no”.
- (7) Never contradict / argue with the examiner.
- (8) Examiners have the responsibility on their part towards the patient community to allow only ‘safe radiologists’, and hence, in every examination, certain mistakes committed by the candidate are considered inexcusable. Some examples of such ‘fatal mistakes’ committed by candidates in examinations from time to time include missing a pneumothorax on a supine chest radiograph or non-accidental injury in paediatric imaging studies. Candidates should make their own list of review areas or findings that need to be ruled out before declaring an imaging to be normal.

ELECTRONIC FORMATS FOR RADIOLOGY VIVA VOCE

With a recent shift to electronic formats for radiology viva voce in some countries, it has become necessary to familiarise oneself with the use of the mouse for image viewing. Candidates accustomed to using the scroll function on the keyboard for scrolling images

need to practise using the mouse for the examination, as keyboards are not provided. As a single mouse is shared by the examiner and the candidate, following 'mouse etiquettes' becomes important. The candidate should avoid grabbing the mouse from the examiner's hand. Asking for permission from the examiner before using the mouse or handling the mouse only after being offered by the examiner is appropriate. It is prudent to avoid using fingers to point at findings on the screen; instead, the candidate should practise using the mouse pointer for the same. The candidate should familiarise oneself with the OsiriX software which is currently being used for display of images in radiology viva voce examinations. Prior usage of the OsiriX software and watching instructional videos which are available online will help relieve some anxiety for the examination

CONCLUSION

This discussion is the result of authors' cumulative

experience and aimed to provide candidates with advice, which may be helpful in their radiology viva examination.

ACKNOWLEDGEMENT

We would like to thank Prof AC Lamont, Consultant Radiologist, Townsville Hospital, Australia for his valuable inputs in preparation of this manuscript.

REFERENCES

1. Cascarini L, Lowe DG. Surviving a viva: a guide for candidates. *J R Soc Med.* 2004;97:498-500. [cross ref](#)
2. Canon CL, Mulligan S, Koehler RE. Mock radiology oral examination. *Acad Radiol.* 2005;12:368-72. [cross ref](#)
3. Subhas G, Yoo S, Chang YJ, Peiper D, Frikker MJ, Bouwman DL, et al. Benefits of mock oral examinations in a multi-institutional consortium for board certification in general surgery training. *Am Surg.* 2009;75:817-21.
4. DeCann RW, Hegarty JR. A comparison of the performance of role-play and non-role-play students at interview. *Radiography.* 1987;53:219-21.