

---

---

**ORIGINAL ARTICLE**

---

---

## **Efficacy of Acrylamido Polyvinyl Alcohol Hydrogel Microspheres for Uterine Artery Embolisation for Leiomyoma**

**WM Wong, FSK Chu, WK Tso**

*Department of Radiology, Queen Mary Hospital, Pokfulam, Hong Kong*

### **ABSTRACT**

**Objective:** To evaluate the efficacy of acrylamido polyvinyl alcohol hydrogel microspheres (A-PVAM) for uterine artery embolisation for leiomyoma in our centre in Hong Kong.

**Methods:** This retrospective study reviewed cases that underwent uterine artery embolisation for symptomatic leiomyomas using A-PVAM from 2009 to 2012 in a single local institute. Pre- and post-embolisation magnetic resonance images of pelvis were evaluated by independent radiologists who were not involved in the procedures, and reduction in the volumes of uterus and dominant leiomyoma was calculated. Procedural details, angiographic features, and clinical consultation notes were reviewed. Procedure-related complications and clinical outcomes were studied.

**Results:** A total of five patients were included in the study. All patients showed reduction in the volumes of the uterus and dominant leiomyomas. The mean volume reduction in the dominant leiomyoma was 45.8% (range, 18.2%-78.8%), and mean uterine volume reduction was 31.4% (range, 12.8%-53.5%). Post-embolisation scans of all patients showed necrosis of the leiomyomas. No procedure-related complications such as endometritis, pelvic inflammatory disease, transcervical expulsion of leiomyomas, uterine ischaemia, or loss of ovarian function were noted. All the five patients had clinical improvement in their pressure and / or menorrhagia symptoms.

**Conclusion:** A-PVAM for uterine artery embolisation for leiomyomas in the manner described resulted in high rates of positive outcomes in our limited sample size. Further research on new embolic agents for uterine artery embolisation including A-PVAM would be useful.

**Key Words:** Leiomyoma; Polyvinyl alcohol; Uterine artery embolization; Uterine neoplasms

## **中文摘要**

### **丙烯酸胺聚乙炔醇凝膠微球用於子宮肌瘤的動脈栓塞術的效果**

**黃慧美、朱兆麒、曹偉權**

**目的：**探討在香港一所中心內，丙烯酸胺聚乙炔醇凝膠微球（A-PVAM）用於子宮肌瘤動脈栓塞術的效果。

**方法：**本研究回顧在2009年至2012年期間一個本地中心內使用A-PVAM作子宮肌瘤動脈栓塞術的病例。由未參與手術的獨立放射科醫生分別評估病人在栓塞術前後的磁共振圖像，計算子宮和主要子宮肌瘤的體積減少比例。並翻查手術程序的細節、血管造影特徵和臨床診斷的資料。與手術相關的

---

---

**Correspondence:** Dr Wai-mei Wong, Department of Radiology, Queen Mary Hospital, 102 Pokfulam Road, Pokfulam, Hong Kong. Tel: (852) 2255 3284; Fax: (852) 2255 5497; Email: wwm322@ha.org.hk

Submitted: 6 Jan 2014; Accepted: 26 May 2014.

併發症和臨床結果也一一進行了研究。

**結果：**共5例被納入本研究。所有患者的子宮和主要子宮肌瘤體積均有減少。主要子宮肌瘤的體積平均縮小了45.8%（介乎18.2%至78.8%）；子宮的體積也平均縮小了31.4%（介乎12.8%至53.5%）。所有患者栓塞術後的掃描均顯示肌瘤壞死。無手術相關併發症的發生，如子宮內膜炎、盆腔炎、子宮平滑肌瘤經宮頸剝脫、子宮缺血或卵巢功能喪失。5例患者在壓力和 / 或月經過多的症狀方面均有改善。

**結論：**雖然本研究的病例數目有限，但也證明A-PVAM用以子宮肌瘤動脈栓塞術治療效果積極的機率高。未來對於包括A-PVAM在內的子宮動脈栓塞術新型栓塞劑的進一步研究會很有用。

## INTRODUCTION

Acrylamido polyvinyl alcohol hydrogel microspheres (A-PVAM) has been available as an embolic agent since 2002, yet limited literature about its efficacy for uterine artery embolisation (UAE) for symptomatic leiomyoma is available worldwide. In this study, we present our local experience with the use of this embolic agent.

## METHODS

### Patient Selection Criteria

This retrospective study analysed data collected from 2009 to 2012. All patients who underwent UAE for symptomatic uterine leiomyoma(s) using A-PVAM (Bead Block Biocompatibles, Farnham, UK) during the study period were included. Those patients who did not undergo post-embolisation imaging were excluded. Patients who underwent UAE using other embolic agents, or for other purposes not related to symptomatic leiomyomas, like adenomyosis, postpartum haemorrhage, vascular malformation, etc, were excluded. Two patients who used A-PVAM together with polyvinyl alcohol (PVA) particles were also excluded. This retrospective study was exempted from approval by the ethics committee as this was a case series only.

### Pre- and Post-embolisation Clinical Assessment

All patients were referred from the Department of Obstetrics and Gynaecology of Queen Mary Hospital, Hong Kong. They were categorised into two major symptom groups, namely, pressure symptoms and menorrhagia. Their symptoms were assessed clinically before and after the embolisation in outpatient clinics by gynaecologists. The clinical consultation notes were reviewed through electronic patient records. Before undertaking the procedures, these patients were referred to our departmental outpatient clinic

and seen by interventional radiologists who reviewed the clinical history to rule out any contraindications to UAE<sup>1</sup> including current pregnancy, known or suspected gynaecological malignancy, current uterine or adnexal infection, history of allergy to contrast, coagulopathy, and renal failure. The radiologists also reviewed the pre-embolisation magnetic resonance imaging (MRI) scans for anatomical location of the leiomyomas. Those patients with intracavitary or cervical leiomyoma and pedunculated leiomyoma with narrow stalks were rejected for UAE. The procedure and potential complications were explained during the consultation.

After the procedure, the patient symptoms were reassessed by the gynaecologists. Any subsequent surgical treatment received or complications related to the procedure were reviewed. Their follow-up in the gynaecology clinic was ongoing at the time this manuscript was written. All the clinical consultation notes until 1 May 2014 were reviewed.

### Pre- and Post-embolisation Magnetic Resonance Imaging Assessment

All patients had MRI of the pelvis before and after embolisation to assess the volume of the uterus and largest leiomyoma (calculated by the formula: height x length x width x 0.523). The MRI was reported by at least one radiology specialist who was not involved in the embolisation procedures. The percentage reductions in the volumes of the uterus and largest leiomyoma were calculated. Characteristics of the uterine leiomyomas including numbers, location, as well as pre- and post-embolisation signal intensity change were also recorded. Necrosis was defined as lack of enhancement of leiomyoma, or new T1-weighted hyperintense signal suggesting haemorrhagic infarction, or new T2-weighted hyperintense signal suggestive of liquefactive necrosis.

## Embolisation Procedures

All embolisation procedures were performed by two radiologists who were interventional radiology specialists and trainers at the Hong Kong College of Radiologists. The procedures were performed under deep sedation induced by anaesthetists. Vascular access was achieved by bilateral or single common femoral puncture followed by insertion of 5-French (5Fr) vascular sheath. Angiography of internal iliac artery and subsequent uterine artery on each side was performed with either angiocatheter 4Fr Cobra 1 or Simmons Sidewinder II with hydrophilic guidewire, and further super-selective catheterization of the uterine artery with or without coaxial micro-catheter system, depending on the size of the uterine artery. Different sizes of A-PVAM including 300 to 500  $\mu\text{m}$ , 500 to 700  $\mu\text{m}$ , and 700 to 900  $\mu\text{m}$  were used, according to the size of the uterine artery. The procedures were performed according to the recommended protocol provided by the manufacturing company. About 5 ml of contrast was used to dilute the A-PVAM to obtain a 50% contrast and 50% A-PVAM saline solution mix. The A-PVAM suspension was injected from the syringe under fluoroscopic visualisation using a slow pulsatile action, while observing the contrast flow rate under real-time fluoroscopic screening to prevent any backflow. Additional injections of A-PVAM of the same size or larger size were given until the radiological endpoint was reached, corresponding to an angiographic image of a patent horizontal segment with stagnant flow in the ascending segment of the uterine artery (Figures 1 to 4). The same procedures were performed on the contralateral side with a new set of catheter and guidewire. In one patient, only right UAE was performed as the left uterine artery could not be catheterized despite repeated attempts by both radiologists.

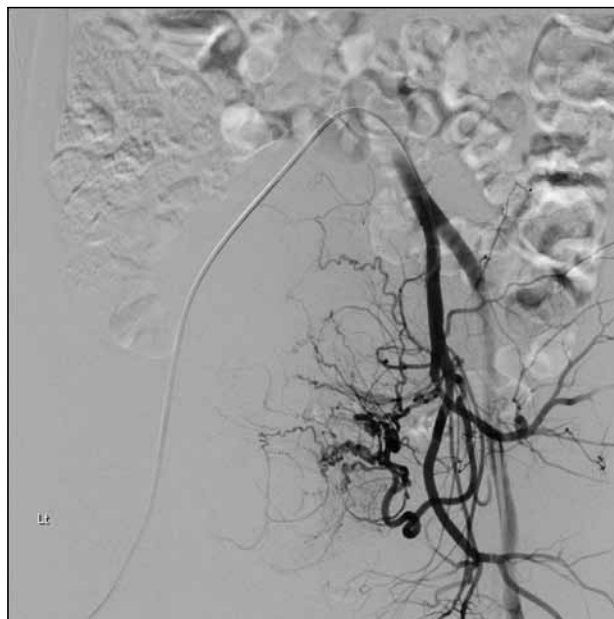
## RESULTS

### Patient Baseline Characteristics

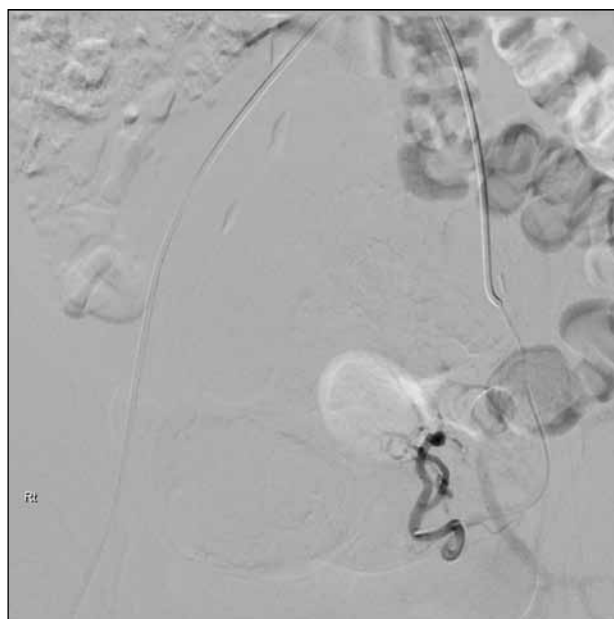
A total of five patients were included in this study. The mean age was 43 years (range, 37-53 years). Three of the patients mainly presented with pressure symptoms (60%), one with menorrhagia (20%), and one was suffering severely from both pressure and menorrhagia symptoms (20%). Three patients had undergone previous myomectomy.

### Pre-embolisation Magnetic Resonance Imaging Characteristics

All patients had more than 10 uterine leiomyomas.

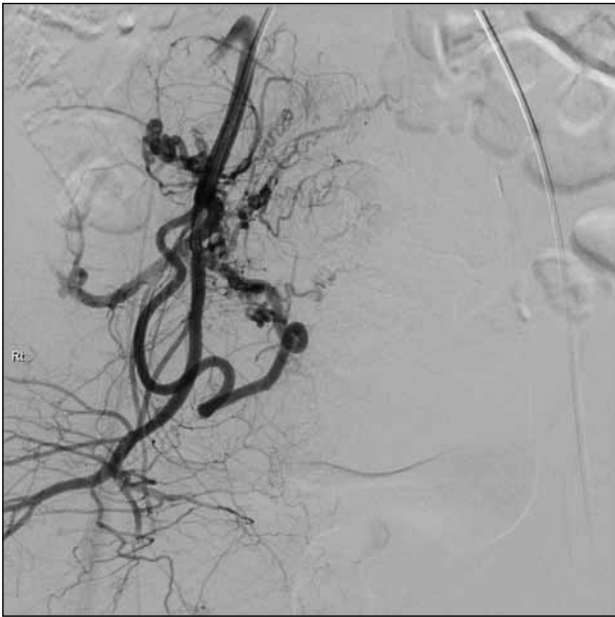


**Figure 1.** Pre-embolisation angiogram of the left internal iliac artery shows hypertrophic arteries supplying the uterine leiomyomas.

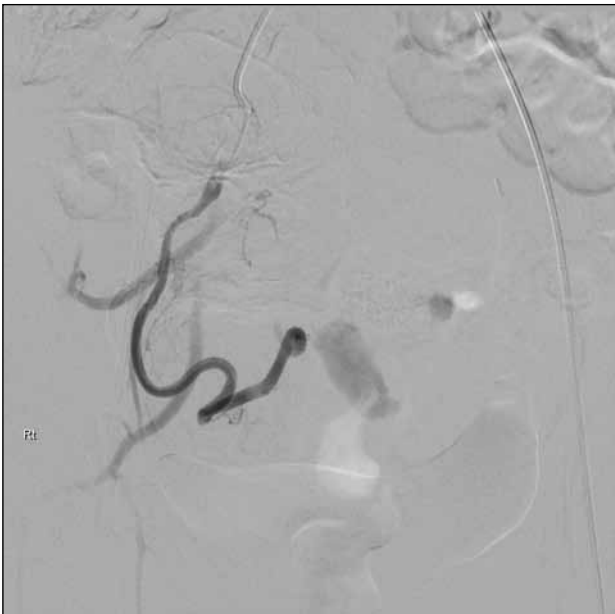


**Figure 2.** Post-embolisation selective angiogram of left uterine artery shows absence of flow to uterine leiomyomas while the blood flow in the horizontal and ascending segment of the left uterine artery is stagnant.

Three out of five patients had uterine leiomyomas with subserosal, intramural, and submucosal components. One patient had intramural leiomyomas only, while one patient had both intramural and subserosal leiomyomas. The mean uterine volume was 685.4 ml,



**Figure 3.** Pre-embolisation angiogram of the right internal iliac artery shows hypertrophic arteries supplying the uterine leiomyomas.



**Figure 4.** Post-embolisation selective angiogram of the right uterine artery shows absence of flow to uterine leiomyomas while the blood flow in the horizontal and ascending segment of the right uterine artery is stagnant.

and the mean volume of the largest leiomyoma was 203.4 ml.

### Post-embolisation Magnetic Resonance Imaging Characteristics

All patients showed reduction in the volumes of uterus

and dominant leiomyoma. The mean volume reduction in the dominant leiomyoma was 45.8% (range, 18.2%-78.8%), and the mean uterine volume reduction was 31.4% (range, 12.8%-53.5%). Post-embolisation scans of all patients showed necrosis of the leiomyomas.

In the patient who underwent only unilateral UAE, uterine volume reduction was 25.6%, and volume reduction in the dominant leiomyoma was 18.2%.

### Clinical Outcomes

All patients had clinical improvement in their pressure and / or menorrhagia symptoms. One patient who had bilateral UAE underwent subsequent myomectomy despite reduction of uterine volume, because she continued to suffer from urinary frequency after UAE. She had uterine volume reduction of 32% and dominant fibroid reduction of 50%, yet her uterus size after UAE corresponded to that of an 18-week pregnant uterus. Her uterus size was static on MRI and ultrasound after UAE until before surgery.

### Procedure-related Complications

No procedure-related complications such as endometritis, pelvic inflammatory disease, transcervical expulsion of leiomyoma, uterine ischaemia, or loss of ovarian function were reported. Length of hospital stay ranged from 2 days to 4 days, with one exception who stayed for 8 days for pain control.

### DISCUSSION

Uterine leiomyoma is a very common gynaecological condition. The lifetime risk for a woman over the age of 45 years of having leiomyomas is more than 60%.<sup>2</sup> Patients with uterine leiomyoma commonly present with menorrhagia, pain, and urinary symptoms.<sup>3</sup> Although hysterectomy has been considered the definitive treatment, many uterus-conserving treatments have been widely used or are now being investigated. The non-surgical / minimally invasive surgical treatments include laparoscopic or hysteroscopic myomectomy, UAE, and newer options like magnetic resonance-guided high-intensity focused ultrasound, myolysis / radiofrequency ablation and laparoscopic or vaginal occlusion of uterine vessels.<sup>4</sup> UAE for symptomatic leiomyomas was first described by Ravina et al in 1995.<sup>5</sup> In a recent Cochrane review summarising the results of five randomised clinical trials comparing UAE versus surgery (hysterectomy / myomectomy), with a 5-year follow-up, UAE appeared to have an overall patient satisfaction rate similar to hysterectomy

and myomectomy, while offering an advantage with regard to a shorter hospital stay and a quicker return to routine activities. There was no significant difference in major complication rate and ovarian failure rate at long-term follow-up. However, UAE is associated with a higher rate of minor complications including nausea, pain and vaginal discharge, and an increased likelihood of requiring surgical intervention within 2 to 5 years of the initial procedure.<sup>6</sup> The principle of UAE is based on the fact that there are enlarged vessels feeding the leiomyoma and there is preferential flow through these vessels early in the embolisation process. The goal is to occlude the vessels of the leiomyoma but not to completely occlude the uterine artery.<sup>7</sup>

PVA particles (Contour; Target Vascular/Boston Scientific Corp., Marlborough [MA], USA) was the only embolic agent commercially available until 2002. Three types of regularly calibrated microspheres were introduced over a short time period, subsequently, with increasing usage, as there is concern regarding particle clumping, unpredictable behaviour, and the clinical effectiveness with the use of Contour PVA in UAE.<sup>8</sup> These included tris-acryl gelatin microspheres (TAGM), Embosphere (Biosphere Medical, Rockland [MA], USA), acrylamido PVA microspheres, Bead Block (Biocompatibles, Farnham, UK), and spherical PVA microspheres (Contour SE; Boston Scientific Corp., Natick [MA], USA). Pelage et al<sup>9</sup> used a sheep model to show that calibrated microspheres behave differently from nonspherical PVA in UAE. PVA particles were associated with more uterine necrosis than calibrated tris-acryl microspheres. Furthermore, PVA particles occluded vessels of a wider range of size than did calibrated TAGM since they form aggregates.<sup>9</sup> PVA was also shown to reduce fertility in sheep models after UAE.<sup>7</sup>

To date, there is limited information on the clinical impact of different regularly calibrated microsphere for UAE. A systematic review and meta-analysis of published comparative trials by Das et al<sup>10</sup> showed no evidence of superiority of any embolic agent. When this manuscript was written, only five clinical studies on A-PVAM for UAE had been published.<sup>11-16</sup> Worthington-Kirsch et al<sup>13</sup> showed that there was no difference in efficacy between A-PVAM and TAGM. Our result is comparable with that by Liaw et al,<sup>11</sup> who reported UAE with A-PVAM caused volume reduction of around 53% (standard deviation [SD], 17%) in the dominant leiomyoma and uterine volume

reduction of 38% (SD, 22%). The other four clinical studies used reduction in enhancement on MRI as the imaging outcome.<sup>12-16</sup> Abramowitz et al<sup>12</sup> found a significant difference in post-embolisation enhancement between Bead Block and Embosphere, Bead Block and Contour, Contour SE and Embosphere, and Contour SE and Contour. Bead Block was shown to be associated with lower mean reduction in enhancement as compared with Contour and Embosphere. We did not choose percentage of reduction in enhancement for outcome evaluation as one patient could not have post-embolisation contrast MRI due to poor renal function.

## CONCLUSION

A-PVAM for UAE of leiomyomas in the manner described resulted in a high rate of positive outcome in our study with a limited sample size. However, the efficacy of A-PVAM for UAE is yet to be fully investigated. Future study on its long-term outcome, or a comparative study with other embolic agents would be useful. Interventional radiologists should stay updated of data from studies with new embolic agents.

## DECLARATION

No conflicts of interest were declared by authors.

## REFERENCES

1. Bulman JC, Ascher SM, Spies JB. Current concepts in uterine fibroid embolization. *Radiographics*. 2012;32:1735-50. [crossref](#)
2. Okolo S. Incidence, aetiology and epidemiology of uterine fibroids. *Best Pract Res Clin Obstet Gynaecol*. 2008;22:571-88. [crossref](#)
3. Parker WH. Etiology, symptomatology, and diagnosis of uterine myomas. *Fertil Steril*. 2007;87:725-36. [crossref](#)
4. van der Kooij SM, Ankum WM, Hehenkamp WJ. Review of nonsurgical/minimally invasive treatments for uterine fibroids. *Curr Opin Obstet Gynecol*. 2012;24:368-75. [crossref](#)
5. Ravina JH, Herbreteau D, Ciraru-Vigneron N, Bouret JM, Houdart E, Aymard A, et al. Arterial embolisation to treat uterine myomata. *Lancet*. 1995;346:671-2. [crossref](#)
6. Gupta JK, Sinha A, Lumsden M, Hickey M. Uterine artery embolization for symptomatic uterine fibroids. *Cochrane Database Syst Rev*. 2012;5:CD005073.
7. Laurent A, Pelage JP, Wassef M, Martal J. Fertility after bilateral uterine artery embolization in sheep model. *Fertil Steril*. 2008;89(5 Suppl):1371-83. [crossref](#)
8. Golzarian J, Lang E, Hovsepian D, Kroncke T, Lampmann L, Lohle P, et al. Higher rate of partial devascularization and clinical failure after uterine artery embolization for fibroids with spherical polyvinyl alcohol. *Cardiovasc Intervent Radiol*. 2006;29:1-3. [crossref](#)
9. Pelage JP, Laurent A, Wassef M, Bonneau M, Germain D, Rymer R, et al. Uterine artery embolization in sheep: comparison of acute effects with polyvinyl alcohol particles and calibrated microspheres. *Radiology*. 2002;224:436-45. [crossref](#)
10. Das R, Champaneria R, Daniels JP, Belli AM. Comparison of embolic agents used in uterine artery embolisation: a systematic review and meta-analysis. *Cardiovasc Intervent Radiol*. 2014;37:1179-90. [crossref](#)

11. Liaw JV, Yun CH, Walker TG, Kalva SP, Janne d'Othée B. Comparison of clinical and MR imaging outcomes after uterine fibroid embolization with A-PVAM and Embosphere. *Eur J Radiol.* 2012;81:1371-5. [cross ref](#)
12. Abramowitz SD, Israel GM, McCarthy SM, Pollak JS, White RI Jr, Tal MG. Comparison of four embolic materials at uterine artery embolization by using postprocedural MR imaging enhancement. *Radiology.* 2009;250:482-7. [cross ref](#)
13. Worthington-Kirsch RL, Siskin GP, Hegener P, Chesnick R. Comparison of the efficacy of the embolic agents acrylamido polyvinyl alcohol microspheres and tris-acryl gelatin microspheres for uterine artery embolization for leiomyomas: a prospective randomized controlled trial. *Cardiovasc Intervent Radiol.* 2011;34:493-501. [cross ref](#)
14. Kroencke TJ, Scheurig C, Lampmann LE, Boekkooi PF, Kissner L, Kluner C, et al. Acrylamido polyvinyl alcohol microspheres for uterine artery embolization: 12-month clinical and MR imaging results. *J Vasc Interv Radiol.* 2008;19:47-57. [cross ref](#)
15. Stampfl U, Radeleff B, Sommer C, Stampfl S, Dahlke A, Bellemann N, et al. Midterm results of uterine artery embolization using narrow-size calibrated embozene microspheres. *Cardiovasc Intervent Radiol.* 2011;34:295-305. [cross ref](#)
16. Verret V, Ghegediban SH, Wassef M, Pelage JP, Golzarian J, Laurent A. The arterial distribution of Embozene and Embosphere microspheres in sheep kidney and uterus embolization models. *J Vasc Interv Radiol.* 2011;22:220-8. [cross ref](#)