

Percutaneous Endovascular Intervention in Transplant Renal Artery Stenosis: Long-term Outcome in the Chinese Population

PPY Lui¹, PSF Lee¹, HKY Tam¹, RKL Lee², LWY Chan¹, JHY Leung², CM Chu²

¹Department of Radiology, North District Hospital, Hong Kong; ²Department of Imaging and Interventional Radiology, Prince of Wales Hospital, Hong Kong

ABSTRACT

Objective. To assess the technical success and long-term outcome in Chinese patients with transplant renal artery stenosis (TRAS) after percutaneous transluminal angioplasty (PTA), with or without stenting.

Methods. A retrospective review of 44 consecutive PTA (with or without stenting) in 35 patients with TRAS from September 2003 to January 2012 in two regional hospitals of the New Territories East Cluster, Hong Kong was conducted. Technical success, complications, serum creatinine level, arterial blood pressure, and number of antihypertensive medications taken before and after intervention were assessed and compared. Graft survival was estimated using Kaplan-Meier method.

Result. Of 44 interventions (17 PTA and 27 PTA with stenting) performed, 35 were primary interventions and the remaining 9 were secondary for re-stenosis. Overall technical success rate was 95.5% (PTA: 88.2%; PTA with stenting: 100%). No major complication or graft loss during intervention was observed. There were four minor complications including a self-limiting dissection in external iliac artery and three puncture site haematomas. There was no significant difference in restenosis rate between the PTA (25.0%) and PTA with stenting (26.1%) groups ($p > 0.05$). There was a persistent improvement in graft dysfunction and hypertensive control in the short and intermediate term, with satisfactory clinical success in patients presenting with graft dysfunction (100%) and hypertension (94%). Long-term clinical success in hypertensive control was relatively sustained (84.6%) while that in creatinine level it was only partially sustained (68.5%) with a mean follow-up of 70.3 (standard deviation, 32.9) months. Estimated allograft survival after all interventions was 100% at 1 year and 97% at 5 years.

Conclusion. Treatment of haemodynamically significant TRAS with percutaneous endovascular intervention is a safe procedure with high technical success, showing beneficial effects in improving allograft function and blood pressure in the short and intermediate term, as well as good long-term graft survival.

Key Words: Angioplasty, balloon; Kidney transplantation; Renal artery obstruction; Treatment outcome

中文摘要

移植後腎動脈狹窄的經皮血管內介入治療：華籍人口中的遠期療效

呂沛欣、李醒芬、譚家盈、李嘉樂、陳慧儀、梁凱瑩、朱卓文

目的：評估經皮腔內血管成形術（PTA）治療移植後腎動脈狹窄（TRAS）華籍患者（有或無支架）的技術成功率和長期預後。

Correspondence: Dr Phoenix PY Lui, Department of Radiology, G/F, North District Hospital, Sheung Shui, Hong Kong.
Tel: (852) 2683 7376; Email: phoenixlui@gmail.com

Submitted: 3 Mar 2014; Accepted: 9 Jun 2014.

This study was orally presented in the 11th Asia Pacific Congress of Cardiovascular and Interventional Radiology (APCCVIR 2014) in Singapore.

方法：回顧分析於2003年9月至2012年1月期間，香港新界東聯網兩間分區醫院中35名TRAS患者中的連續44例PTA（有或無支架）。評估及比較以下幾方面：技術成功率、併發症、血清肌酸酐水平、動脈血壓，以及術前術後服用的系列抗高血壓藥物量。並採用Kaplan-Meier方法估計移植物的存活率。

結果：44例手術（17例PTA和27例有支架PTA）中，35例為首次手術，其餘9例為再狹窄引起的二次手術。整體技術成功率為95.5%（PTA：88.2%；有支架PTA：100%）。手術中未觀察到嚴重併發症或移植物損失。但有四例輕微併發症，包括髂外動脈自限性離斷一例和穿刺部位血腫三例。PTA組和有支架PTA組在再狹窄率方面無顯著差異，前者25.0%，後者26.1%（ $p > 0.05$ ）。短期和中期觀察發現移植物功能障礙和高血壓兩方面持續改善，有移植物功能障礙（100%）和高血壓（94%）的病人的臨床成功率令人滿意。平均隨訪期70.3（標準差32.9）個月的數據顯示高血壓控制較為持續（84.6%），但肌酐水平控制只有部分持續（68.5%）。手術後同種異體移植物存活率為一年期100%和五年期97%。

結論：血流動力學對TRAS而言意義重大，經皮血管內介入治療對於此病來說既安全，又有高成功率；不但有利於移植腎功能和血壓的中短期改善，還有提高移植物存活率的長期效果。

INTRODUCTION

Transplant renal artery stenosis (TRAS) is a recognised and potentially treatable cause in post-transplant hypertension, allograft dysfunction, and even graft loss. Its incidence varies widely from 1% to 23%, depending on the definition and diagnostic techniques used.¹ Endovascular intervention, namely, percutaneous transluminal angioplasty (PTA) with or without stent placement is commonly the initial treatment of choice to restore kidney perfusion, apart from surgical intervention and conservative treatment. In the current study, we retrospectively evaluated the technical procedures, technical success rate, clinical success rate, and intermediate- and long-term clinical outcomes in patients with TRAS after percutaneous endovascular intervention in the Chinese population.

METHODS

Patient Group

From September 2003 to January 2012, 44 consecutive procedures including 17 PTA and 27 stenting in 35 patients were performed for TRAS in the Prince of Wales Hospital and North District Hospital in Hong Kong. The clinical diagnosis of TRAS was based on uncontrolled refractory or new-onset hypertension, or allograft dysfunction, and / or Doppler ultrasound suspicion.

Definitions of hypertension and renal insufficiency provided by Rundback et al² and Beecroft et al³ were adopted as below:

- Hypertension was considered if (i) blood pressure increased from baseline, (ii) there was accelerated hypertension (sudden worsening of previously controlled hypertension), or (iii) there was refractory hypertension (hypertension resistant to treatment with at least three medications of different classes).
- Elevated creatinine levels necessitating renal salvage defined as (i) sudden unexplained worsening of renal function (increased serum creatinine level of >10% over baseline), and / or (ii) impairment of renal function secondary to antihypertensive treatment.
- Doppler ultrasound criteria for significant TRAS included peak systolic velocity of >200 cm/s, with or without damped flow in the intrarenal arteries.

TRAS with haemodynamic significance was defined as angiographic luminal diameter stenosis of $\geq 50\%$,² or translesional pressure gradient of >15%.¹ Two patients with early graft failure due to acute graft rejection were excluded from our study. No single case was declined during the study period.

For cases with confirmed post-renal TRAS, local urologist surgeons have strong reservation for open surgery due to relatively high surgical risk and morbidity versus percutaneous endovascular intervention. Percutaneous endoluminal treatment was considered the first-line treatment in all cases. No single case of open surgery or auto retransplants was noted in

our centre during the study period.

Operators

A total of three chief operators were involved in our study. The majority of cases (>90%) were performed by an operator who had more than 10 years of experience in interventional radiology. The remaining two operators had around 5 years of experience at the time of performing the procedure.

Procedures

In each intervention, diagnostic transplant renal arteriography was initially performed via a femoral arterial approach in the majority of patients. Transbrachial approach was adopted in one patient due to infeasibility of femoral approach (Figure 1). An ipsilateral or contralateral femoral approach was chosen based on the type and angle of surgical anastomosis.

Non-selective ipsilateral iliac arteriography was performed to exclude any inflow or pre-anastomotic lesion and determine number of renal arteries, before the transplant renal artery was cannulated selectively, in postero-anterior or any other projection to best profile the stenosis. After proper calibration, percentage of stenosis was determined by the ratio of the diameter of the stenosed segment with that of a relatively normal segment of renal artery.

Nonionic iodinated contrast medium was utilised. The volume of contrast agent was kept to minimum to reduce the risk of nephrotoxicity. In the majority of cases, heparin sodium was administered intra-arterially (1000-3000 IU).

The stenoses were negotiated using a guidewire (either a 0.014 / 0.018 inch micro-guidewire or 0.035 Terumo guidewire), over which balloon angioplasty or self-expandable stent placement (range, 2.5-8 mm in diameter) or both were performed. Post-PTA or stenting arteriogram was obtained to evaluate technical success. Primary stenting was the preferred treatment of choice in angiographically confirmed TRAS, in consensus with the referring clinician. In some cases where anatomical problem of the anastomosis was a concern, balloon angioplasty was performed instead. In few cases of marginal TRAS, angioplasty was the only treatment offered. Among all the 27 stenting procedures, the majority (n = 21) were primary stenting, five were a combination of PTA and stent placement, and one involved stent insertion after unsuccessful PTA.

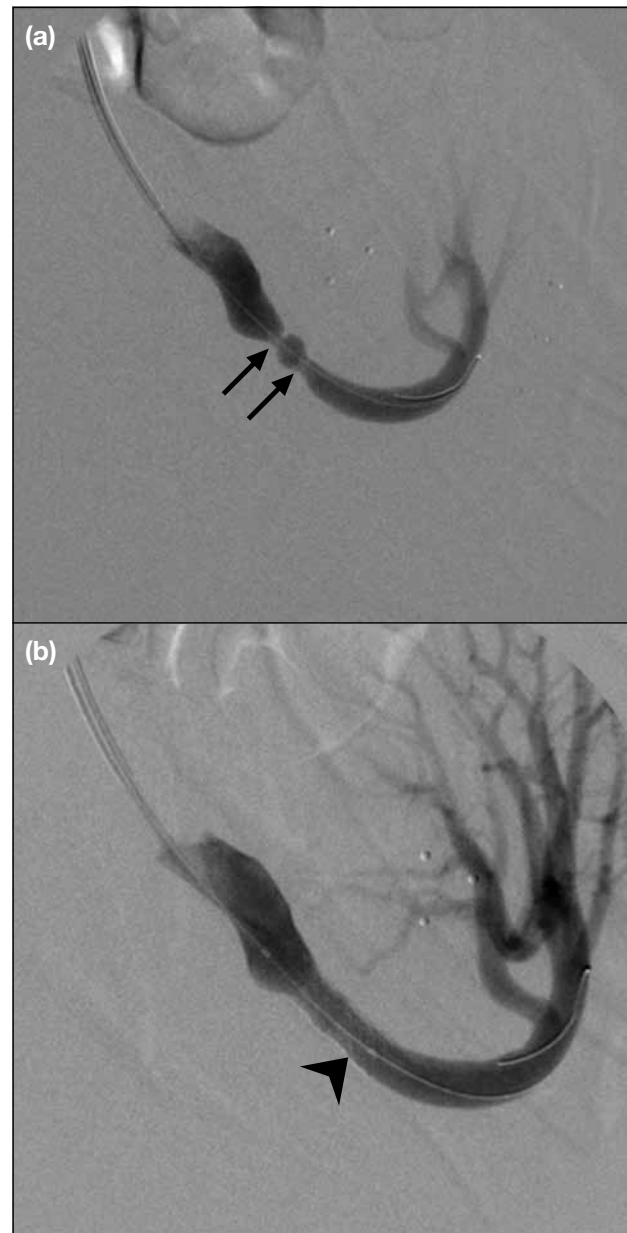


Figure 1. Endovascular intervention with stent implantation in transplant renal artery stenosis using left transbrachial approach in a second transplanted kidney at left iliac fossa with end-to-end anastomosis with left internal iliac artery. (a) Preliminary angiography shows two foci of severe stenosis (arrows) in the perianastomotic region and (b) a balloon-expandable metallic stent (arrowhead) is deployed across the stenosis over a micro-guidewire with restoration of vessel calibre.

All patients were treated with antiplatelet drugs (acetyl salicylic acid 80 mg to 160 mg) for an infinite period after the procedure.

Outcome Evaluation

Technical success, complications, clinical parameters

including dialysis-free graft survival, serum creatinine level, systolic arterial blood pressure (SBP) and diastolic arterial blood pressure (DBP), and number of antihypertensive medications before and after intervention were assessed and compared. Technical success after percutaneous intervention was defined as residual stenosis of <30%, no flow-limiting dissection, and a residual peak SBP gradient of <10% of the SBP across the lesion.^{2,3}

Complications were considered as procedure-related if documented within 30 days of the percutaneous intervention, and classified as major or minor based on criteria established by the Standards of Practice Committee of the Society of Interventional Radiology.⁴ Patient follow-ups were made in routine clinic visits, with blood pressure monitoring and blood investigations for serum creatinine obtained at 3 months, 1 year, and 2 years (blood pressure only). The mean of three consecutive serum creatinine levels before the intervention was obtained as baseline serum creatinine.

Clinical success was defined by (a) improvement — of >15% reduction in serum creatinine level; (b) stabilisation — within 10% of pretreatment serum creatinine value at 3 months' post-intervention³; (c) cure — DBP of <90 mm Hg and SBP of <140 mm Hg after stopping antihypertensive medications; or (d) improvement — DBP of <90 mm Hg and / or SBP of <140 mm Hg on the same or reduced number of medications; or a reduction in DBP by at least 15 mm Hg with the same or a reduced number of medications at 1 year post-intervention.²

Statistical Analysis

Two-tailed Student's *t*-test was employed to analyse the differences between the mean SBP and DBP, and mean serum creatinine level before and after intervention. The number of antihypertensive medications was compared with the use of Wilcoxon signed rank test. Graft survival was estimated using Kaplan-Meier method. Categorical variables were compared with contingency tables by means of chi-square test or Fisher's exact test. Statistical Package for the Social Sciences (SPSS) version 20 was used for analysis. The statistical significance level was defined as $p < 0.05$.

RESULTS

Baseline Patient Characteristics

The baseline demographic data are summarised in Table 1. The majority of the cohort had cadaveric

Table 1. Baseline demographic data.

| Demographics | All (n=35)* |
|--|---------------------------------|
| Mean age (years) | 49.5 ± 10.9 |
| Female:male | 12:23 |
| Cadaveric donor | 34 (97.1%) |
| Second transplant | 2 (5.7%) |
| Causes of transplantation | |
| Glomerulonephritis | 16 (45.7%) |
| Polycystic kidney disease | 4 (11.4%) |
| Others [†] | 9 (25.7%) |
| Unknown | 6 (17.1%) |
| End-to-side anastomosis to EIA | 28 (80.0%) |
| End-to-end anastomosis to IIA | 7 (20.0%) |
| 2 Renal arteries | 4 (11.4%) |
| 3 Renal arteries | 1 (2.9%) |
| Localisation of primary arterial stenosis [‡] | |
| Peri-anastomosis | 30 (85.7%) |
| Post-anastomosis | 6 (17.1%) |
| Pre-anastomosis | 1 (2.9%) |
| Median (range) time from transplant to diagnosis of TRAS | 6 months (3 days to 224 months) |

Abbreviations: EIA = external iliac artery; IIA = internal iliac artery; TRAS = transplant renal artery stenosis.

* Data are shown as mean ± standard deviation, No., or No. (%), unless otherwise stated.

[†] Including diabetes nephropathy (n = 2), renal stones disease (n = 2), systemic lupus erythematosus (n = 2), reflux nephropathy (n = 1), hypertensive nephrosclerosis (n = 1), and focal segmental glomerulosclerosis (n = 1).

[‡] Multiple sites of arterial stenosis were present in 4 patients.

renal transplantation (97.1%), with end-to-side arterial anastomosis to the external iliac artery (80.0%). Peri-anastomosis was the most common site of arterial stenosis (85.7%). The interval between renal transplantation and initial diagnosis of TRAS varied, ranging from 3 days to 224 months, with the median time being 6 months. The mean (± standard deviation [SD]) follow-up time was 70.3 ± 32.9 months.

Technical Outcome

Among the 44 interventions (17 PTA and 27 stenting) performed, 35 were primary interventions and the remaining nine were secondary treatments for re-stenosis. The overall technical success rate was 95.5%. Better technical success rate was yielded with stent insertion (100%) than with PTA (88.2%). No major complication or immediate graft loss during intervention was encountered. Four (9.1%) minor complications including a self-limiting, non-obstructive dissection in external iliac artery and three puncture site haematomas resolved on conservative treatment.

The overall re-stenosis rate in primary PTA or stenting

was 25.7%. There was no significant difference in the re-stenosis rate between the PTA (25.0%) and stenting (26.1%) groups ($p = 1.0$). Secondary patency was 100% with the nine secondary interventions (5 PTA, 4 stenting) at the last follow-up (mean \pm SD, 70.8 ± 36.0 months).

Clinical Outcome

Among the 22 cases presenting with graft dysfunction, the mean decrease in post-intervention serum creatinine level was $87 \mu\text{mol/l}$ (95% confidence interval [CI], 11.2-162.1) at 3 months ($p < 0.05$) and $55 \mu\text{mol/l}$ (95% CI, 18.5-91.8) at 1 year ($p = 0.005$). Clinical success rate was 100% in this group. There was a significant, though small, decrease in the mean creatinine level in all procedures ($n = 44$): $46 \mu\text{mol/l}$ (95% CI, 7.6-84.6) at 3 months ($P < 0.05$) and $24 \mu\text{mol/l}$ (95% CI, 2.9-45.8) at 1 year ($p < 0.05$).

In the 16 cases presenting with hypertension, significant improvement in post-procedure SBP was observed at 3 months (mean \pm SD decrease, 14 ± 16.7 mm Hg, $p < 0.05$), 1 year (15 ± 15.8 mm Hg, $p = 0.005$), and 2 years (16 ± 16.1 mm Hg, $p < 0.005$). Significant drop in DBP was only present at 3 months after intervention, with a mean decrease of 5 ± 7.8 mm Hg ($p < 0.05$). These patients required a mean of 4.2 ± 1 medications for blood pressure control, compared with a mean of 3.4 ± 1 antihypertensive medications after intervention ($p < 0.05$). Clinical success rate was 94% in this hypertensive

group achieving improvement in blood pressure control.

Among all the 44 procedures, statistically significant decrease in both SBP and DBP was observed at 3 months, 1 year, and 2 years post-intervention ($p < 0.05$), and in creatinine level at 3 months and 1 year ($p < 0.05$) [Table 2].

Among the six asymptomatic patients with TRAS diagnosed by abnormal Doppler sonographic findings (mean peak systolic velocity, 439 ± 138 cm/s), the serum creatinine levels and blood pressure control remained stable after the intervention at 3 months and 1 year, respectively.

No patient mortality or cardiovascular mortality was observed till the last follow-up (mean, 70.8 ± 36.0 months).

Four graft losses were encountered during follow-up at 25 to 112 months (Table 3). Two had recurrence of initial disease; one had cholesterol embolism which could be attributed to both the prior renal artery stenosis and the associated hypertension; one had chronic deterioration due to unknown cause, with no recurrent TRAS and biopsy showing no acute rejection.

Estimated dialysis-free allograft survival after endoluminal intervention was 100% at 1 year and 97% at 5 years (Figure 2). There was no significant difference

Table 2. Changes in serum creatinine level and blood pressure following percutaneous renal revascularisation.

| | Mean \pm standard deviation | | | |
|--|-------------------------------|----------------|----------------|----------------|
| | Baseline | 3 Months | 1 Year | 2 Years |
| Serum creatinine ($\mu\text{mol/l}$) | 193 ± 134 | $147 \pm 57^*$ | $153 \pm 56^*$ | N/A |
| Systolic blood pressure (mm Hg) | 147 ± 17 | $133 \pm 17^*$ | $133 \pm 13^*$ | $130 \pm 14^*$ |
| Diastolic blood pressure (mm Hg) | 83 ± 11 | $77 \pm 12^*$ | $76 \pm 12^*$ | $75 \pm 11^*$ |

Abbreviation: N/A = not available.

* $p < 0.05$ comparing with baseline values.

Table 3. Causes and duration of graft loss in TRAS after PTA/stenting.

| Patient No. | Cause of graft loss | Duration (months) | Initial presentation | Intervention |
|-------------|--|-------------------|----------------------|--------------------------|
| 1 | Unknown | 112 | \uparrow Cr | PTA |
| 2 | Recurrence of initial disease (focal segmental glomerulosclerosis) | 71 | \uparrow Cr | PTA + secondary stenting |
| 3 | Recurrence of initial disease (IgA nephropathy) | 97 | \uparrow Cr | PTA |
| 4 | Cholesterol embolism | 25 | Hypertension | Stenting |

Abbreviations: Cr = creatinine; IgA = immunoglobulin A; PTA = percutaneous transluminal angioplasty; TRAS = transplant renal artery stenosis.

in graft survival between primary and secondary intervention groups ($p > 0.05$) as shown in Figure 3.

In the long term, persistent improvement (45.7%) or stabilisation (22.8%) of creatinine level was sustained

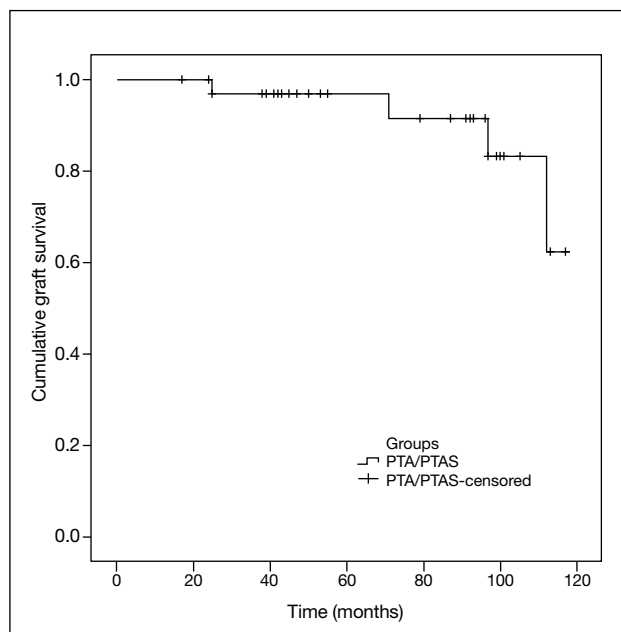


Figure 2. Long-term graft survival in patients with percutaneous transluminal angioplasty (PTA) or PTA with stenting (PTAS).

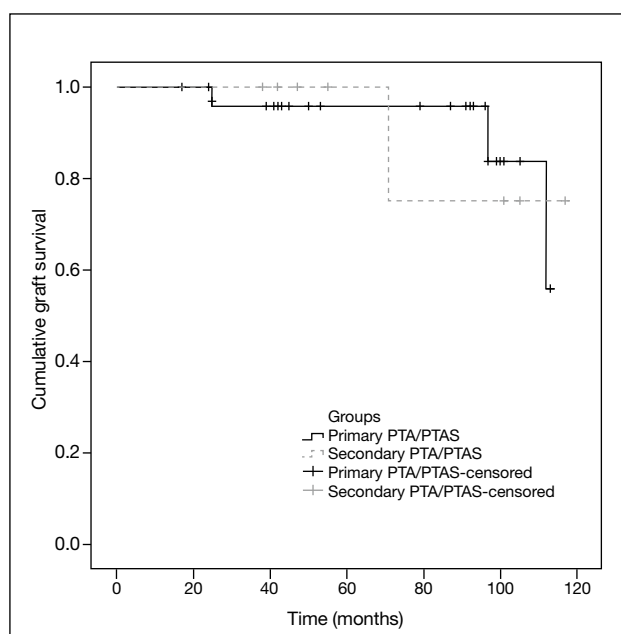


Figure 3. Long-term graft survival in patients with primary intervention and secondary intervention. Abbreviations: PTA = percutaneous transluminal angioplasty; PTAS = percutaneous transluminal angioplasty with stenting.

in 68.5% of all patients at the last follow-up, while deterioration (20.0%) or graft failure (11.4%) occurred in 31.4%. Long-term clinical success in hypertensive control was sustained in 84.6% of the 13 patients presenting with hypertension (improvement in 53.8%, stabilisation in 30.8%) at the last follow-up.

DISCUSSION

Percutaneous intervention is nowadays commonly advocated for the primary treatment of TRAS, while surgical revascularisation generally has been reserved for patients not amenable to percutaneous intervention. Surgical dissection of the renal and iliac vessels is technically demanding, accounted by the variable anatomy and extensive fibrosis that frequently develops around the kidney which nearly always involves the renal vessels.⁵ Surgery carries a significant risk of graft loss (up to 15% to 20%), ureteral injury (14%), re-operation (13%), and mortality (5%).¹ On the other hand, reported complications in endovascular intervention occur in up to 10% of cases, including haematoma at femoral artery puncture site, intimal flaps, arterial rupture, arterial dissection, and thrombosis.¹ Contrast hypersensitivity and nephropathy are also potential complications upon intravenous contrast use. No significant complications were recorded in our study, except a self-limiting, non-obstructive dissection in the external iliac artery and three puncture site haematomas in the groin (9.1%).

A number of observational studies have illustrated the potential benefits of endoluminal intervention in TRAS. Relevant studies in recent 10 years generally favoured an improved hypertension control and creatinine levels (Table 4).^{3,6-14} Some also demonstrated improved glomerular filtration rate. These studies, however, generally comprised a small sample size with 8 to 26 patients or interventions.^{3,6-8,11-14} One of these studies with a larger sample size of 62 PTA/stenting elicited an early statistically significant ($p < 0.05$) drop in creatinine and blood pressure only at 1 month after the procedure but not at 6 or 12 months.¹⁰ Another study with 32 stenting procedures and long follow-up of a mean of 85.2 months, however, lacked statistical correlation and support.⁹ Two of these studies were conducted among Chinese populations,^{8,12} and were, again, limited by a small sample size. In our current study, we recruited a relatively bigger sample size of 44 PTA/stenting with a relatively long follow-up period (mean, 70.3 months) in the Chinese population. We demonstrated a persistent, statistically significant improvement in creatinine

Table 4. Summary of studies investigating endoluminal treatment of transplant renal artery stenosis in recent 10 years.^{3,6-14}

| Study | No. of interventions | Procedure | Follow-up (months) | Outcome |
|------------------------------------|----------------------|-----------|--------------------|----------------|
| Beecroft et al, ³ 2004 | 21 | PTA/stent | 27 (mean) | BP↓ and Cr↓* |
| Salvadori et al, ⁶ 2005 | 26 | stent | 43.3 (mean) | BP↓ and Cr↓ |
| Ridgway et al, ⁷ 2006 | 13 | stent | 4.6 (median) | BP↓ and GFR↑ |
| Chow et al, ⁸ 2007 | 18 | PTA/stent | 21.6 (mean) | BP↓ and GFR ~ |
| Valpreda et al, ⁹ 2008 | 32 | stent | 85.2 (mean) | BP↓ and Cr↓† |
| Marini et al, ¹⁰ 2011 | 62 | PTA/stent | 39 (median) | BP↓ and Cr↓† |
| Sharma et al, ¹¹ 2011 | 8 | stent | 68.4 (mean) | BP↓ and Cr↓ |
| Su et al, ¹² 2012 | 18 | stent | 85.2 (mean) | BP↓, Cr↓, GFR↑ |
| Del Pozo et al, ¹³ 2012 | 13 | stent | 180 (mean) | BP↓, Cr↓, GFR↑ |
| Guzzardi et al, ¹⁴ 2013 | 17 | PTA/stent | 28.3 (mean) | BP↓ and Cr↓ |
| Present study | 44 | PTA/stent | 70.3 (mean) | BP↓ and Cr↓ |

Abbreviations: BP = blood pressure; Cr = creatinine; GFR = glomerular filtration rate; PTA = percutaneous transluminal angioplasty.

* Short-term outcome at 1 month.

† No p value was calculated to indicate statistical significance.

‡ Statistical significance ($p < 0.05$) was only detected in 1-month postprocedure value but not in 6- or 12-month values.

and blood pressure in both short and intermediate term. High clinical success rates were observed in patients presenting with graft dysfunction (100%) and hypertension (94%).

Nevertheless, long-term outcome of renal allograft after endoluminal intervention is still poorly documented, with conflicting observations. Ghazanfar et al¹⁵ reported an improved 5-year graft survival rate of 86% in 44 patients with PTA versus patients undergoing surgery or conservative medical treatment. On the contrary, Audard et al¹⁶ reported significantly worse transplant survival in 29 patients undergoing angioplasty with or without stenting for TRAS compared with controls without TRAS, partly attributed to three immediate graft losses which were procedure-related.¹⁶ Our data aided to support a favourable long-term outcome after percutaneous intervention, with high estimated dialysis-free allograft survival of 97% at 5 years. Long-term clinical success in hypertensive control was relatively sustained (84.6%) while that in creatinine level it was only partially sustained (68.5%) with a mean follow-up duration of 70.3 months.

We observed no significant difference in re-stenosis rates between PTA (25%) and stenting (26.1%) groups. This is in contrast to some studies which found an increased re-stenosis rate in PTA without stent placement. One study reported a re-stenosis rate of up to 62% in a group of 21 patients undergoing PTA with a mean follow-up of 95.8 months, compared with 30% in 10 stent implantation procedures.¹⁷ Yet, we reported a relatively higher technical success rate

with stent insertion (100%) versus PTA (88.2%). Non-randomisation of patients undergoing PTA or stenting is a potential limitation for a fair, direct comparison between the stenting and non-stenting groups. Further large-scale randomised controlled trials are required to justify any long-term outcome benefit of PTA with stenting over no stenting.

CONCLUSION

Our study suggests that percutaneous endoluminal intervention for haemodynamically significant TRAS is a safe procedure with high technical success, showing beneficial effects in improving allograft function and blood pressure in the short and intermediate term, as well as a good long-term graft survival and sustained clinical success in hypertensive control in the Chinese population. Long-term clinical success in improving or stabilising graft dysfunction, however, was partially sustained.

REFERENCES

1. Fervenza FC, Lafayette RA, Alfrey EJ, Petersen J. Renal artery stenosis in kidney transplants. *Am J Kidney Dis.* 1998;31:142-8. [crossref](#)
2. Rundback JH, Sacks D, Kent KC, Cooper C, Jones D, Murphy T, et al. Guidelines for the reporting of renal artery revascularization in clinical trials. *J Vasc Interv Radiol.* 2003;14(9 Pt 2):S477-92. [crossref](#)
3. Beecroft JR, Rajan DK, Clark TW, Robinette M, Stavropoulos SW. Transplant renal artery stenosis: outcome after percutaneous intervention. *J Vasc Interv Radiol.* 2004;15:1407-13. [crossref](#)
4. Sacks D, McClenny TE, Cardella JF, Lewis CA. Society of Interventional Radiology clinical practice guidelines. *J Vasc Interv Radiol.* 2003;14(9 Pt 2):S199-202. [crossref](#)
5. Gray DW. Graft renal artery stenosis in the transplanted kidney. *Transplant Rev (Orlando).* 1994;8:15-21. [crossref](#)

6. Salvadori M, Di Maria L, Rosati A, et al. Efficacy and safety of Palmaz stent implantation in the treatment of renal artery stenosis in renal transplantation. *Transplant Proc.* 2005;37:1047-8. [cross ref](#)
7. Ridgway D, White SA, Nixon M, Carr S, Blanchard K, Nicholson ML. Primary endoluminal stenting of transplant renal artery stenosis from cadaver and non-heart-beating donor kidneys. *Clin Transplant.* 2006;20:394-400. [cross ref](#)
8. Chow KM, Szeto CC, Lee PS, Ho SS, Leung CB, Li PK. Revascularization for post-transplant renal artery stenosis. *Nephrology (Carlton).* 2007;12:406-12. [cross ref](#)
9. Valpreda S, Messina M, Rabbia C. Stenting of transplant renal artery stenosis: outcome in a single center study. *J Cardiovasc Surg (Torino).* 2008;49:565-70.
10. Marini M, Fernandez-Rivera C, Cao I, et al. Treatment of transplant renal artery stenosis by percutaneous transluminal angioplasty and/or stenting: study in 63 patients in a single institution. *Transplant Proc.* 2011;43:2205-7. [cross ref](#)
11. Sharma S, Potdar A, Kulkarni A. Percutaneous transluminal renal stenting for transplant renal artery stenosis. *Catheter Cardiovasc Interv.* 2011;77:287-93. [cross ref](#)
12. Su CH, Lian JD, Chang HR, et al. Long-term outcomes of patients treated with primary stenting for transplant renal artery stenosis: a 10-year case cohort study. *World J Surg.* 2012;36:222-8. [cross ref](#)
13. Del Pozo M, Martí J, Guirado L, et al. Angioplasty and stent treatment of transplant renal artery stenosis [in Spanish]. *Nefrologia.* 2012;32:455-8.
14. Guzzardi G, Fossaceca R, Di Gesù I, et al. Endovascular treatment of transplanted renal artery stenosis with PTA/stenting. *Radiol Med.* 2013;118:826-36. [cross ref](#)
15. Ghazanfar A, Tavakoli A, Augustine T, Pararajasingam R, Riad H, Chalmers N. Management of transplant renal artery stenosis and its impact on long-term allograft survival: a single-centre experience. *Nephrol Dial Transplant.* 2011;26:336-43. [cross ref](#)
16. Audard V, Matignon M, Hemery F, et al. Risk factors and long-term outcome of transplant renal artery stenosis in adult recipients after treatment by percutaneous transluminal angioplasty. *Am J Transplant.* 2006;6:95-9. [cross ref](#)
17. Voiculescu A, Schmitz M, Hollenbeck M, et al. Management of arterial stenosis affecting kidney graft perfusion: a single-centre study in 53 patients. *Am J Transplant.* 2005;5:1731-8. [cross ref](#)