Hong Kong J Radiol. 2014;17:285-92 | DOI: 10.12809/hkjr1413197

PICTORIAL ESSAY

Aortic Root Anatomy and Diagnosis of Pathological Conditions by Multidetector Computed Tomography

WK Tsang[1], A Li[2], YC Wong[3]

[1]Department of Radiology and Imaging, Queen Elizabeth Hospital, Jordan, Hong Kong, [2]Department of Radiology, North District Hospital, Sheung Shui, Hong Kong, and [3]Department of Radiology, Tuen Mun Hospital, Tuen Mun, Hong Kong

ABSTRACT

Multidetector (MD) cardiac computed tomography (CT) imaging has emerging use in the assessment of the anatomy and function of the heart. Apart from its established role in the evaluation of the coronary arteries, MDCT can also accurately assess the aortic root. This pictorial essay serves to present the use of MDCT in the evaluation of normal anatomy of the aortic root and its various pathological conditions.

Key Words: *Aneurysm; Aneurysm, false; Bicuspid aortic valve; Coronary aneurysm; Sinus of Valsalva*

中文摘要

利用多層螺旋電腦斷層掃描剖析主動脈根部解剖結構和病理狀況

曾慧勤、李子飛、王耀忠

心臟的多層螺旋（MD）電腦斷層掃描（CT）成像在評估心臟結構和功能方面很有價值。除評估冠狀動脈的作用被肯定外，MDCT也可以準確評估主動脈根部。本圖案回顧旨在顯示MDCT於評估主動脈根部的正常解剖結構及其各種病理狀況的應用。

INTRODUCTION

Multidetector (MD) cardiac computed tomography (CT) imaging is an important tool in the assessment of coronary artery stenosis. Apart from coronary artery, cardiac CT is also helpful in assessing the aortic root; the pathologies of which can mimic coronary artery diseases which are sometimes fatal.[1] This pictorial essay serves to present the use of MDCT in the evaluation of normal anatomy of the aortic root as well as its various pathological conditions.

NORMAL ANATOMY

The aortic valve is a tricuspid valve which, normally, has three leaflets. It shows tri-radiating lines of apposition between adjacent leaflets during valve closure. The 'aortic root' refers to the aortic valve from its position at the left ventricular outlet to the ventriculo-aortic junction (VAJ). Functionally, this whole complex structure is the aortic valve (Figure 1).[2]

The aortic root bulges outwards to form three

Correspondence: *Dr WK Tsang, Department of Radiology and Imaging, Queen Elizabeth Hospital, Jordan, Hong Kong. Tel: (852) 2958 2688; Email: tsang_k@yahoo.com.hk*

Submitted: 30 Jul 2013; Accepted: 6 Feb 2014.

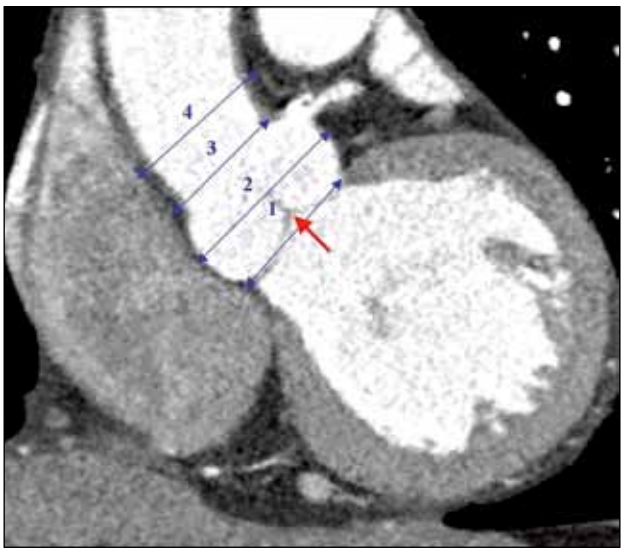

Figure 1. Normal aortic root. An oblique coronal image of multidetector computed tomography coronary angiography shows the structures of aortic root. 1 = annulus, 2 = sinus of Valsalva, 3 = sinotubular junction, 4 = ascending aorta; red arrow = valve commissure.

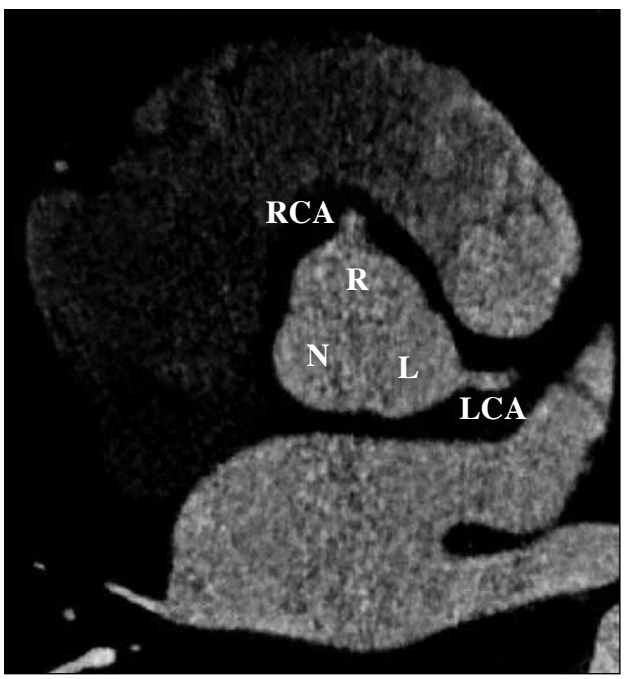

Figure 2. Normal sinus of Valsalva (SOV). An oblique axial image of multidetector computed tomography coronary angiography obtained at the level of the aortic valve shows the SOVs and coronary arteries.
Abbreviations: L = left coronary cusp; LCA = left coronary artery; N = non-coronary cusp; R = right coronary cusp; RCA = right coronary artery.

dilatations, the aortic sinuses or sinuses of Valsalva (SOV) [Figure 2]. The SOVs lie within the pericardial sac and at the centre of the heart. The superior border of SOV is the sinotubular junction. It has a slightly scalloped outline as it follows the contour of the three sinuses. Two of the SOVs give rise to the main coronary arteries and are nominated as the coronary sinuses. The right coronary sinus locates anteriorly while the left coronary sinus locates posteriorly to the left. The right posterior SOV does not give rise to the coronary artery and is called the non-coronary sinus. During systole, the left ventricular pressure exceeds the aortic pressure and the valvular leaflets are pushed apart. The SOVs provide enough space for the leaflets to fall back without directly striking the aortic wall and allow free ejection of blood. The orifices of the coronary arteries are commonly close to the level of the sinotubular junction. As the free edges of the valvular leaflets are at a lower level than their corresponding sinuses, when the aortic valve opens, the leaflets fall back into their sinuses without occluding the coronary orifices. During diastole, the sinuses act as reservoirs and allow filling of the coronary arteries. As the height of the right coronary sinus is greater than that of the rest of the SOVs, the difference of the heights of the sinuses causes a small tilt angle (approximately 5.47°) between the sinotubular junction and the aortic root base.[3]

Table 1. Normal dimensions of aortic root structures.

Size (end diastole)	Measurement made	Normal range (cm)
Annulus	Internal diameter	1.4-2.6
Sinus of Valsalva	External diameter	2.1-3.5
Sinotubular junction	External diameter	1.7-3.4
Ascending aorta	External diameter	2.1-3.4

An accurate measurement of the aortic annulus is mandatory for optimal sizing of prosthesis in the percutaneous aortic valve replacement (Table 1).[4] The aortic annulus is defined as a virtual ring at the aortic root where the nadirs of the basal attachment (hinge-lines) of the valvular leaflets locate. It is often elliptical rather than circular. Anatomically, there are controversies regarding the presence of a histological aortic annulus. Some authors regard it as an ill-founded or non-existent virtual structure while others assert its presence, microscopically, at the interleaflet triangles.[2,3]

The anatomical VAJ is the transition between the ventricular myocardium and the aortic wall. Apart from the site of aortic-mitral valvular continuity, more than half of the VAJ is formed by the central fibrous body. Therefore, it is impossible to define the exact location of the anatomical VAJ. Due to the semilunar configuration of the hingelines, the anatomical and functional VAJs

do not coincide. The hingelines extend throughout the root with their nadirs below the anatomical VAJ and their distal attachments at the sinutubular junction. As a result, haemodynamically, the ventricular parts within the aortic sinuses become part of the aorta. In contrast, though the three pieces of aortic wall between the arcs lie above the anatomical VAJ, functionally, they incorporate into part of the ventricle during valvular closure. They are known as the interleaflet fibrous triangles. Compared with the hingelines and the sinusal walls, the interleaflet fibrous triangles are thinner and less collagenous. Thus they are at a higher risk of aneurysm formation.

The semilunar hingelines of adjacent leaflets meet at the level of the sinotubular junction, forming the commissures. When the aortic valve closes, the ventricular sides of the leaflet-free edges meet. This zone of apposition is called the lunule. At the midportion, it is thickened and forms the nodule of Arantius.

AORTIC ROOT PATHOLOGY

Sinus of Valsalva Aneurysm

Sinus of Valsalva aneurysm (SVA) is a rare condition related to weakness of the elastic connective tissue at the junction of the aortic media and the annulus.[3,5] Congenital causes include underlying deficiency of normal elastic tissue like in those with Marfan and Ehlers-Danlos syndromes. Acquired SVAs are most commonly related to infection, degeneration, or trauma.

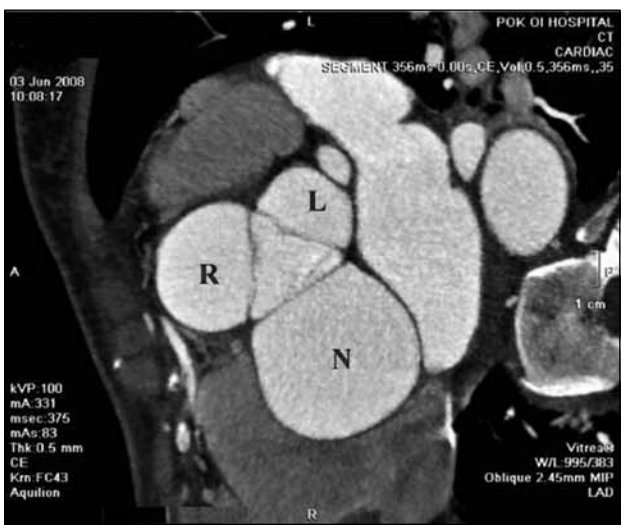

Figure 3. An oblique axial image obtained at the level of the aortic valve demonstrates patulous right (R) and left (L) coronary cusps and a wide-neck sinus of Valsalva aneurysm of the non-coronary cusp (N).

Figure 4. An oblique sagittal image of multidetector computed tomography coronary angiography shows a wide-neck sinus of Valsalva aneurysm of the non-coronary cusp (N).

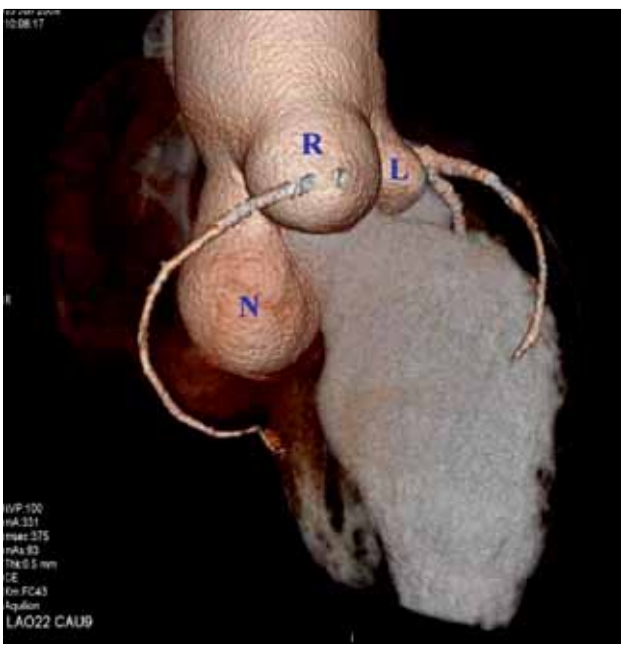

Figure 5. Multidetector computed tomography coronary angiography with volume-rendered image demonstrates patulous right (R) and left (L) coronary cusps and a wide-necked sinus of Valsalva aneurysm of the non-coronary cusp (N).

Non-ruptured SVAs may be asymptomatic, or they may present acutely with mass effect on adjacent cardiac structures. As the SOVs are located at the centre of the heart and within the pericardial sac, a ruptured SVA can open into a cardiac chamber or pericardial space. Right coronary sinus is the most commonly involved SOV in ruptured SVA, which opens into the right atrium or the right ventricular outflow tract.[2] Ruptured SVAs result in aortocardiac shunt and may manifest as progressive congestive heart failure, severe acute chest pain with dyspnoea, or even cardiac arrest. In general, symptomatic or large SVAs should be repaired to avoid complications, whereas small asymptomatic SVAs may be monitored.

Illustrative Cases

Sinus of Valsalva Aneurysm with Patulous Right and Left Coronary Cusps

In a 48-year-old woman with an 8-year history of moderate aortic regurgitation, CT coronary angiography showed patulous right and left coronary cusps and a wide-neck SVA of the non-coronary cusp (Figures 3 to 5).

Acute Ruptured Sinus of Valsalva Aneurysm

A 49-year-old man presented with haemoptysis during his treatment for tuberculous spondylodiscitis. Chest radiograph showed congested lung fields. Echocardiogram revealed flail aortic valve with moderate aortic regurgitation, aortic valvular leaflet thickening and vegetations. Features were compatible with infective endocarditis. CT coronary angiogram showed prolapsed aortic valve and a lobulated wide-necked aneurysm arising from the undersurface of the right coronary sinus. A fistula connecting the basal aspect of the aneurysm to the right atrium was noted (Figure 6). Overall features were consistent with ruptured SVA with fistula to the right atrium.

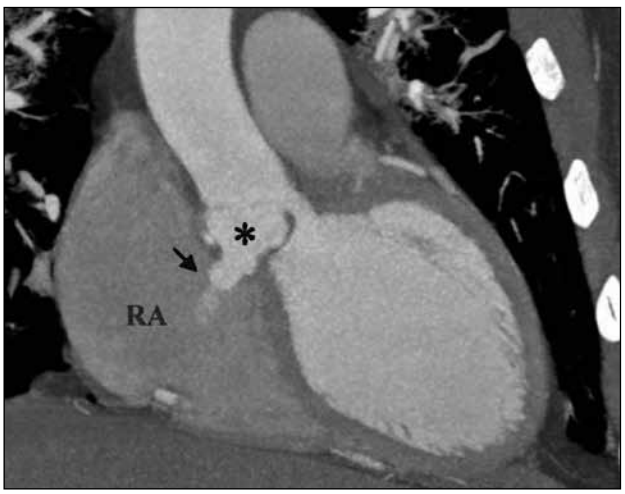

Figure 6. Multidetector computed tomography coronary angiography with multiplanar reconstruction in oblique coronal view demonstrates sinus of Valsalva aneurysm (SVA) (*) with contrast jet (arrow) directed towards the right atrium (RA), consistent with ruptured SVA with fistula into the right atrium.

Sinus of Valsalva Pseudoaneurysm

Infective SOV pseudoaneurysm is a rare condition resulting from extension of infection from a paravalvular myocardial abscess complicating endocarditis.[6] Clinically, patients have insidious onset of vague symptoms. Complications include rupture or formation of fistula to the right heart with left-to-right shunt. Prognosis is poor if untreated. MDCT could be helpful in detection and preoperative planning of surgery in infective endocarditis.[7] It correlates well with transesophageal echocardiography (TEE) and intraoperative findings in the detection of valvular vegetations, demonstration of their mobility, and diagnosis of paravalvular abscesses / pseudoaneurysms. Compared with TEE, CT is superior in providing anatomical information regarding perivalvular extent of the abscess / pseudoaneurysm.[7]

Illustrative Case

Sinus of Valsalva Pseudoaneurysm with Aortic Root Abscess

A 30-year-old man with a history of substance abuse presented with subacute onset of dyspnoea. Physical examination found ejection diastolic murmur at the left lower sternal border. Coronary CT angiogram demonstrated a huge narrow-necked contrast-filled sac arising from the left SOV, suggestive of SOV pseudoaneurysm (Figure 7). Soft tissue infiltrates in the mediastinal spaces surrounding the aortic arch and roots of the great vessels raised the suspicion of mediastinitis and aortic root micro-abscesses (Figure 8).

Bicuspid Aortic Valve

Bicuspid aortic valve (BAV) is the most common congenital anomaly of the aortic valve, resulting from complex abnormal cusp formation during valvulogenesis.[8,9] Since BAV causes premature fibrosis and calcification of the aortic valves, aortic stenosis is the most common complication.[10] The classical bicuspid valve shows two symmetrical aortic cusps. During diastole, the open BAV assumes a typical ellipsoid shape. Aortic stenosis of the bicuspid valve presents at an age range of 30 to 50 years, earlier than

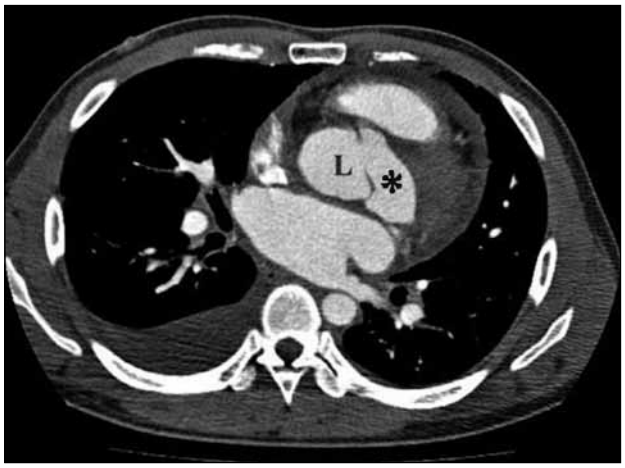

Figure 7. An axial image of multidetector computed tomography coronary angiography shows a huge narrow-necked contrast-filled sac (*) from the left sinus of Valsalva (L), suggestive of sinus of Valsalva pseudoaneurysm.

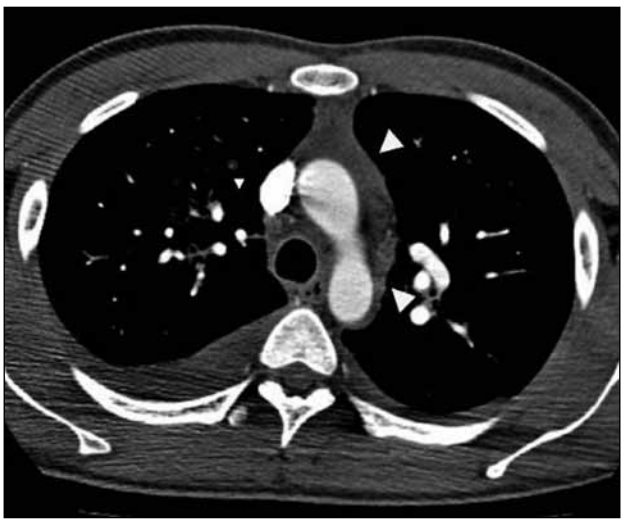

Figure 8. Soft tissue infiltrates (arrowheads) in the mediastinal spaces surrounding the aortic arch and root of the great vessels raise the suspicion of mediastinitis and aortic root micro-abscesses.

those caused by degeneration. In the evaluation of patients with bicuspid valves that require valve repair, the degree of calcification of the valve is important as coronary implantation and aortic root replacement may be indicated in those with significant calcification.

Illustrative Case

Bicuspid Aortic Valve with Ascending Aortic Aneurysm

A 53-year-old woman with aortic stenosis and regurgitation was noted to have dilated aortic root on echocardiography. Preoperative cardiac CT showed thickened, calcified BAV with incomplete closure (Figure 9). Fusiform, ascending aortic aneurysm and concentric left ventricular hypertrophy were also revealed (Figure 10).

Coronary Artery Anomalies

Congenital anomalies of the coronary arteries are uncommon yet important causes of chest pain, with prevalence of 0.3% to 1% in the general population. They can be classified anatomically according to their

Figure 9. Multidetector computed tomography coronary angiography with multiplanar reconstruction image in oblique sagittal view demonstrates bicuspid aortic valve with thickening and calcification (arrowheads).

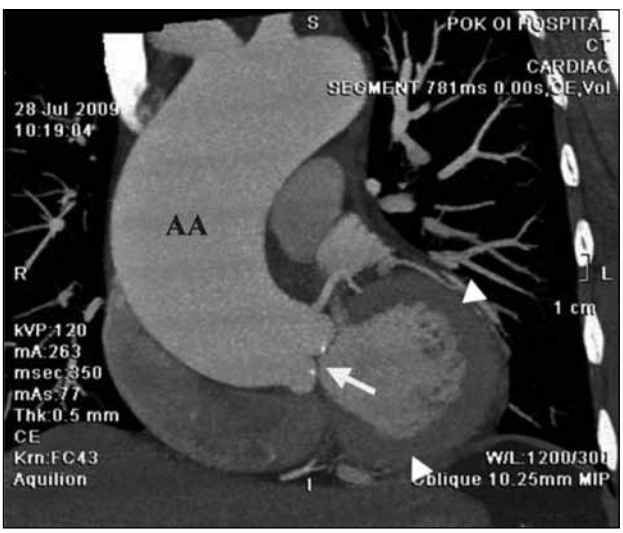

Figure 10. Multidetector computed tomography coronary angiography with multiplanar reconstruction image demonstrates bicuspid aortic valve with thickening and calcification (arrow), fusiform ascending aortic aneurysm (AA) and concentric left ventricular hypertrophy (arrowheads).

origin, course, and termination.[11] They could also be divided as haemodynamically significant or insignificant (Table 2). The former ones are characterised by abnormalities of myocardial perfusion, which lead to an increased risk of myocardial ischaemia or sudden death.

Illustrative Cases

Anomalous Right Coronary Artery with Malignant Course

CT coronary angiography of a 57-year-old woman with chest pain revealed common origin of the right coronary artery (RCA) and left coronary artery from the left coronary cusp (Figure 11). The proximal RCA ran between the pulmonary trunk and aortic root, consistent with an anomalous origin of RCA with 'malignant' interarterial course (Figure 12).

Separate Left Anterior Descending and Left Circumflex Arteries

CT coronary angiography of a 79-year-old woman revealed separate ostia of the left anterior descending artery and left circumflex artery arising from the left coronary sinus. This is a normal variant without haemodynamic effect upon coronary perfusion (Figure 13). No adverse cardiac event was documented in this patient in the subsequent 4 years.

Coronary Artery Aneurysm with Associated Fistula

Coronary artery aneurysm (CAA) is defined as a coronary artery segment with diameter that exceeds the diameter of adjacent normal coronary segments; or the diameter of the patient's largest coronary vessel by 1.5 times and involves less than 50% of the total length of the vessel.[12-14] Coronary artery fistula (CAF) is defined as a direct precapillary connection between a branch of a coronary artery and the lumen of a cardiac chamber, the coronary sinus, the superior vena cava,

Table 2. Coronary artery anomalies.*

Anomalies of origin
• High takeoff
• Multiple ostia
• Single coronary artery
• **Anomalous origin of coronary artery from pulmonary artery**
• Origin of coronary artery or branch from opposite or noncoronary sinus and an anomalous (retroaortic, interarterial, **prepulmonic**, septal [subpulmonic]) course
Anomalies of course
• **Myocardial bridging**
• Duplication of arteries
Anomalies of termination
• Coronary artery fistula
• Coronary arcade
• Extracardiac termination

* Those in bold are haemodynamically significant which could lead to abnormal myocardial perfusion and even sudden death.

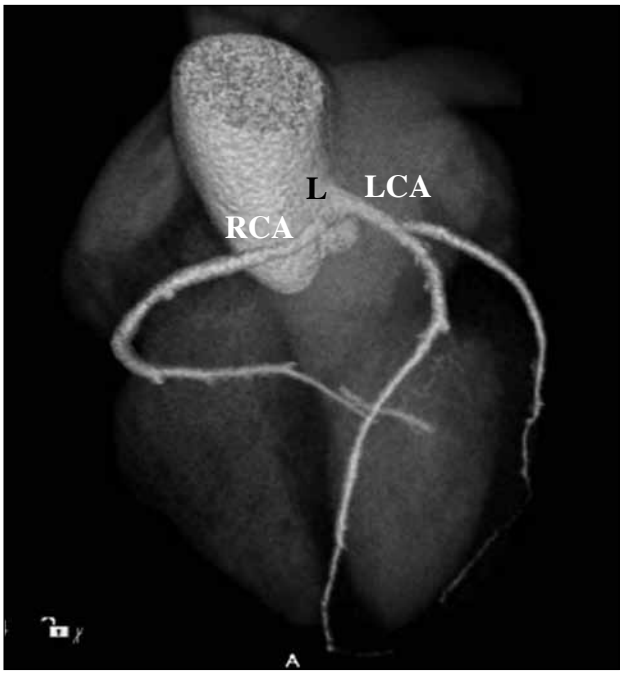

Figure 11. Common origin of right coronary artery (RCA) and left coronary artery (LCA) from the left coronary cusp (L).

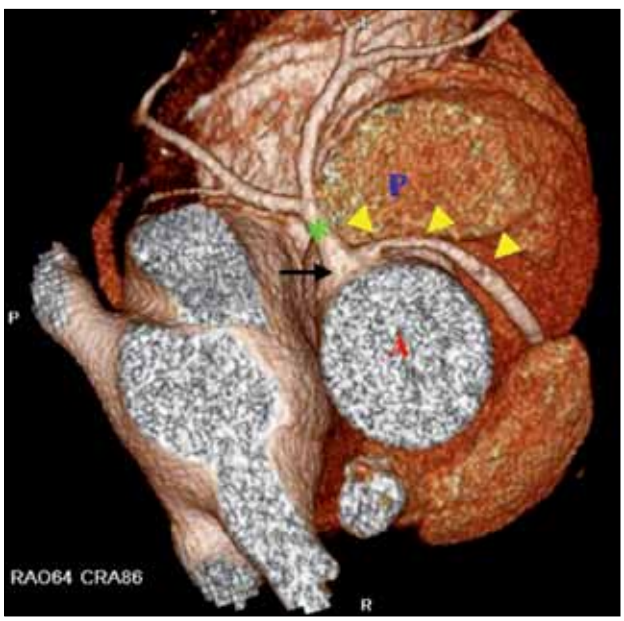

Figure 12. Multidetector computed tomography coronary angiography with volume-rendered image. Common origin (black arrow) of right coronary artery (RCA) and left coronary artery (*) from the left coronary cusp. The proximal RCA (arrowheads) runs between the pulmonary trunk (P) and aortic root (A), consistent with 'malignant' interarterial course.

Figure 13. Separate ostia of left anterior descending artery and left circumflex coronary artery from left coronary sinus. This is considered a normal variant without haemodynamic effect on coronary perfusion.

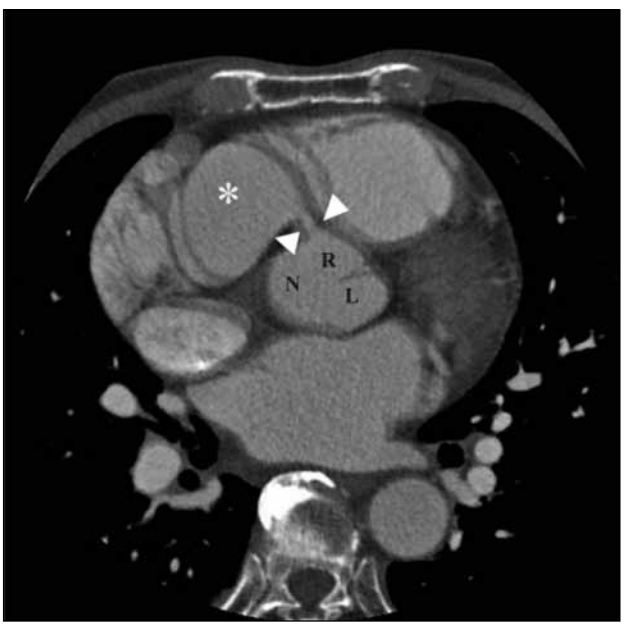

Figure 14. A huge fusiform aneurysm (*) arising from the proximal right coronary artery (arrowheads).
Abbreviations: L = left coronary cusp; N = non-coronary cusp; R = right coronary cusp.

a pulmonary artery or pulmonary vein close to the heart.[15] Approximately 3% of CAFs are associated with CAA, a rare condition with only about 50 cases reported in the English literature. It is congenital in most cases. Acquired causes include complications of previous open-heart surgery, endomyocardial biopsy,

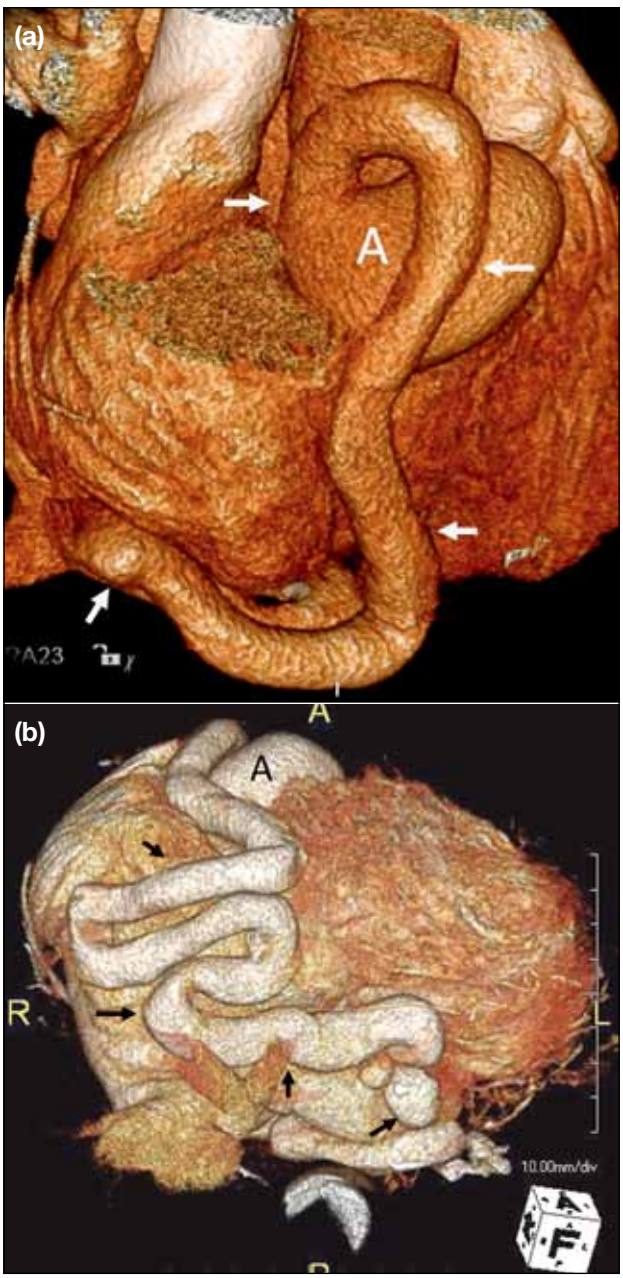

Figure 15. Volume-rendered images of multidetector computed tomography coronary angiography: (a) coronal oblique and (b) axial oblique. There is a huge fusiform aneurysm arising from the proximal right coronary artery with direct drainage into the coronary sinus and the inferior aspect of the heart via a large fistula (arrows). Features are compatible with coronary artery aneurysm with associated fistula.
Abbreviation: A = right coronary artery aneurysm.

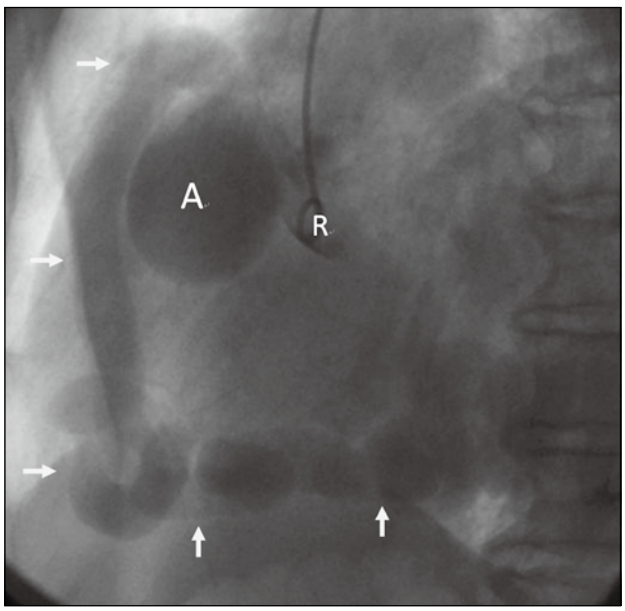

Figure 16. A selected image of the right coronary angiogram; right coronary artery fistula (arrows) is shown.
Abbreviations: A = right coronary artery aneurysm; R = right coronary sinus (with courtesy of Cardiology team, Department of Medicine and Geriatrics, Tuen Mun Hospital).

percutaneous transluminal coronary angioplasty, myocardial infarction, and trauma. One-third of the patients with coronary artery aneurysm with associated fistula (CAAAF) are asymptomatic, and two-thirds of patients may experience symptoms such as angina, dyspnoea on exertion, or palpitation. Aneurysm repair, closure of fistula, and coronary artery bypass graft are the definitive treatment options.

Illustrative Case

Right Coronary Artery Aneurysm with Associated Fistula

No abnormality was detected in thallium scan and echocardiogram of a 73-year-old man who presented with chest pain. Further workup with CT coronary angiogram showed a huge fusiform aneurysm arising from the proximal RCA with direct drainage into the coronary sinus and the inferior aspect of the heart (Figures 14 and 15). Features were compatible with right CAAAF. The diagnosis was confirmed by subsequent cardiac catheterization, which demonstrated a 3-cm proximal RCA aneurysm that drained into the coronary sinus (Figure 16).

CONCLUSION

The aortic root is a complex structure which functions as a whole as the aortic valve. Pathological conditions of the aortic root are rare yet important. MDCT is excellent for evaluation of its anatomy and various pathologies.

REFERENCES

1. Manghat NE, Rachapalli V, Van Lingen R, Veitch AM, Roobottom CA, Morgan-Hughes GJ. Imaging the heart valves using ECG-gated 64-detector row cardiac CT. Br J Radiol. 2008;81:275-90. cross ref
2. Ho SY. Structure and anatomy of the aortic root. Eur J Echocardiogr. 2009;10:i3-10. cross ref
3. Berdajs D, Lajos P, Turina M. The anatomy of the aortic root. Cardiovasc Surg. 2002;10:320-7. cross ref
4. Schultz CJ, Moelker A, Piazza N, Tzikas A, Otten A, Nuis RJ, et al. Three dimensional evaluation of the aortic annulus using multislice computer tomography: are manufacturer's guidelines for sizing for percutaneous aortic valve replacement helpful? Eur Heart J. 2010;31:849-56. cross ref
5. Bricker AO, Avutu B, Mohammed TL, Williamson EE, Syed IS, Julsrud PR, et al. Valsalva sinus aneurysms: findings at CT and MR imaging. Radiographics. 2010;30:99-110. cross ref
6. Bennett CJ, Maleszewski JJ, Araoz PA. CT and MR imaging of the aortic valve: radiologic-pathologic correlation. Radiographics. 2012;32:1399-420. cross ref
7. Gahide G, Bommart S, Demaria R, Sportouch C, Dambia H, Albat B, et al. Preoperative evaluation in aortic endocarditis: findings on cardiac CT. AJR Am J Roentgenol. 2010;194:574-8. cross ref
8. Chen JJ, Manning MA, Frazier AA, Jeudy J, White CS. CT angiography of the cardiac valves: normal, diseased, and postoperative appearances. Radiographics. 2009;29:1393-412. cross ref
9. Fedak PW, Verma S, David TE, Leask RL, Weisel RD, Butany J. Clinical and pathophysiological implications of a bicuspid aortic valve. Circulation. 2002;106:900-4. cross ref
10. Ko SM, Song MG, Hwang HK. Bicuspid aortic valve: spectrum of imaging findings at cardiac MDCT and cardiovascular MRI. AJR Am J Roentgenol. 2012;198:89-97. cross ref
11. Kim SY, Seo JB, Do KH, Heo JN, Lee JS, Song JW, et al. Coronary artery anomalies: classification and ECG-gated multi-detector row CT findings with angiographic correlation. Radiographics. 2006;26:317-33. cross ref
12. Díaz-Zamudio M, Bacilio-Pérez U, Herrera-Zarza MC, Meave-González A, Alexanderson-Rosas E, Zambrana-Balta GF, et al. Coronary artery aneurysms and ectasia: role of coronary CT angiography. Radiographics. 2009;29:1939-54. cross ref
13. Syed M, Lesch M. Coronary artery aneurysm: a review. Prog Cardiovasc Dis. 1997;40:77-84. cross ref
14. Aqel RA, Zoghbi GJ, Iskandrian A. Spontaneous coronary artery dissection, aneurysms, and pseudoaneurysms: a review. Echocardiography. 2004;21:175-82. cross ref
15. Schumacher G, Roithmaier A, Lorenz HP, Meisner H, Sauer U, Müller KD, et al. Congenital coronary artery fistula in infancy and childhood: diagnostic and therapeutic aspects. Thorac Cardiovasc Surg. 1997;45:287-94. cross ref