
CASE REPORT

Endoscopic Nasopharyngectomy for Recurrent Nasopharyngeal Carcinoma

HM Chong¹, PY Lo¹, RKC Ngan²

Departments of ¹ENT Surgery and ²Clinical Oncology, Queen Elizabeth Hospital, Jordan, Hong Kong

ABSTRACT

Patients with early local recurrence of nasopharyngeal carcinoma with close proximity to the nearby carotid artery can be offered long-term control by endoscopic nasopharyngectomy which allows complete microscopic clearance of the recurrent tumour without damaging the carotid artery. This case report illustrates how this can be achieved without mutilating surgical procedures or further irradiation so that the patient can be spared of the associated morbidities.

Key Words: Endoscopy; Nasopharyngeal neoplasms; Neoplasm recurrence, local; Pharyngectomy

中文摘要

內視鏡鼻咽切除術治療復發性鼻咽癌

莊厚明、盧佩儀、顏繼昌

早期局部復發的鼻咽癌患者，如復發位置鄰近頸動脈，可以通過內視鏡鼻咽切除術完整切除復發腫瘤而避免損傷頸動脈，並獲得長期的控制。本文報告一宗類似病例，患者可以避免破壞性手術及再程放療，並避免了相關的併發症。

INTRODUCTION

Local recurrence of nasopharyngeal carcinoma has become less common since the use of intensity-modulated radiotherapy and chemotherapy. Early localised local recurrence in the nasopharynx can be cured by either re-irradiation or nasopharyngectomy. Nasopharyngectomy alone can serve to avoid exposing the patient to a second course of high-dose radiotherapy and its consequential adverse complications such as osteo-radionecrosis of the brain and skull bone, as well

as fatal haemorrhage of the carotid artery aneurysm.¹ Recent advancements in surgical techniques such as high-precision navigation system and availability of refined instruments allow nasopharyngectomy to be performed through an endoscopic approach which can reduce the surgical morbidities.²⁻⁴ This report illustrates how this approach can control locally recurrent nasopharyngeal carcinoma in the long term with favourable surgical outcome and excellent quality of life.

Correspondence: Dr Hou-ming Chong, Department of ENT Surgery, Queen Elizabeth Hospital, 30 Gascoigne Road, Jordan, Hong Kong.

Tel: (852) 2958 6025; Fax: (852) 2958 5708; Email: hk038@hotmail.com

Submitted: 4 Jun 2014; Accepted: 18 Jul 2014.

CASE REPORT

A 64-year-old man, who had undifferentiated nasopharyngeal carcinoma stage T2N0M0 treated with radical radiotherapy in 1999, was found to have local relapse in September 2011. On fiberoptic nasopharyngoscopy, there was a granular tumour over the left side of the nasopharynx; biopsy of which showed undifferentiated carcinoma. Blood examination showed immunoglobulin A titre against viral capsid antigen of Epstein-Barr virus to be 1 in 160.

Investigations including magnetic resonance imaging (MRI) of nasopharynx, computed tomography (CT) scan of the paranasal sinuses, neck and liver ultrasonography, isotope bone scan, and chest X-ray were arranged. No distant metastasis was detected. The MRI showed a mass lesion in the left lateral and posterior walls of nasopharynx, which extended to within 1 to 2 mm from the left carotid artery (Figure 1). Both parapharyngeal spaces and nasal cavities were uninvolved, and there was no evidence of base of skull erosion. 3-Dimensional MR angiogram of major blood vessels at the skull base was reconstructed. As prominent (1-1.6 cm) bilateral level I lymph nodes were also noted, fine-needle aspiration of the right submental lymph node was performed and revealed no malignant cells. After full evaluation, the recurrence was clinically staged as rT1N0M0.

In view of the very early stage of local recurrence, various curative treatment options were offered to him, including endoscopic nasopharyngectomy and re-irradiation. After discussion, the patient preferred endoscopic nasopharyngectomy.

The operation was performed in October 2011 with the use of the Kick navigation system (BrainLab, Germany). The images of the preoperative MR angiogram and paranasal sinus CT scan were co-registered for mapping the recurrent tumour and the nearby carotid artery to guide the route of resection (Figure 2). With traction applied by the assistant, the tumour was initially resected with needle diathermy and scissors, and finally removed en bloc with coblator when resection was advanced close to the carotid artery. Intra-operative frozen sections of the resection margins were taken, including additional biopsy from the deep margin localised by the Kick navigation system, aiming at achieving negative resection margins to optimise cancer control.⁵ All resection margins were clear except the second deep resection margin which showed

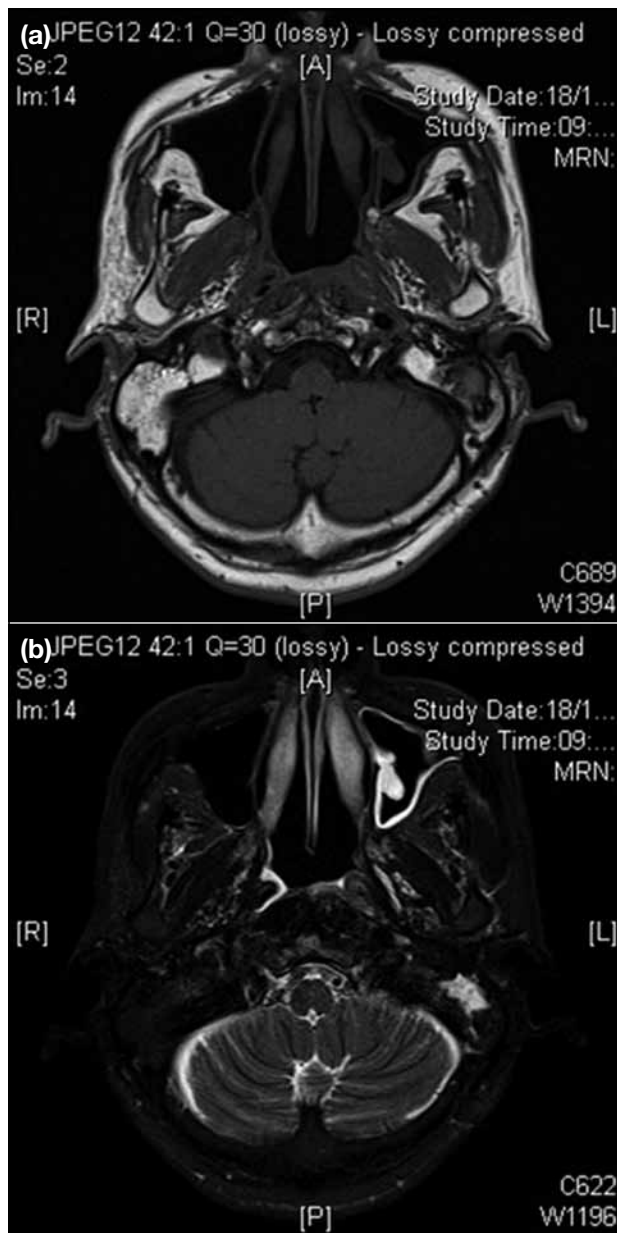


Figure 1. Preoperative magnetic resonance imaging: (a) T1-weighted and (b) T2-weighted images of local recurrence in left nasopharynx in 2011.

involvement of carcinoma cells. Despite this, the resection was stopped when the Kick navigation system indicated the carotid artery was already located about 1 mm away. The wound defect was then covered by a nasal septal flap supplied by the sphenopalatine artery.

The operation was uneventful without any complication. The volume of acute blood loss was around 500 ml. Postoperatively, he was sent to the intensive care unit for a short period of close monitoring, and discharged on postoperative day 14. The final pathology of the nasopharyngectomy specimen showed tumour cells

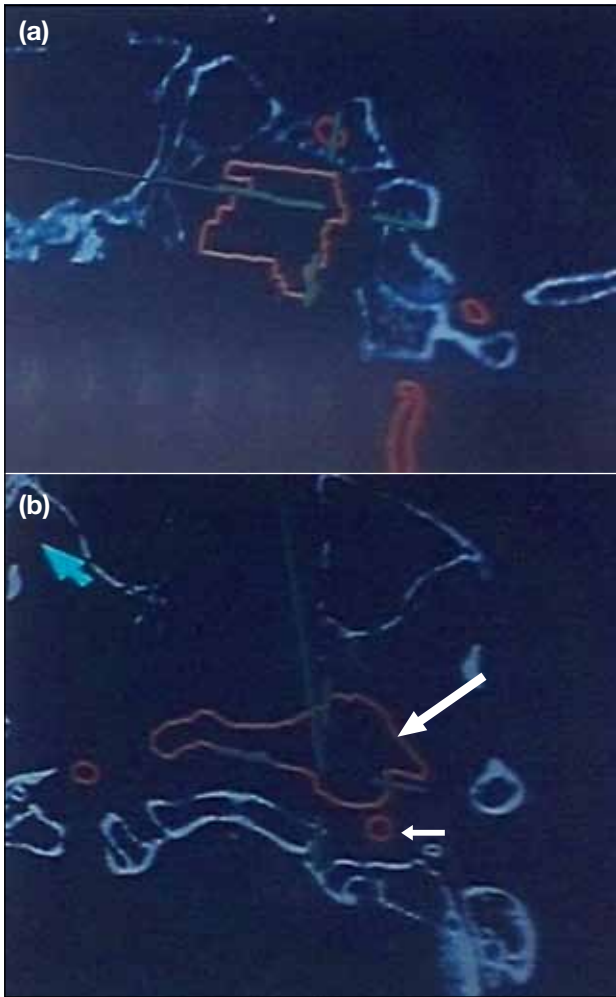


Figure 2. (a) Navigation indicator shows lateral margin of tumour in a coronal image. (b) An axial computed tomography image shows navigation indicators (green arrow) and relationship of the irregular tumour outlined in red (long arrow) over the left side of nasopharynx with the round left carotid artery also in red (short arrow).

focally involving the superior and deep margins while the left and right margins were clear of the tumour.

After full recovery from the operation, he had regular follow-up visits in the ear, nose and throat outpatient clinic with regular nasoendoscopic examination and annual MRI. The nasopharyngeal flap healed well without further development of new lesions, and crusting was regularly removed.

The latest MRI in 2013 showed no evidence of tumour recurrence (Figure 3) and the right level I lymph node remained unchanged at 3 years after the surgery.

DISCUSSION

Despite the risk of irradiation-related complications,

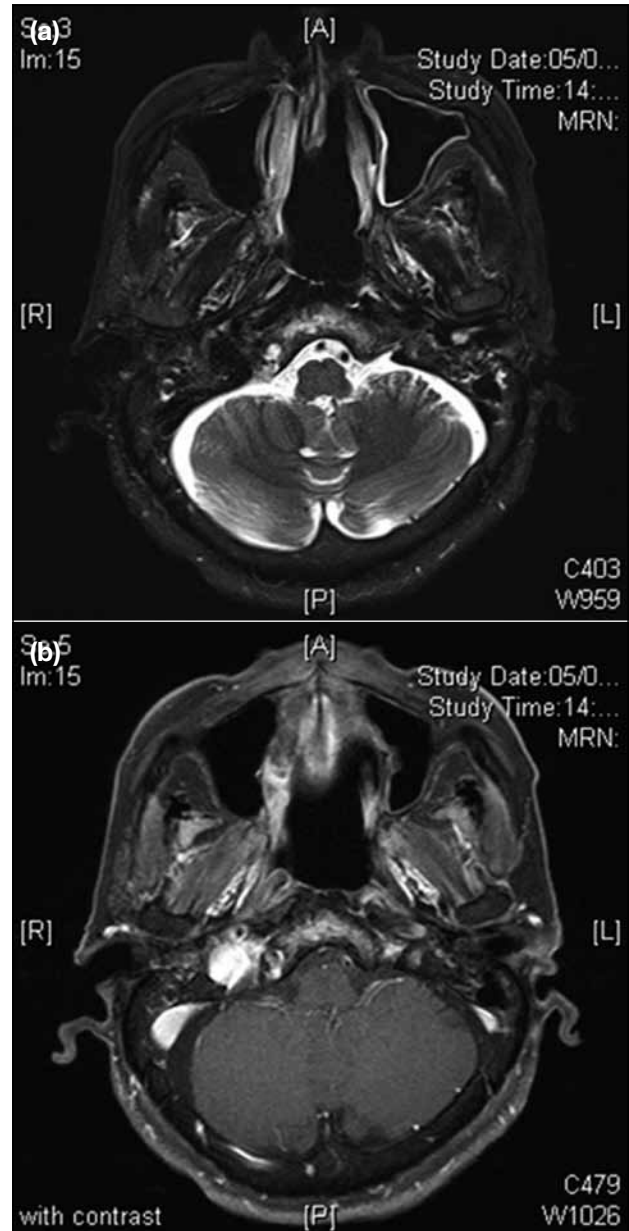


Figure 3. Postoperative magnetic resonance imaging: (a) T2-weighted and (b) T1-weighted images of nasopharynx in 2013 show no recurrence in the resected left nasopharynx.

second-course radiotherapy has been a common treatment option for locally recurrent nasopharyngeal carcinoma, especially for those with more advanced stages (rT3 or rT4) not amenable to nasopharyngectomy. Re-irradiation can lead to possible serious complications such as carotid artery aneurysm, temporal lobe necrosis, and osteo-radionecrosis of skull base.^{6,7} Nasopharyngectomy has been traditionally performed via either maxillary-swing, mandibular-swing, or midface degloving approaches,⁸ but these are associated with significant morbidity.

Endoscopic nasopharyngectomy has been reported

about 10 years ago from different centres. It has become more popular and feasible with the advancement of the navigation system for locating the positions of the tumour and the nearby carotid artery.⁹ Moreover, the use of nasal septal flap to cover the wound after nasopharyngectomy has significantly lessened the clinical problem of non-healing wounds commonly present as persistent headache. New instruments such as needle diathermy and coblator can facilitate dissection and ablation of tumour tissue more precisely. Therefore, the patient benefits from an accurate navigation system which can locate the plane of resection to even within 1 mm next to the carotid artery, and also the use of coblator allows maximal resection of the tumour and avoids excessive thermal transmission injury to the carotid artery.

Indeed, the patient presented here demonstrated the high accuracy of the system that allowed precise excision of the tumour. The computer navigation system, together with the coblation technique capitalising on infrared location and low-temperature desiccation of tissue, protects the nearby vital organs such as the dura and carotid artery from surgical damage. Although the frozen section of the extra second deep resection margin still showed tumour foci within the background scar tissue, they might represent the last few foci of tumour cells extending to near the carotid artery. A positive deep margin is oncologically significant as that indicates a high chance of recurrence as shown by previous studies reporting on nasopharyngectomy performed with an open approach.⁵ To the best of our knowledge, there are no large studies validating any equivalent significance of positive margins in outcome after nasopharyngectomy performed with an endoscopic approach, although a belief of lack of similar implication would be counterintuitive. The advancement in precision of the surgical techniques allowed the closest possible plane of resection in the sense that the ‘last bite’ could have cleared up the few residual tumour clusters without sacrificing the carotid artery, obviating the need of ‘adjuvant’ radiotherapy to safeguard a ‘positive resection margin’. Such an approach avoids a mutilating carotid artery intervention and also saves the patient from the possible serious complications of a second-course radiotherapy.

Compared with open nasopharyngectomy through the maxillary swing approach, the volume of acute blood loss amounting to about 500 ml is much reduced compared with about 1000 ml in open surgery.¹⁰ In addition, there is also a significant reduction in the

risk of postoperative trismus, dysphagia, choking and nasal regurgitation, as well as avoiding a facial scar. In open nasopharyngectomy, the risk of palatal fistula formation has been reported to be up to 8% and severe postoperative trismus of up to 25% of cases.¹¹ The quality of life for the patient is, hence, only minimally affected compared with that before the salvage operation.

CONCLUSION

Endoscopic nasopharyngectomy performed with a high-precision navigation system and surgical instruments that can remove the recurrent tumour accurately without associated thermal injury to the nearby carotid artery, is a competitive option for treating locally recurrent nasopharyngeal carcinoma.

DECLARATION

No conflicts of interest were declared by authors.

REFERENCES

1. Lam JW, Chan JY, Lui WM, Ho WK, Lee R, Tsang RK. Management of pseudoaneurysms of the internal carotid artery in postirradiated nasopharyngeal carcinoma patients. *Laryngoscope*. 2014;124:2292-6. [cross ref](#)
2. Chen MY, Guo X, Wen WP, Hua YJ, Guo L, Li NW, et al. Salvage surgical operation via endoscopic transnasal approach for local persistent or recurrent nasopharyngeal carcinoma [in Chinese]. *Ai Zheng*. 2007;26:673-8.
3. Chen MY, Wen WP, Guo X, Yang AK, Qian CN, Hua YJ, et al. Endoscopic nasopharyngectomy for locally recurrent nasopharyngeal carcinoma. *Laryngoscope*. 2009;119:516-22. [cross ref](#)
4. Ho AS, Kaplan MJ, Fee WE Jr, Yao M, Sunwoo JB, Hwang PH. Targeted endoscopic salvage nasopharyngectomy for recurrent nasopharyngeal carcinoma. *Int Forum Allergy Rhinol*. 2012;2:166-73. [cross ref](#)
5. Vlantis AC, Tsang RK, Yu BK, Kam MK, Tong MC, Lo PS, et al. Nasopharyngectomy and surgical margin status: a survival analysis. *Arch Otolaryngol Head Neck Surg*. 2007;133:1296-301. [cross ref](#)
6. Leung TW, Tung SY, Sze WK, Wong FC, Yuen KK, Lui CM, et al. Treatment results of 1070 patients with nasopharyngeal carcinoma: an analysis of survival and failure patterns. *Head Neck*. 2005;27:555-65. [cross ref](#)
7. Chua DT, Sham JS, Kwong DL, Wei WI, Au GK, Choy D. Locally recurrent nasopharyngeal carcinoma: treatment results for patients with computed tomography assessment. *Int J Radiat Oncol Biol Phys*. 1998;41:379-86. [cross ref](#)
8. Hao SP, Tsang NM. Surgical management of recurrent nasopharyngeal carcinoma. *Chang Gung Med J*. 2010;33:361-9.
9. Ong YK, Solares CA, Lee S, Snyderman CH, Fernandez-Miranda J, Gardner PA. Endoscopic nasopharyngectomy and its role in managing locally recurrent nasopharyngeal carcinoma. *Otolaryngol Clin North Am*. 2011;44:1141-54. [cross ref](#)
10. Chen MY, Wen WP, Guo X, Yang AK, Qian CN, Hua YJ, et al. Endoscopic nasopharyngectomy for locally recurrent nasopharyngeal carcinoma [in Chinese]. Available from: <http://www.mdweekly.com.cn/article.asp?id=11221>.
11. Chan YW, Chow VL, Wei WI. Quality of life of patients after salvage nasopharyngectomy for recurrent nasopharyngeal carcinoma. *Cancer*. 2012;118:3710-8. [cross ref](#)