
ORIGINAL ARTICLE

Incidental Breast Masses on Ultrasound: What are Their Characteristics and Clinical Outcome?

VYK To, CY Lee, CX Chan, SL Fung

Department of Radiology, Tuen Mun Hospital, Tuen Mun, Hong Kong

ABSTRACT

Objective: To evaluate the characteristics and clinical outcome of non-palpable breast lesions screened by ultrasound.

Methods: From January 2011 to June 2011, all new cases referred to the breast clinic at Tuen Mun Hospital, Hong Kong, were identified. All patients underwent ultrasound with or without mammography. Patients with a palpable or mammographically detected breast mass were included in the control group. Patients with non-palpable breast lesions detected incidentally on ultrasound only were included in the investigation group. Any patients who underwent targeted ultrasound were excluded. Baseline patient demographics, including age and family history of breast cancer, were documented. Lesion characteristics on ultrasound, including maximum dimension and Breast Imaging Reporting and Data System (BI-RADS) classification, were analysed. The nature of the lesions was confirmed histologically or by follow-up imaging for at least 2 years to indicate benignity.

Results: A total of 196 patients with 422 lesions were identified. Among the 422 lesions, 130 were palpable or mammographically detected lesions (control group) and 292 were non-palpable ultrasound-detected lesions (investigation group). The baseline characteristics in both groups were comparable. The mean age was 44 years in the control group and 42 years in the investigation group. There were 10 and 8 patients with a family history of breast cancer in the control group and investigation group, respectively. Compared with the control group, the maximum dimension of the lesion was significantly smaller in the investigation group ($p < 0.05$). The BI-RADS classification was significantly lower in the investigation group ($p < 0.05$). A total of 156 lesions had tissue diagnosis and 270 lesions were followed up for at least 2 years with no change or a decrease in size, indicating benignity. In the control group, 18 (13.8%) lesions were malignant while in the investigation group, no lesions were malignant ($p < 0.05$).

Conclusion: Ultrasound can detect small lesions that are mammographically occult and non-palpable. However, these lesions are likely more benign-looking (BI-RADS 2/3) and pathologically benign.

Key Words: Breast neoplasms; Mammography; Mass screening; Palpation; Ultrasonography, mammary

中文摘要

超聲偶然發現的乳腺腫塊的特徵和臨床結局

杜婉筠、李芷茵、陳積聖、馮小玲

目的：評估臨床觸診未捫及但於超聲檢查發現的乳腺病變的特徵和臨床結局。

Correspondence: Dr Victoria YK To, Department of Radiology, Tuen Mun Hospital, 23 Tsing Chung Koon Road, Tuen Mun, Hong Kong.

Tel: (852) 2468 5175; Email: vykto911@gmail.com

Submitted: 15 Dec 2014; Accepted: 4 Mar 2015.

方法：收集於2011年1月至6月期間被轉介至香港屯門醫院乳腺專科的新症病例。所有病人均已進行超聲檢查，部分也接受了乳腺X線攝影。觸診或乳腺X線攝影發現腫塊的病例均被列入對照組。觸診未及但於超聲偶然發現乳腺腫塊的病例則被納入研究組。研究排除所有接受針對性超聲檢查的病例。記錄研究初始階段病人的人口學統計資料，包括其年齡和乳腺癌家族史，並分析超聲檢查中的乳腺腫塊特徵，包括腫塊最大直徑、乳腺影像報告和數據系統（BI-RADS）分級。病變性質由組織學檢查確診；或依據兩年以上的隨訪影像檢查來提示病變為良性。

結果：總計196名病人，含422例乳腺腫塊被納入研究。422例乳腺腫塊中，130例為可觸及或乳腺X線攝影發現（對照組），另292例為未觸及但於超聲檢查中發現（研究組）。研究組和對照組的基線特徵相若。對照組與研究組平均年齡分別為44歲和42歲，另分別有10人和8人有乳腺癌家族史。研究組腫塊最大直徑顯著小於對照組（ $p < 0.05$ ），其BI-RADS分級亦較低（ $p < 0.05$ ）。共有156個腫塊有組織學診斷，270個腫塊隨訪兩年以上無變化或體積變小，提示為良性。對照組中，18個腫塊（13.8%）為惡性；研究組中則沒有發現任何惡性病變（ $p < 0.05$ ）。

結論：超聲可探測到乳腺X線攝影中隱匿性和觸診未及的小腫塊；但多數腫塊為良性外觀形態（即BI-RADS分級2和分級3），其病理學診斷也為良性。

INTRODUCTION

Breast cancer is the commonest female cancer in Hong Kong since the early 1990s. It is the third leading cause of death among all women with cancer in Hong Kong. There has been a rising incidence of breast cancer over the past 20 years, not only in the western population but also in the Chinese population. The incidence has tripled from 1993 to 2011.^{1,2}

Currently, there is no population-based breast screening programme in Hong Kong, while there are established breast screening programmes in the United States, United Kingdom, Singapore, and Japan among others. There is increasing public awareness of breast cancer worldwide and more women are now performing self-breast examination. A growing number of women are attending the breast clinic for self-examined breast masses.

The American College of Radiology recommends that ultrasound can be considered an adjunct to screening mammography in women with dense breast tissue or in high-risk women for whom magnetic resonance imaging (MRI) cannot be done.³ However, there is no consensus on the usefulness of ultrasound screening in the Asian population. Several studies also observe that Asians or Chinese generally have denser breast tissue.^{4,5}

Ultrasound is a well-tolerated, inexpensive, and widely available modality compared with mammography and MRI. In many centres, ultrasound screening of both

breasts is done in addition to mammography. However, some centres only perform targeted ultrasound. At Tuen Mun Hospital in Hong Kong, symptomatic patients attend the new case breast clinic and are referred to the radiology department for imaging. Patients older than 40 years have mammogram and ultrasound scan performed, whereas patients younger than 40 years only have ultrasound scan. All new cases also have bilateral whole-breast ultrasound scans.

The purpose of this study was to evaluate the characteristics and clinical outcome of non-palpable breast lesions screened by ultrasound scan.

METHODS

From January 2011 to June 2011, all new cases referred to the breast clinic at Tuen Mun Hospital were identified. Using the hospital's electronic patient records, all clinical notes at the breast clinic were reviewed. Baseline patient demographics, including age and family history of breast cancer, were documented. The presenting symptoms, such as a palpable mass, lumpiness or nipple discharge, were recorded. If patients had mammogram done, whether or not any mass was identified was noted. Ultrasound was performed by radiologists with at least 5 years of experience in ultrasound imaging. The images were reviewed by two radiologists, one of whom had completed training in breast radiology and the other was a breast radiology trainee. Images were assessed on the hospital's picture archiving and communication

system. All lesions identified on ultrasound, whether palpable or not, were documented and lesion characteristics, including the maximum dimension up to two decimal places and Breast Imaging Reporting and Data System (BI-RADS) classification, were analysed.

Inclusion and Exclusion Criteria

The inclusion criteria were palpable masses or mammographically detected breast masses (control group) and asymptomatic non-palpable breast masses detected incidentally on ultrasound only (investigation group). Only female patients were recruited. Patients who had previous private imaging were excluded since their ultrasound studies could not be accessed and evaluated. Patients with only targeted ultrasound done or inadequate follow-up time were also excluded.

The nature of the lesions was confirmed with tissue diagnosis, either cytology from fine-needle aspiration or histology from core biopsy. Benignity was defined by the tissue diagnosis result or presumed after at least 2 years of follow-up with no change or a decrease in the size of the lesion.

Statistical Analysis

This was a retrospective cross-sectional study. The chi-square test was used to calculate any statistical differences between the outcomes in the two groups. The

independent *t*-test was used to calculate any statistical differences in the size of the lesions between the two groups. The BI-RADS classification was arranged into BI-RADS 2/3 and BI-RADS 4/5 for categorical analysis. The chi-square test was used to calculate the statistical difference in BI-RADS classification between the control group and investigation group.

RESULTS

A total of 689 patients attended the new case breast clinic at Tuen Mun Hospital, Hong Kong from January 2011 to June 2011 and 493 patients were excluded from the study. There were 196 patients with 426 lesions identified. Among the 426 lesions were 130 palpable or mammographically detected lesions (control group) and 296 non-palpable ultrasound-detected lesions; of the latter group, four non-palpable lesions in the contralateral breast of patients with palpable breast cancers were excluded, making 292 as the total number of lesions in the investigation group (Figure).

The baseline patient characteristics in both groups were comparable. The mean age was 44 years in the control group and 42 years in the investigation group. There were 10 (7.7%) and 8 (2.7%) patients with a family history of breast cancer in the control group and investigation group, respectively.

Of the patients studied, 133 (67.9%) patients presented

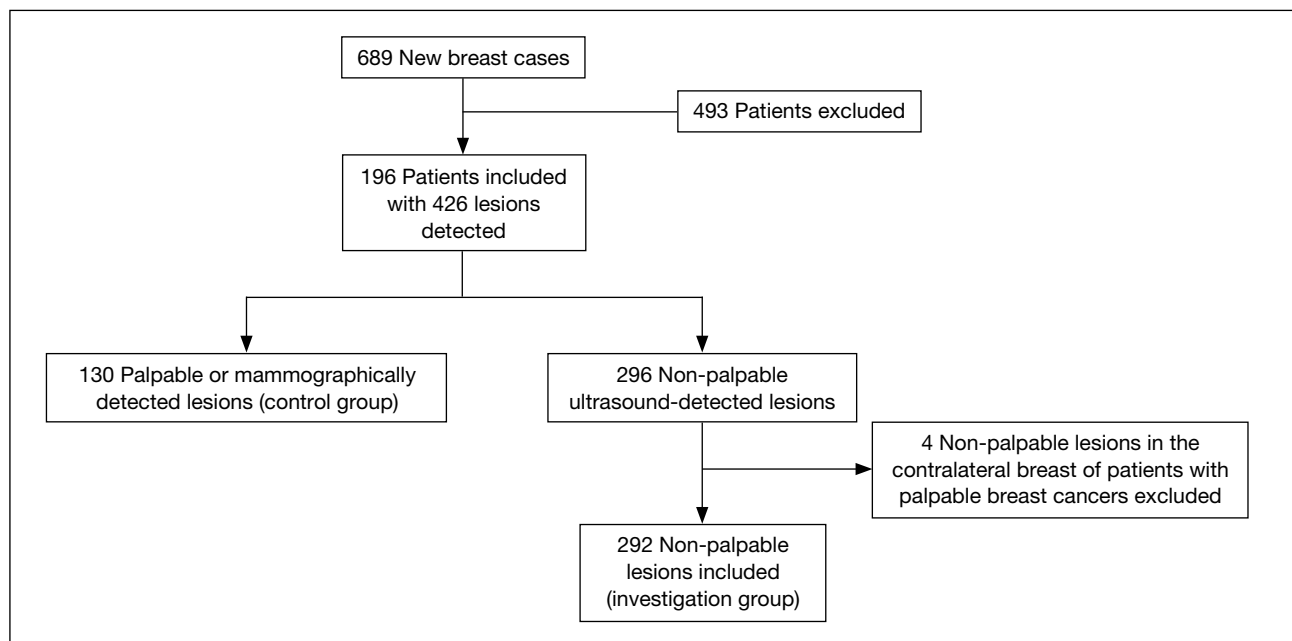


Figure. Flowchart showing the number of lesions in the control group and investigation group.

Table. Size and pathology results of the lesions.

	Control group (n = 130)	Investigation group (n = 292)	p Value
Mean size (range) [cm]	2.32 (0.31-4.60)	0.91 (0.20-3.40)	<0.05
Tissue diagnosis: malignant	18 (13.8%)	0 (0%)	<0.05
Invasive ductal carcinoma	12	-	
Mucinous carcinoma	5	-	
Intracystic papillary carcinoma	1	-	

with masses, 33 (16.8%) with lumpiness, 54 (27.6%) with mastalgia, 41 (20.9%) with nipple discharge, and other reasons included screening of those with a family history of breast cancer. Some patients had two or more symptoms at the same time.

The maximum dimension of the lesion was significantly smaller in the investigation group ($p < 0.05$). The mean size was 2.32 cm in the control group and 0.91 cm in the investigation group (Table). The BI-RADS classification was significantly lower in the investigation group ($p < 0.05$). Most of the lesions in both groups were BI-RADS 3.

There were 156 lesions with tissue diagnosis and 270 lesions were followed up for at least 2 years with no change or a decrease in size, indicating benignity. In the control group, 18 (13.8%) lesions were malignant while, in the investigation group, no lesions were malignant ($p < 0.05$) [Table]. Incidental lesions detected in the contralateral breast of the 18 patients with palpable breast cancers were excluded from the investigation group to eliminate possible high-risk patients but there was still a statistically significant difference between the two groups ($p < 0.05$).

Two patients had non-palpable ultrasound-detected lesions with a tissue diagnosis of atypical cells showing no change in size after 2 years. One patient had atypical ductal hyperplasia and subsequently underwent surgical excision.

DISCUSSION

According to the American College of Radiology, ultrasound can be considered an adjunct to screening mammography in women with dense breast tissue or in high-risk women for whom MRI cannot be done.³ In the United Kingdom, mammography remains the gold standard of the National Health Service Breast Screening Programme and the use of ultrasound is not addressed.⁶ The Singapore national breast cancer screening programme, BreastScreen Singapore, only uses ultrasound as an additional test, depending on the

mammography result.⁷ There is still much debate on the usefulness of ultrasound screening, whether it can be used alone or must only be considered an adjunct to mammography in the Asian population.^{2,8} In Hong Kong, many public and private institutions still advocate ultrasound screening of both breasts rather than targeted ultrasound.

Ultrasound is a well-tolerated, cost-effective, and widely available modality, which may be an attractive alternative to mammography if women are given the option. Some Asian women have smaller breast volume and compression of the breast may be a highly uncomfortable experience, so ultrasound screening, being less traumatic, may be more favourable in this population.⁹ In addition, many Chinese women may have denser breast tissue^{4,5} so interpretation of the mammograms can be quite challenging. Many studies concentrate on the usefulness of mammography and MRI, but few studies address the usefulness of ultrasound in Asian or Chinese populations. Therefore, this study explored the effectiveness of ultrasound screening in Asian women.

Our study concludes that ultrasound can easily detect non-palpable lesions as small as 0.20 cm. This result suggests that ultrasound is a good investigation modality for identifying occult masses, especially in young patients or patients who have denser background breast tissue as proposed in many previous studies.¹⁰⁻¹⁷ With increasing breast density, the sensitivity of mammography decreases. Therefore, in Asian women with generally smaller denser breasts, ultrasound is likely to better detect small occult lesions than mammography. However, this needs to be balanced with possible increases in cost, biopsy rates, and patient anxiety.^{2,8,17,18}

Our results also suggest that the BI-RADS classification and tissue diagnosis of incidental lesions are more likely to be benign ($p < 0.05$). Most of the lesions in both groups were BI-RADS 3. This outcome is in line with current guidelines and studies that screening ultrasound

is limited by a low positive predictive value with a higher number of false positives when compared with screening mammography.¹⁵⁻¹⁹

In our study, screening ultrasound also detected two atypical lesions and one atypical ductal hyperplasia, which affected the management. Although no breast cancers were detected, ultrasound may still be useful in certain high-risk groups to detect premalignant lesions. There is limited literature on the assessment of ultrasound to identify premalignant lesions; further local studies in this area can be considered.

There are a few limitations to this study. First, this is a retrospective single-centre study in patients who were initially symptomatic, therefore in a diagnostic group. However, we postulate that if the lesions were non-palpable and incidentally detected on ultrasound, then the lesions are likely to be similar to those in a screening population. We also excluded many patients who had previously undergone imaging in private practice, only had targeted ultrasound, or had no tissue diagnosis with inadequate follow-up, which compromises the sample size. Second, ultrasound is operator-dependent, therefore the accuracy and quality of the images taken are unknown factors. In our study, ultrasound was performed by radiologists with at least 5 years of experience in ultrasound imaging. Lastly, cytology from fine-needle aspiration may not be adequate for accurate diagnosis and the interpretation relies heavily on the confidence and experience of the pathologist. However, many women opt for fine-needle aspiration as a less invasive procedure before considering core biopsy. If further studies are to be done, perhaps only core biopsy results should be included. For patients without tissue diagnosis, 2 years' follow-up should be adequate.

CONCLUSION

Ultrasound is a useful tool to detect small lesions, which are mammographically occult and non-palpable. However, these lesions are inclined to be more benign looking (BI-RADS 2/3) and pathologically benign. Ultrasound may also incidentally detect premalignant lesions such as atypical ductal hyperplasia; therefore further studies, for example in high-risk patients, are worth exploring.

REFERENCES

1. Hong Kong Cancer Registry, Hospital Authority; 2011.
2. Guidelines for cancer prevention, early detection and screening. Hong Kong: The Hong Kong Anti-Cancer Society; 2009.

3. Lee CH, Dershaw DD, Kopans D, Evans P, Monsees B, Monticciolo D, et al. Breast cancer screening with imaging: recommendations from the Society of Breast Imaging and the ACR on the use of mammography, breast MRI, breast ultrasound, and other technologies for the detection of clinically occult breast cancer. *J Am Coll Radiol.* 2010;7:18-27. [crossref](#)
4. Recommendations on breast cancer screening. Hong Kong: Centre for Health Protection, Cancer Expert Working Group on Cancer Prevention and Screening; 2012.
5. Kwong A, John E, Pal S, Strakowski L, Ikeda DM. Comparison of breast density in Asian women and Caucasian women. *Breast Cancer Res Treat.* 2006;100:S143.
6. del Carmen MG, Halpern EF, Kopans DB, Moy B, Moore RH, Goss PE, et al. Mammographic breast density and race. *AJR Am J Roentgenol.* 2007;188:1147-50. [crossref](#)
7. Liston J, Wilson R, Thomas KG, Hopkins C, Litherland J, Record C, et al. Clinical Guidelines for Breast Cancer Screening Assessment. 3rd ed. NHSBSP Publication No 49; June 2010.
8. BreastScreen Singapore, Health Promotion Board: <http://www.hpb.gov.sg/HOPPortal/health-article/3324>. Accessed Apr 2015.
9. Dullum JR, Lewis EC, Mayar JA. Rates and correlates of discomfort associated with mammography. *Radiology.* 2000;214:547-52. [crossref](#)
10. Kolb TM, Lichy J, Newhouse JH. Comparison of the performance of screening mammography, physical examination, and breast US and evaluation of factors that influence them: an analysis of 27,825 patient evaluations. *Radiology.* 2002;225:165-75. [crossref](#)
11. Kaplan SS. Clinical utility of bilateral whole-breast US in the evaluation of women with dense breast tissue. *Radiology.* 2001;221:641-9. [crossref](#)
12. Crystal P, Strano SD, Shcharynski S, Koretz MJ. Using sonography to screen women with mammographically dense breasts. *AJR Am J Roentgenol.* 2003;181:177-82. [crossref](#)
13. Hooley RJ, Greenberg KL, Stackhouse RM, Geisel JL, Butler RS, Philpotts LE. Screening US in patients with mammographically dense breasts: initial experience with Connecticut Public Act 09-41. *Radiology.* 2012;265:59-69. [crossref](#)
14. Loving VA, DeMartini WB, Eby PR, Gutierrez RL, Peacock S, Lehman CD. Targeted ultrasound in women younger than 30 years with focal breast signs or symptoms: outcomes analyses and management implications. *AJR Am J Roentgenol.* 2010;195:1472-7. [crossref](#)
15. Weigel S, Biesheuvel C, Berkemeyer S, Kugel H, Heindel W. Digital mammography screening: how many breast cancers are additionally detected by bilateral ultrasound examination during assessment? *Eur Radiol.* 2013;23:684-91. [crossref](#)
16. Teh W, Wilson AR. The role of ultrasound in breast cancer screening. A consensus statement by the European Group for Breast Cancer Screening. *Eur J Cancer.* 1998;34:449-50. [crossref](#)
17. Berg WA, Blume JD, Cormack JB, Mendelson EB, Lehrer D, Böhm-Vélez M, et al. Combined screening with ultrasound and mammography vs mammography alone in women at elevated risk of breast cancer. *JAMA.* 2008;299:2151-63. [crossref](#)
18. Nothacker M, Duda V, Hahn M, Warm M, Degenhardt F, Madjar H, et al. Early detection of breast cancer: benefits and risks of supplemental breast ultrasound in asymptomatic women with mammographically dense breast tissue. A systematic review. *BMC Cancer.* 2009;9:335. [crossref](#)
19. Corsetti V, Houssami N, Ferrari A, Ghirardi M, Bellarosa S, Angelini O, et al. Breast screening with ultrasound in women with mammography-negative dense breasts: evidence on incremental cancer detection and false positives, and associated cost. *Eur J Cancer.* 2008;22:539-44. [crossref](#)