

---

---

**ORIGINAL ARTICLE**

---

---

# **N-Butyl Cyanoacrylate Embolisation for Acute Arterial Haemorrhage and Pseudoaneurysms in Extracranial Locations**

**KK Cheng, SCH Lam, DHY Cho, S Lau**

*Department of Diagnostic and Interventional Radiology, Kwong Wah Hospital, Yaumatei, Hong Kong*

## **ABSTRACT**

**Objective:** To review the technical feasibility and effectiveness of N-butyl cyanoacrylate (NBCA; Histoacryl, B. Braun, Melsungen, Germany) embolisation to control acute arterial haemorrhage and embolisation of pseudoaneurysms in extracranial locations.

**Methods:** A retrospective study was performed on 17 patients who underwent NBCA embolisation for haemorrhage control over a 5-year period. All showed angiographic evidence of active contrast extravasation, pseudoaneurysm, or both. NBCA alone was used in nine patients. NBCA together with other embolic agents (coils and particulate agents) were used in eight patients. Causes of the acute haemorrhage or pseudoaneurysm included recent operation or procedure, over-warfarinisation, recurrent tongue base carcinoma, pulmonary tuberculosis, cavitary lung mass, duodenal ulcer, and trauma. The sites embolised included the kidney, abdominal or chest wall, hepatopancreaticobiliary system, gastrointestinal tract, pulmonary system, head and neck, spleen, and lower limb.

**Results:** Immediate angiographic success was achieved in all patients (100%). Of 17 patients, NBCA embolisation was beneficial in 13 (76.5%), with no clinical or radiological evidence of recurrent bleeding. In the remaining four (23.5%) patients, one was confirmed to have recurrent bleeding during subsequent re-operation. Recurrent bleeding was suspected clinically in two. One patient died within 24 hours of the procedure due to multi-organ failure. There were no major complications directly related to NBCA embolisation.

**Conclusion:** NBCA embolisation with or without another embolic agent is technically feasible, effective, and safe to control acute arterial haemorrhage and to embolise pseudoaneurysms due to various causes and at various anatomic sites.

**Key Words:** Aneurysm, false; Arteries; Cyanoacrylates; Embolization, therapeutic; Hemorrhage

## **中文摘要**

### **NBCA 栓塞術治療顱外急性動脈出血和假性動脈瘤**

鄭加勁、林卓恆、曹慶恩、柳洵

**目的：**回顧研究N-氰基丙烯酸正丁酯（NBCA）栓塞術控制顱外急性動脈出血和假性動脈瘤栓塞的技術可行性和有效性。

---

---

**Correspondence:** Dr KK Cheng, Department of Diagnostic and Interventional Radiology, Kwong Wah Hospital, Yaumatei, Hong Kong.

Tel: (852) 3517 7090; Fax: (852) 3517 5454; Email: ckk635@ha.org.hk

Submitted: 11 Dec 2014; Accepted: 2 Mar 2015.

An earlier version of this paper was presented at the 22nd Annual Scientific Meeting of Hong Kong College of Radiologists held in Hong Kong, 1-2 November 2014.

**方法：**回顧分析5年內接受NBCA栓塞術以控制出血的17例病人。全部病例發現有急性顯影劑外滲，或假性動脈瘤的血管造影術證據，或兩者並存。9例單用NBCA，另8例合併使用NBCA膠和其他栓塞劑（線圈和微粒）。急性出血或假性動脈瘤的病因包括近期手術、華法林過量、復發性舌根癌、肺結核、空洞性肺腫塊、十二指腸潰瘍和創傷。栓塞部位包括腎、腹壁或胸壁、肝膽胰系統、胃腸道、肺部、頭和頸、脾和下肢。

**結果：**術後即時血管造影術成功率為100%。17例病人中，13例（76.5%）沒有臨床或放射學證據顯示出血復發，證實NBCA栓塞術有效。餘下4例（23.5%）病人中，1例於隨後二次手術過程中證實出血復發；2例臨床懷疑出血復發；1例因多器官衰竭於術後24小時內死亡。並沒有與NBCA栓塞術直接相關的嚴重併發症。

**結論：**NBCA單用或聯合其他栓塞劑用於控制顱外急性動脈出血，及栓塞各種誘因和解剖位置的假性動脈瘤是技術上可行，且臨床有效和安全的。

## INTRODUCTION

Transcatheter arterial embolisation has been used for many years to effectively control active arterial haemorrhage and embolise pseudoaneurysms in

various conditions and at different anatomical locations. Most often, metallic coils or particulate agents are used to achieve haemostasis in these cases. N-butyl cyanoacrylate (NBCA; Histoacryl, B.

**Table.** Clinical data of 17 patients who underwent NBCA embolisation.

Patient No.	Age (years) / sex	Underlying condition	Presentation
1	73/F	Psoas haematoma	Abdominal pain after aortic valve replacement operation
2	38/M	Recurrent tongue base carcinoma	Bleeding from tumour
3	81/F	Right hydronephrosis	Haemocalyx and hypotension during percutaneous nephrostomy
4	74/M	Carcinoma of ampulla of Vater	Shock and tachycardia 1 month after Whipple procedure
5	18/F	Appendicitis	Abdominal wall mass during percutaneous drainage of abscess
6	81/F	Fracture neck of left femur	Left hip pain and swelling after DHS fixation
7	62/M	SMA aneurysm	Hypotension and abdominal distension
8	46/M	Splenic flexure carcinoma	Pseudoaneurysm detected in postoperative CT
9	39/F	IgA nephropathy	Abdominal pain after renal biopsy
10	68/M	Cholangiocarcinoma	Bleeding from round drain after operation
11	66/M	Chest wall haematoma	Chest wall haematoma with contrast extravasation in CT
12	57/M	Pulmonary tuberculosis	Haemoptysis
13	75/F	Oncocytoma	Left flank pain and hypotension day 8 after partial nephrectomy
14	45/M	Bleeding duodenal ulcer	Melaena
15	65/M	Cavitary lung mass	Haemoptysis
16	57/M	Cholangiocarcinoma	Melaena after operation
17	38/M	Right renal laceration	Trauma

Abbreviations: CT = computed tomography; DIC = disseminated intravascular coagulopathy; DHS = dynamic hip screw; Ig = immunoglobulin; NBCA = N-butyl cyanoacrylate; SMA = superior mesenteric artery.

\* Clinical suspicion of recurrent bleeding.

Braun, Melsungen, Germany), which is a liquid and permanent embolic agent, is an alternative for control of acute arterial haemorrhage and embolisation of pseudoaneurysms.

The purpose of this study was to review the technical feasibility and effectiveness of NBCA embolisation to control acute arterial haemorrhage in extracranial locations.

**METHODS**

**Patient Population**

Between March 2009 and March 2014, a total of 50 patients underwent NBCA embolisation at various anatomical locations and for various conditions in a single institution in Hong Kong. Of them, 17 patients with bleeding episodes or pseudoaneurysms in extracranial locations who had presented clinically or been identified on computed tomography (CT) underwent NBCA embolisation (17 procedures in total) for haemorrhage control and were retrospectively

reviewed (Table).

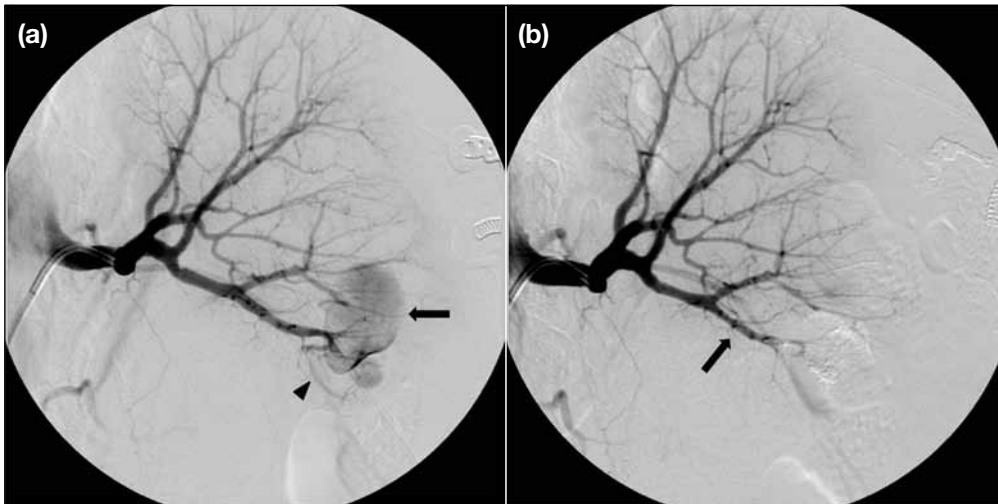
The patients comprised 11 males and six females with a mean age of 58 years (range, 18-81 years). Causes of the acute haemorrhage were recent operation or procedure (n = 9) [Figures 1 and 2], over-warfarinisation (n = 1), recurrent tongue base carcinoma (n = 1), pulmonary tuberculosis (n = 1), cavitary lung mass (n = 1), duodenal ulcer (n = 1), and trauma (n = 1); causes were unknown in two cases. Angiographic evidence of active contrast extravasation, pseudoaneurysm, or both were present in all patients (n = 17, 100%).

The sites embolised included the kidney (n=4) [Figure 3], abdominal or chest wall (n=3), hepatopancreaticobiliary system (n=3), gastrointestinal tract (n=2) [Figure 4], pulmonary system (n=2) [Figure 5], head and neck (n=1) [Figure 6], spleen (n=1), and lower limb (n=1) [Figure 7].

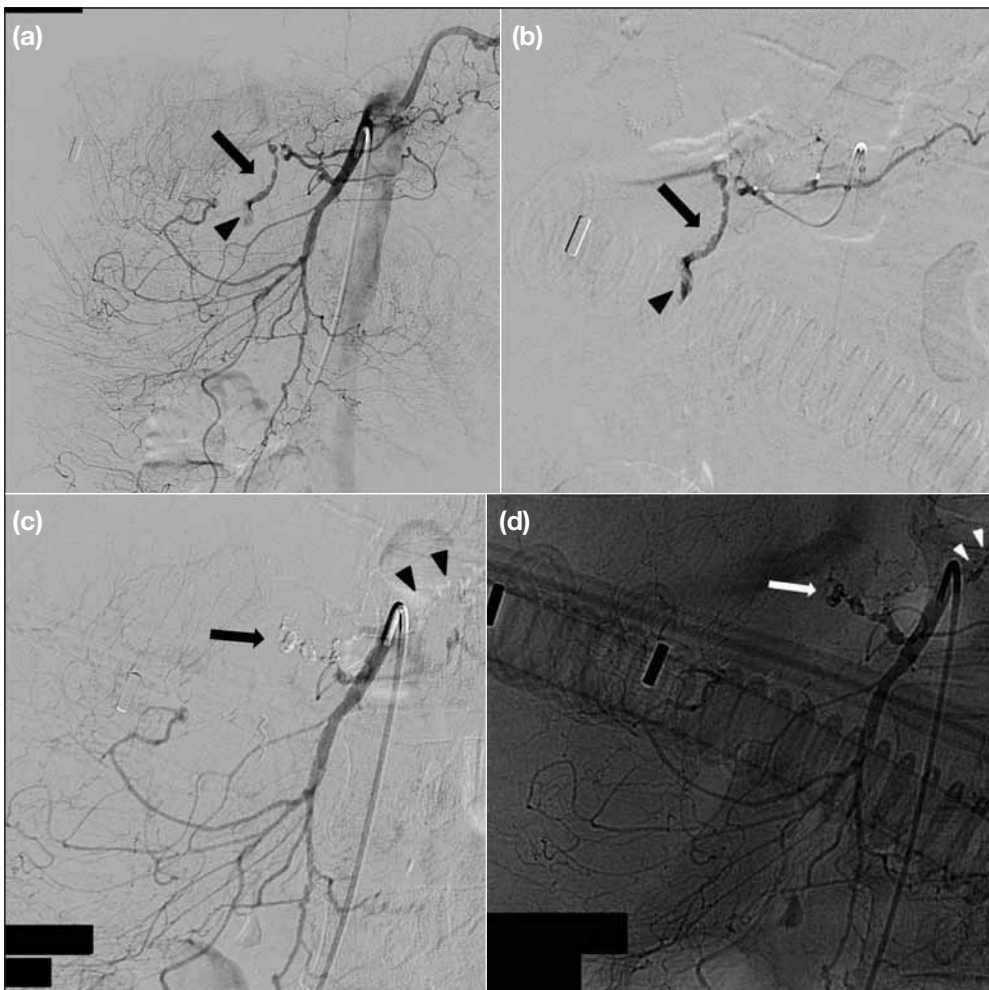
**Embolisation Techniques**

All procedures were performed via a common femoral

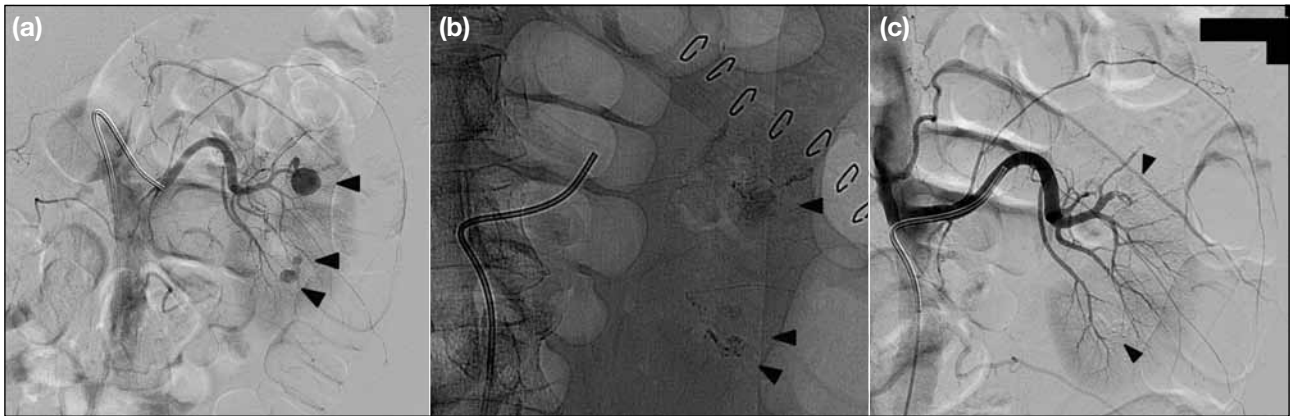
Angiographic findings	Artery embolised	Embolisation materials	Recurrent bleeding	Follow-up (cause of death)
Extravasation	Lumbar artery, iliolumbar arteries	Glue, gelatin sponge	No	Discharged
Extravasation, pseudoaneurysm	Mid right facial artery	Glue, microsphere	Yes*	Death after 4 months (multi-organ failure)
Extravasation	Right lower pole segmental renal artery	Glue, coil	No	Discharged
Extravasation, pseudoaneurysm	Gastroduodenal artery stump	Glue	Yes	Death after 3 days (recurrent bleeding with infective haematoma, DIC with hypotension)
Extravasation	Right inferior epigastric artery	Glue	No	Discharged
Pseudoaneurysm	Branch of left deep femoral artery	Glue, coil	No	Discharged
Extravasation	Jejunal branch of SMA	Glue, coil	No	Discharged
Pseudoaneurysm	Distal splenic artery	Glue, coil	No	Discharged
Extravasation, pseudoaneurysm	Distal left lower pole renal artery	Glue	No	Discharged
Extravasation, pseudoaneurysm	Proximal branch of SMA	Glue	No	Death within 24 hours (multi-organ failure)
Extravasation	Right lateral thoracic artery branches	Glue	No	Discharged
Extravasation	Inferior branch of left bronchial artery	Glue, microsphere	No	Discharged
Pseudoaneurysm, extravasation	Left mid and lower pole segmental renal arteries	Glue	No	Discharged
Pseudoaneurysm	Branch of SMA	Glue, coil	No	Discharged
Pseudoaneurysm	Right lateral-basal subsegmental pulmonary artery	Glue	No	Death after 7 months (sudden cardiac arrest)
Extravasation	Common hepatic artery	Glue	Yes*	Death after 1 month (sepsis)
Pseudoaneurysm	Segmental branch of right kidney	Glue	No	Discharged



**Figure 1.** Case 9: (a) Left renal artery angiogram shows a large pseudoaneurysm (arrow) with active contrast extravasation (arrowhead) at distal part of lower pole artery. (b) Superselective cannulation of the lower pole artery with microcatheter is performed with a total of 1-ml 1:3 NBCA mixture injected. Post-embolisation angiogram shows elimination of the pseudoaneurysm, cessation of contrast extravasation, and preservation of proximal parent artery (arrow).  
Abbreviation: NBCA = N-butyl cyanoacrylate.

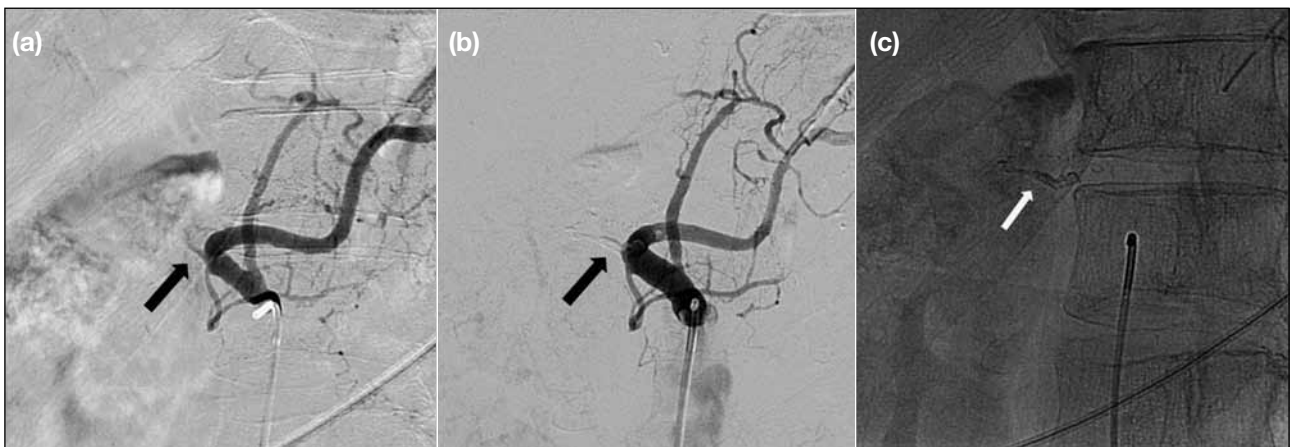


**Figure 2.** Case 10: (a) Superior mesenteric angiogram and (b) superselective arteriography with microcatheter show an abnormal vessel with pseudoaneurysm (arrows) and active contrast extravasation (arrowheads) at a proximal branch of superior mesenteric artery. (c) Post-embolisation digital subtraction angiogram and (d) angiogram show obliteration of the abnormal vessel and pseudoaneurysm (arrows), with cessation of contrast extravasation. Normal branch supplying part of the pancreas is sacrificed (arrowheads). Normal distal branches are preserved.



**Figure 3.** Case 13: (a) Angiogram of left renal artery shows pseudoaneurysms in interpolar and lower polar segmental arteries (arrowheads) with contrast extravasation. (b) A total of 0.2-ml 1:3 NBCA mixture is injected to each of them via microcatheters. Note that the mixture is radiopaque (arrowheads). (c) Post-procedural angiogram shows elimination of pseudoaneurysms (arrowheads) and cessation of contrast extravasation.

Abbreviation: NBCA = N-butyl cyanoacrylate.

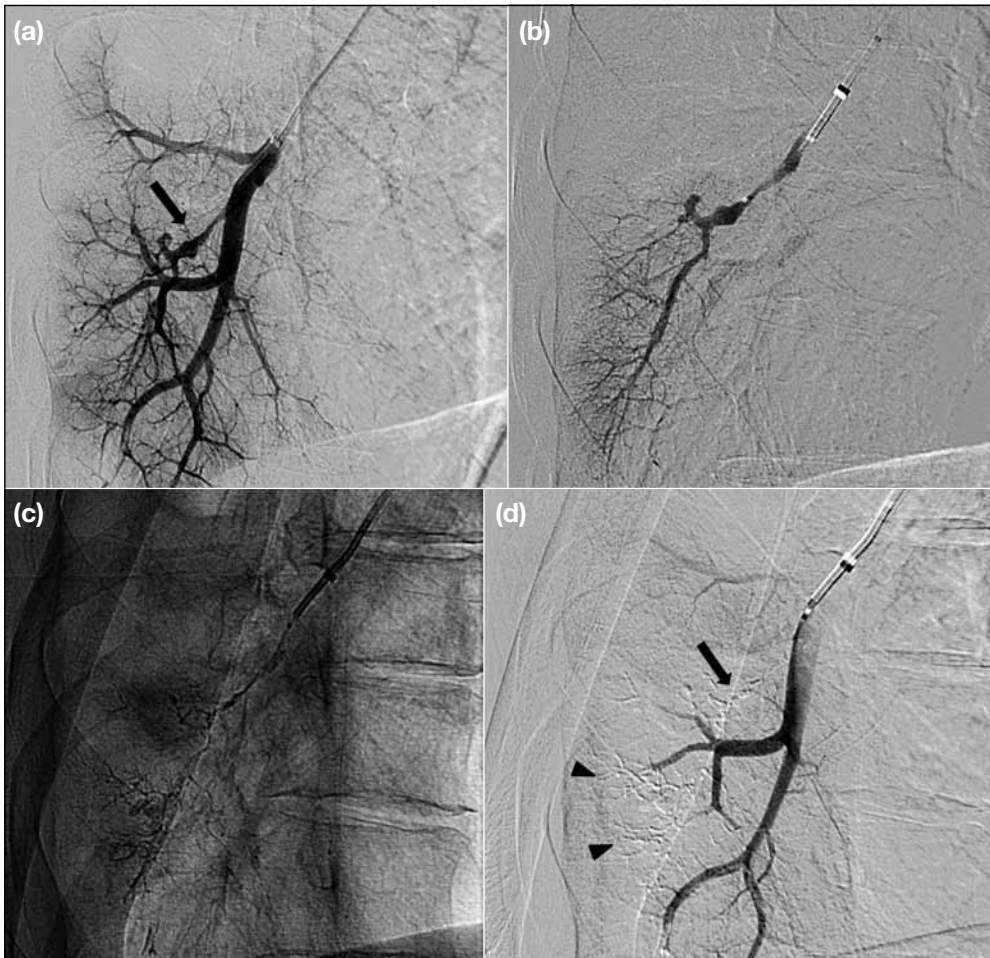

**Figure 4.** Case 16: (a) Coeliac arteriogram shows extravasation from the occluded common hepatic artery (arrow). (b) Post-embolisation arteriogram confirms successful trapping of the bleeding vessel (arrow). (c) The NBCA cast (arrow) depicts in post-embolisation fluoroscopic image.

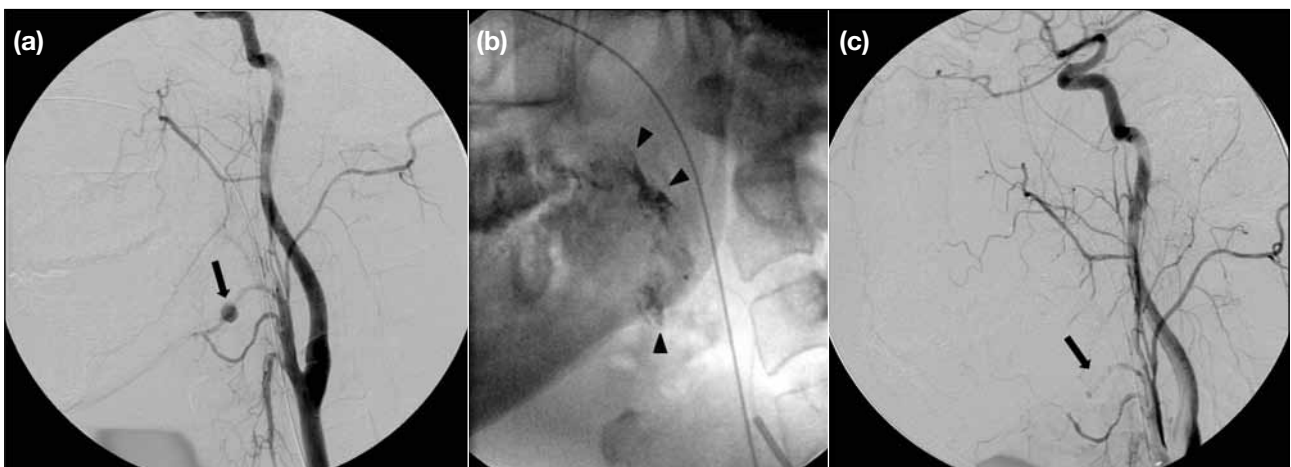
Abbreviation: NBCA = N-butyl cyanoacrylate.

artery approach using a 5-Fr or 6-Fr sheath, except in one patient in whom an 8-Fr long sheath was used for pulmonary artery pseudoaneurysm embolisation. Angiography using various kinds of 5-Fr or 4-Fr selective catheter (such as Cobra and Simmons) was performed with digital subtraction angiography evaluation performed in all patients to visualise the source of bleeding. The catheters were then used to access the site of haemorrhage or pseudoaneurysm. Diagnostic catheter manoeuvres were performed with a 0.035-inch guidewire.

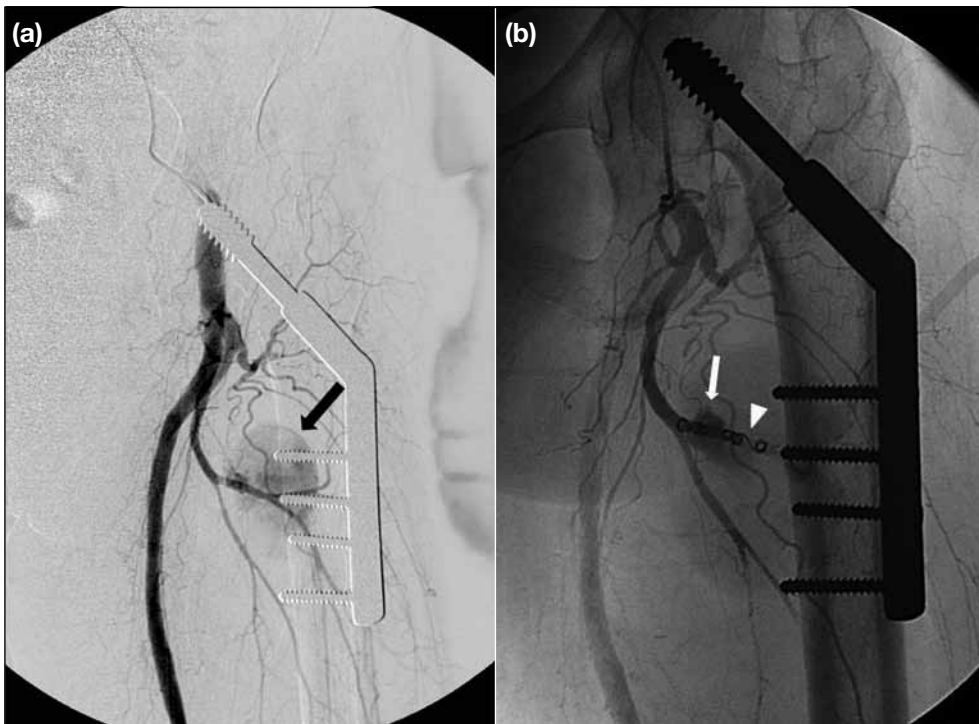
Superselective catheterisation was performed in all patients (100%) with microcatheters and microguidewires, which was advanced as close as possible to the site of haemorrhage or pseudoaneurysm. The microcatheter was placed through the less-selective 5-Fr or 4-Fr outer catheter that served as a guide to provide a stable position in the proximal vessel. This also allowed rapid exchange of microcatheters occluded by NBCA, and enabled check angiography at the proximal vessels to be performed following embolisation. The optional ‘flooding technique’ can



**Figure 5.** Case 15: (a) Selective arteriogram (right oblique view) of right lateral-basal segmental pulmonary artery with microcatheter shows pseudoaneurysm (arrow) at one of the subsegmental artery. (b) The pseudoaneurysm is further cannulated with the microcatheter. (c and d) After injection of 0.2-ml 1:5 NBCA mixture, post-embolisation fluoroscopic image depicts the NBCA cast and digital subtraction arteriogram confirms occlusion of the artery (arrowheads) and obliteration of the pseudoaneurysm (arrow). Abbreviation: NBCA = N-butyl cyanoacrylate.



**Figure 6.** Case 2: (a) Angiogram of right common carotid artery shows pseudoaneurysm with contrast extravasation at mid facial artery (arrow). (b) Superselective embolisation is performed with microspheres followed by NBCA mixture (arrowheads). (c) Post-embolisation angiogram confirms occluded right facial artery with obliterated pseudoaneurysm (arrow). Abbreviation: NBCA = N-butyl cyanoacrylate.



**Figure 7.** Case 6: (a) Common femoral artery angiogram shows a large pseudoaneurysm (arrow) arising from a branch of deep femoral artery. (b) Endovascular embolisation is performed with metallic coils (arrowhead) followed by NBCA mixture (arrow). Post-embolisation angiogram (not shown) shows occlusion of the artery and obliteration of the pseudoaneurysm. Abbreviation: NBCA = N-butyl cyanoacrylate.

also be used to achieve more distal embolisation, with positive-pressure continuous flush of 5% dextrose solution at the guiding catheter. This will flood the distal circulation with dextrose solution and slow the polymerisation of NBCA, hence allowing deeper penetration for more distal embolisation.<sup>1</sup>

NBCA was used as an embolic agent in all patients. NBCA alone was used in 9 (53%) of 17 patients but together with other embolic agents (including metallic coils, trisacryl gelatin microspheres, and gelatin sponge) in the remaining eight (47%). NBCA was used as the initial embolic agent when the operator anticipated difficulty in selective placement of the catheter close to or beyond the bleeding site in vessels that were small, tortuous, or anatomically difficult. Bleeding vessels that were supplied by many collateral vessels were also potential candidates for NBCA embolisation. In instances where complete embolisation with other embolic agents (such as coils or particulate agents) failed, additional NBCA could be administered. The decision to use NBCA was predominantly based on the judgement of the operating interventional radiologist(s) at the time of procedure.

NBCA was available in our angiography suite. Consent for transcatheter embolisation was obtained

in all patients, though no special consent for NBCA embolisation was obtained. The NBCA was mixed with iodinated oil (Lipiodol; Laboratoire Andre Guerbet, Aulnay-sous-Bois, France) in a ratio of 1:3 to 1:5, dependent on operator's preference. A test injection by hand was performed prior to injection of NBCA mixture to simulate the conditions of the planned embolisation. It was used to assess blood flow and vasculature in the region to prevent non-targeted embolisation, as well as to estimate the volume of mixture required. Clean towels were then placed around the hub of the microcatheter. The microcatheter and injection syringes were flushed with 5% dextrose solution before injection of NBCA to ensure clearance of residual saline or blood that could cause premature polymerisation of the glue within the lumen.

NBCA mixture was subsequently administered under continuous digital subtraction angiogram. The rate of injection was adjusted according to the flow of mixture during the screening. Techniques of administration of NBCA mixture depend on the vascular anatomy and operator preference. Two techniques, namely 'sandwich technique' and 'continuous column technique', were used.<sup>2</sup> The 'sandwich technique' (also known as 'push technique' or 'bolus technique') involves loading a volume of NBCA mixture smaller than the capacity

of the microcatheter, followed by injection of 5% dextrose solution to expel the NBCA mixture from the microcatheter and flush it forward into the circulation. The main advantages of this technique are preservation of the microcatheter lumen to allow more than a single deposition, and a reduced chance of catheter tip adhesion. The main disadvantage is the limited volume of NBCA mixture that can be delivered at each time. The 'continuous column technique' involves continuous injection of NBCA mixture as the agent exits the microcatheter to form a cast. A large volume of NBCA mixture can be administered to make a more complete glue cast at the target vessels. Nonetheless, this method may be more difficult to control as it often produces a proximal cast when there is reflux of NBCA mixture, causing potential risk of catheter tip adhesion and non-targeted embolisation during catheter withdrawal.

The delivery catheter was pulled back slowly after adequate deposition of NBCA mixture at the target site until it was no longer in contact with the column of mixture, and then removed.

### Study Endpoints

Retrospective review of patients' clinical records was performed to evaluate the angiographic success, clinical success, embolisation-related complications, and patient outcome.

Angiographic success was defined as absence of contrast extravasation and / or absence of contrast medium entering the pseudoaneurysms on angiography immediately following embolisation.

Complications — including evidence of unintended end-organ damage, abscess formation, and entrapment of delivery catheter — were reviewed in electronic Patient Record. Minor and major complications were defined according to the Classification System of Complications by Outcome in Society of Interventional Radiology Standards of Practice Guideline.<sup>3</sup>

NBCA embolisation was considered successful when there was no evidence or suspicion of recurrent bleeding, or no death within 24 hours of the procedure. Suspicion of recurrent bleeding was determined by clinical presentation or change to serial hematocrit levels. Evidence of recurrent bleeding was confirmed by positive radiological or intra-operative findings.

Follow-up was performed until death or discharge for

the episode of acute haemorrhage at the latest hospital outpatient visit.

### RESULTS

Immediate angiographic success was achieved in all patients (n = 17, 100%), of whom 13 (76.5%) remained in a clinically stable condition without signs or symptoms of recurrent haemorrhage. In the remaining four (23.5%) patients, one had extravasation of contrast and pseudoaneurysm at the gastroduodenal artery (GDA) stump following ampullary carcinoma resection. NBCA embolisation was unsuccessful and emergency laparotomy 3 days later confirmed recurrent bleeding intra-operatively at the GDA stump. Recurrent haemorrhage after NBCA embolisation was clinically suspected in two patients. One of them, who had haemorrhage of a recurrent tongue base carcinoma, showed active contrast extravasation and pseudoaneurysm at the mid right facial artery and had been embolised with microspheres and NBCA resulting in angiographic success. Afterwards, the patient was found to have blood in the endotracheal tube and recurrent bleeding was suspected. He decided to receive supportive care only and succumbed 4 months after admission. Another patient who presented with per rectal bleeding following Whipple procedure for cholangiocarcinoma showed extravasation of contrast from the common hepatic artery, and was subsequently embolised. Nonetheless, the patient presented with recurrent melaena 4 days later although urgent mesenteric angiograms were unremarkable. The fourth patient died within 24 hours of the procedure due to multi-organ failure.

There were no major complications directly related to NBCA embolisation. Non-targeted end-organ embolisation (small splenic infarcts) and suspected liver abscess were evident in one patient on follow-up CT, but the patient was asymptomatic and no additional treatment was given and there were no clinical sequelae. No entrapment of the delivery catheter within the embolised artery occurred during any procedure.

### DISCUSSION

Percutaneous transcatheter embolisation has been used for control of arterial haemorrhage and has been shown to be effective in the chest, abdomen, pelvis, and extremities in most patients.<sup>4-6</sup> Most interventional radiologists are familiar with the use of mechanical agents such as coil or particulate agents, although experience with liquid agents such as adhesives or



glues is generally more limited.<sup>7</sup> Many interventional radiologists are reluctant to use liquid adhesives because of the potential risk of complicated ischaemic injury and the difficulty in handling the agent.<sup>8</sup>

NBCA is a well-known liquid adhesive used in the vascular system. It was approved in 2000 by the US Food and Drug Administration for use in cerebral arteriovenous malformations (AVMs). Some series have reported clinical success rates of 75% to 100%<sup>8-11</sup> when the technique has been used in off-label applications, for example, to treat AVMs in peripheral circulation,<sup>12</sup> non-neurologic pseudoaneurysms,<sup>9,10</sup> and acute arterial haemorrhage at various anatomical locations.<sup>6,9</sup> NBCA has distinct advantages over absolute alcohol, which is another liquid embolisation agent used by some interventional radiologists, in that it does not necessarily permeate to capillary level, and therefore does not inevitably result in tissue infarction.<sup>11</sup> Its low viscosity also allows easy delivery of the agent via a microcatheter.

A disadvantage, however, is that its lack of radiopacity and its rapid polymerisation time make it difficult to use.<sup>8</sup> Mixing it with iodised oil not only opacifies the agent (Figure 3b) but also slows down the polymerisation time. Pollak and White<sup>7</sup> suggested that the estimated in-vivo polymerisation time for NBCA to iodised oil mixtures of between 1:1 and 1:4 was 1 to 4 seconds, with a linear relationship to the mixture.

Major considerations for choosing an embolic agent are speed and reliability of delivery, duration of occlusive effect, and preservation of normal tissue. Transcatheter embolisation for control of acute haemorrhage is typically performed with metallic coils and / or particulate agents.<sup>13</sup> Nonetheless, selective placement of the catheter close to and beyond the bleeding site, especially in small and tortuous vessels, may be difficult.<sup>9</sup> It is also technically difficult and time-consuming if the lesion is supplied by many collateral vessels, or if there are many efferent arteries originating from the pseudoaneurysms.<sup>9</sup> NBCA has the advantage of embolising small arteries and collateral circulations that are difficult for metallic coils.

In our case series, angiographic success was achieved in 100% of patients and the overall success rate was 76.5% (13 in 17 patients). Results are comparable with a previously published case series by Kish et al,<sup>11</sup> who reported a 75% success rate (12 out of 16)

of NBCA embolisation with or without other embolic agent in patients with acute arterial haemorrhage. Retrospective studies published by Song et al,<sup>10</sup> Jae et al,<sup>8</sup> and Yamakado et al<sup>9</sup> reported an angiographic success rate of 94%, 100%, and 100% for NBCA embolisation in patients with pseudoaneurysms, non-variceal upper gastrointestinal bleeding, and ruptured pseudoaneurysms, respectively.

Potential complications of transcatheter embolisation with NBCA include end-organ ischaemia (such as bowel infarction in case of embolisation for gastrointestinal haemorrhage), abscess formation, and entrapment of the delivery catheter within the embolised artery.<sup>14-16</sup> Ischaemia, necrosis or ulceration of skin or mucosa is also a possible sequelae of non-target distal embolisation injury in cases that involve the head and neck or chest wall. The delivery catheter must be removed promptly after each injection to avoid entrapment. Embolisation of untargeted sites or reflux of glue into another innocent vessel by over-injection is also a possible complication of NBCA embolisation. Yamakado et al,<sup>9</sup> Kish et al,<sup>11</sup> Jae et al,<sup>8</sup> and Song et al<sup>10</sup> reported no cases of organ infarction, infectious complications, or catheter entrapment in their case series. In our series, we encountered only one case with evidence of non-targeted end-organ embolisation (small splenic infarcts) and suspected liver abscess at follow-up CT, and no additional treatment was required and there were no clinical sequelae. No other major end-organ ischaemia, including skin and mucosa of the head and neck or chest wall, was documented in our case series and there was no evidence of catheter entrapment. The results of our cases are comparable with these series.

## CONCLUSION

This study demonstrates that NBCA embolisation with or without other embolic agent is technically feasible, effective, and safe to control acute arterial haemorrhage and to embolise pseudoaneurysms due to various causes and at different anatomical locations.

## REFERENCES

1. Moore C, Murphy K, Gailloud P. Improved distal distribution of n-butyl cyanoacrylate glue by simultaneous injection of dextrose 5% through the guiding catheter: technical note. *Neuroradiology*. 2006;48:327-32. [crossref](#)
2. Rosen RJ, Contractor S. The use of cyanoacrylate adhesives in the management of congenital vascular malformations. *Semin Intervent Radiol*. 2004;21:59-66. [crossref](#)
3. Sacks D, McClenny TE, Cardella JF, Lewis CA. Society of

- Interventional Radiology clinical practice guidelines. *J Vasc Interv Radiol.* 2003;14:S199-202. [cross ref](#)
4. Keller FS, Rösch J, Baur GM, Taylor LM, Dotter CT, Porter JM. Percutaneous angiographic embolization: a procedure of increasing usefulness: review of a decade of experience. *Am J Surg.* 1981;142:5-13. [cross ref](#)
  5. Gabelmann A, Görlich J, Merkle EM. Endovascular treatment of visceral artery aneurysms. *J Endovasc Ther.* 2002;9:38-47. [cross ref](#)
  6. Schenker MP, Duszak R Jr, Soulen MC, Smith KP, Baum RA, Cope C, et al. Upper gastrointestinal hemorrhage and transcatheter embolotherapy: clinical and technical factors impacting success and survival. *J Vasc Interv Radiol.* 2001;12:1263-71. [cross ref](#)
  7. Pollak JS, White RI Jr. The use of cyanoacrylate adhesives in peripheral embolization. *J Vasc Interv Radiol.* 2001;12:907-13. [cross ref](#)
  8. Jae HJ, Chung JW, Jung AY, Lee W, Park JH. Transcatheter arterial embolization of nonvariceal upper gastrointestinal bleeding with N-butyl cyanoacrylate. *Korean J Radiol.* 2007;8:48-56. [cross ref](#)
  9. Yamakado K, Nakatsuka A, Tanaka N, Takano K, Matsumura K, Takeda K. Transcatheter arterial embolization of ruptured pseudoaneurysms with coils and n-butyl cyanoacrylate. *J Vasc Interv Radiol.* 2000;11:66-72. [cross ref](#)
  10. Song HH, Won YD, Kim YJ. Transcatheter N-butyl cyanoacrylate embolization of pseudoaneurysms. *J Vasc Interv Radiol.* 2010;21:1508-11. [cross ref](#)
  11. Kish JW, Katz MD, Marx MV, Harrell DS, Hanks SE. N-butyl cyanoacrylate embolization for control of acute arterial hemorrhage. *J Vasc Interv Radiol.* 2004;15:689-95. [cross ref](#)
  12. Bank WO, Kerber CW, Cromwell LD. Treatment of intracerebral arteriovenous malformations with isobutyl 2-cyanoacrylate: initial clinical experience. *Radiology.* 1981;139:609-16. [cross ref](#)
  13. Reber PU, Baer HU, Patel AG, Wildi S, Triller J, Büchler MW. Superselective microcoil embolisation: treatment of choice in high-risk patients with extrahepatic pseudoaneurysms of the hepatic arteries. *J Am Coll Surg.* 1998;186:325-30. [cross ref](#)
  14. Stoesslein F, Ditscherlein G, Romaniuk PA. Experimental studies on new liquid embolization mixtures (histoacryl-lipiodol, histoacryl-panthopaque). *Cardiovasc Intervent Radiol.* 1982;5:264-7. [cross ref](#)
  15. Kazekawa K, Iwata H, Shimozuru T, Sampei K, Sakaki N, Morikawa N, et al. Nontoxic embolic liquids for treatment of arteriovenous malformations. *J Biomed Mater Res.* 1997;38:79-86. [cross ref](#)
  16. Savader SJ, Trerotola SO, Merine DS, Venbrux AC, Osterman FA. Hemobilia after percutaneous transhepatic biliary drainage: treatment with transcatheter embolotherapy. *J Vasc Interv Radiol.* 1992;3:345-52. [cross ref](#)