

---

---

## CASE REPORT

---

---

# Incarcerated Right Diaphragmatic Hernia: a Rare Sequela of Open Radiofrequency Ablation for Hepatocellular Carcinoma

TF Lee, CY Chu, CS Cheng, JLS Khoo

Department of Radiology, Pamela Youde Nethersole Eastern Hospital, Chai Wan, Hong Kong

### ABSTRACT

*Hepatocellular carcinoma is a common malignancy in this locality due to the high prevalence of hepatitis B carriers. Radiofrequency ablation is frequently used for treatment of hepatocellular carcinoma. Thermal injury to the diaphragm during radiofrequency ablation for liver tumour is a rare complication. Thermal injury may lead to a defect in the diaphragm and hernia formation. Intestinal obstruction can result from incarceration of the diaphragmatic hernia. We present a patient with intestinal obstruction due to incarcerated diaphragmatic hernia after radiofrequency ablation. The causes, presentation, and imaging findings of this condition are reviewed.*

*Key Words: Carcinoma, hepatocellular; Catheter ablation; Hernia, diaphragmatic*

## 中文摘要

### 右側嵌頓性膈疝：開放式射頻消融治療肝細胞癌後的一種罕見後遺症

李騰飛、朱志揚、鄭志成、邱麗珊

本港有不少乙型肝炎病毒攜帶者，這也令肝癌的發病變得普遍。射頻消融術經常用於治療肝癌。射頻消融的過程中產生的熱量導致橫隔膜損傷相當罕見。熱損傷可能會導致橫隔膜受損及膈疝的形成。而膈疝如果嵌頓後也可導致腸梗阻。本文報告一名肝癌患者在接受射頻消融術後併發嵌頓性膈疝而導致腸梗阻的病例，以此討論這種併發症的原因、表現和影像學檢查結果。

### INTRODUCTION

Hepatocellular carcinoma (HCC) is the fourth commonest cancer in Hong Kong<sup>1</sup> largely due to the high prevalence of hepatitis B carriers (up to 10% of the population).<sup>2</sup> Radiofrequency ablation (RFA) is a frequently used minimally invasive treatment for HCC and hepatic metastases.<sup>3</sup> RFA achieves tissue destruction by applying localised heat. Although RFA

is considered a relatively safe procedure, various complications have been associated with the procedure. Thermal injury to the diaphragm has been reported as one of the complications of RFA.<sup>3</sup> Underlying medical conditions and local inflammatory reactions may impair tissue repair, which may, in turn, result in delayed formation of diaphragmatic defect. Herniation of bowel through the diaphragmatic defect has been

---

---

*Correspondence: Dr Tang-Fei Lee, Department of Radiology, Pamela Youde Nethersole Eastern Hospital, 3 Lok Man Road, Chai Wan, Hong Kong.  
Email: leetangfei@gmail.com*

Submitted: 7 Jul 2014; Accepted: 27 Oct 2014.

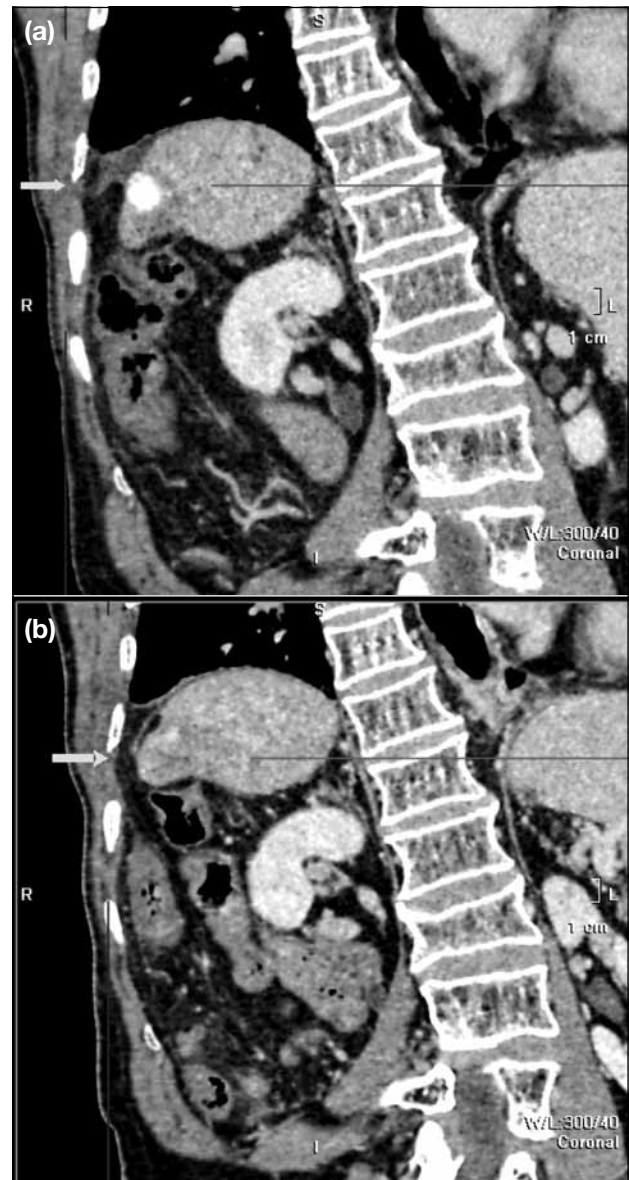
rarely reported, with most being delayed in presentation. Patients may present acutely with incarceration of the herniated bowel or intestinal obstruction. To the best of our knowledge, only one patient with small bowel herniation with incarceration through the post-RFA diaphragmatic defect after treatment for HCC has been previously reported.<sup>4</sup> It is surprising that this complication has not been reported in our locality since HCC is a relatively common disease in Hong Kong. We report on a patient attending the Pamela Youde Nethersole Eastern Hospital, Hong Kong, with this rare presentation.

### CASE REPORT

In August 2008, an 81-year-old man with a history of cholecystectomy and hepatitis B cirrhosis was diagnosed with a 3-cm segment VII exophytic HCC. Three sessions of transarterial chemoembolisation followed by radiotherapy were performed. Subsequent magnetic resonance imaging (MRI) showed no viable tumour. Four years later, follow-up computed tomography (CT) and MRI showed a new 1.1-cm anterior right lobe enhancing lesion. Hepatic resection was not contemplated due to limited liver reserve. RFA via an open approach was performed. However, the anterior right lobe lesion could not be located by intra-operative ultrasound (US), therefore RFA was performed on the previous 3-cm segment VII HCC. A 17-gauge 3-cm Cool-tip needle (Covidien, Inc., Boulder [CO], USA) was used. Three ablation cycles were performed on this lesion. Subsequently, the patient was followed up by the surgeons.

On the post-RFA surveillance CT scans performed 12 and 18 months after RFA, a new small right posterolateral diaphragmatic defect with herniation of a small amount of intra-abdominal fat could be retrospectively identified, although it was not reported. No bowel herniation was evident and no sign of incarceration was present at that time (Figure 1).

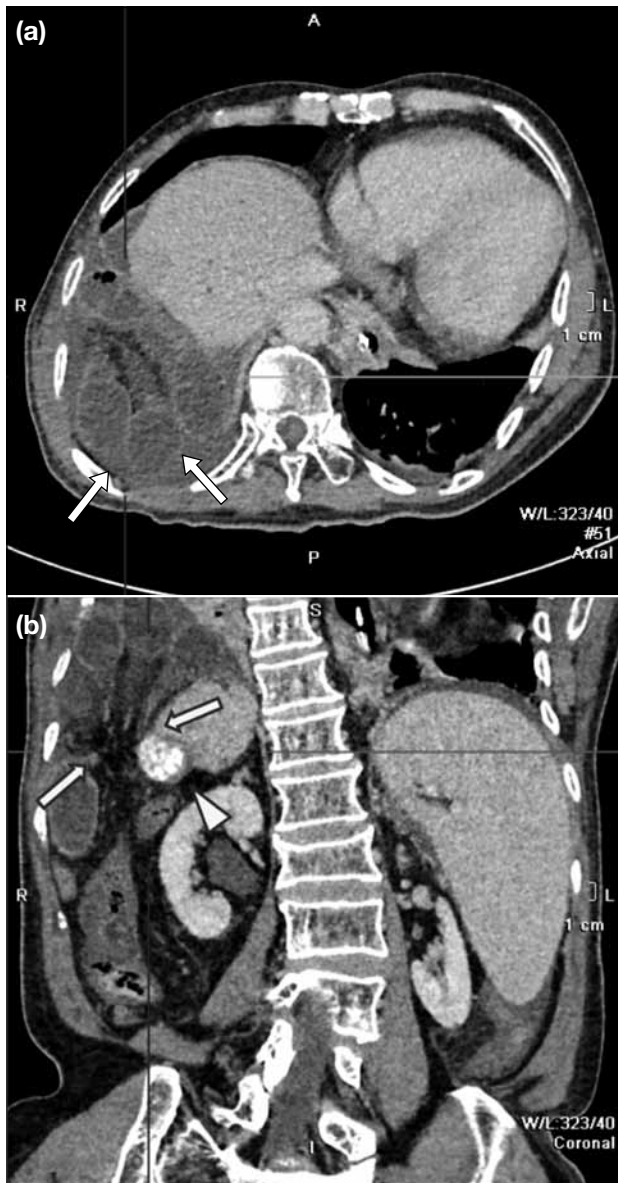
Approximately 22 months after RFA, the patient was admitted with a 1-day history of vomiting and no bowel output. On physical examination there was mild abdominal distension, and abdominal radiograph showed dilated ileum compatible with intestinal obstruction. In view of the clinical suspicion of intestinal obstruction, an urgent CT of the abdomen was arranged, which showed dilated small bowel loops with air fluid levels and string-of-bead sign, in keeping with mechanical intestinal obstruction. A 2.0-cm defect was found in



**Figure 1.** Coronal reformatted computed tomography scans performed (a) 12 months after radiofrequency ablation (RFA) demonstrating a small right diaphragmatic defect with herniation of a small amount of abdominal fat into the right pleural cavity (arrow), and (b) 18 months after RFA showing a similar defect with an increased amount of fat herniated into the right pleural cavity (arrow).

the posterolateral right hemidiaphragm, with loops of dilated small bowel herniating through the defect into the right lower pleural cavity. Mucosal enhancement of the herniated bowel was slightly diminished (Figure 2). A working diagnosis of incarcerated diaphragmatic hernia with closed loop obstruction was made.

Emergency operation was performed, which confirmed



**Figure 2.** (a) An axial computed tomography scan performed on admission showing herniation of a small bowel loop to the right pleural cavity through a right posterolateral diaphragmatic defect. There is diminished mucosal enhancement of the small bowel (arrows). (b) A coronal reformatted image clearly demonstrating the defect (arrows), which is lateral to the hepatocellular carcinoma treated with prior transarterial chemoembolisation and radiofrequency ablation (arrowhead).

the CT findings of incarcerated diaphragmatic hernia with a defect in the posterolateral right hemidiaphragm. Approximately 20 cm of proximal ileum was found to be herniating through the diaphragmatic defect. The herniated bowel was reduced after rewarming. A 1.8-cm length of small bowel was resected because of bowel ischaemia. The patient was discharged 11 days after surgery.

Unfortunately, the patient was readmitted 3 days after discharge because of acute coronary syndrome and died 2 days after admission.

## DISCUSSION

RFA has been used as treatment for unresectable HCC, primary treatment for resectable HCC, recurrent HCC after partial hepatectomy, and bridging therapy before liver transplantation. Depending on factors such as Child-Pugh class, number of tumours, and local treatment policy, HCC up to 5 cm in size may be treated by RFA.<sup>5</sup> RFA is a localised thermal treatment technique designed to induce tumour destruction by heating the tumour tissue to a temperature exceeding 60°C. Heating causes intracellular protein denaturation, cell membrane destruction, and dehydration of intracellular and extracellular tissue, hence leading to coagulative necrosis.<sup>5,6</sup> RFA can be administered by using percutaneous, laparoscopic, or open approaches. Percutaneous RFA can be performed under local anaesthesia under image guidance. Laparoscopic or open approaches allow repeated placement of the RFA electrode at multiple sites to ablate larger tumours. The use of intra-operative US also provides better resolution of the number and location of the liver tumours.<sup>6</sup>

Major complications are seen in 2.2% of patients treated with RFA. The most frequently encountered major complications include peritoneal bleeding, tumour seeding, liver abscess, and bowel perforation.<sup>3</sup> Complications related to RFA can be classified into four different types: thermal, mechanical, septic, and other unexplained causes. Thermal damage includes bowel perforation, biliary stenosis, and grounding pad burns. Thermal damage of the gastrointestinal wall occurs in 0.7% of patients. Symptoms typically occur several days after the procedure.<sup>3</sup>

For tumours lying close to liver dome, thermal injury to the diaphragm is possible. Although the true prevalence of diaphragmatic defect due to RFA-related injury is unknown, thermal injury to the diaphragm appears to be uncommon.<sup>3</sup> In a review of 3670 patients undergoing RFA, only five incidences of diaphragmatic burn were noted in the percutaneous RFA group, resulting in bile leak, abscess, or diaphragmatic paresis. Among patients undergoing RFA via the laparoscopic or open approach, there was no recorded RFA-related visceral burn.<sup>4</sup> We believe this is due to the fact that the adjacent organs can be mobilised to avoid injury during laparoscopic and open RFA. To our knowledge, since the first

reported case of diaphragmatic hernia complicating RFA in 2003,<sup>7</sup> six patients with diaphragmatic hernia after RFA have been reported in the English literature, with onset ranging from 9 to 18 months after RFA.<sup>5,7-11</sup> All cases were associated with the percutaneous approach. Imaging guidance by US or CT was used. The diaphragmatic defects ranged from 2 to 5 cm.<sup>5,7-11</sup> Herniation of the small bowel was found in two patients,<sup>5,8</sup> while the rest involved herniation of the large bowel.<sup>7,9-11</sup> Three of the patients presented with acute abdominal symptoms suggesting incarceration or intestinal obstruction.<sup>7,8,10</sup> The other patients presented with dyspnoea.<sup>7,9</sup> One patient was asymptomatic and the defect was detected on follow-up imaging<sup>11</sup> (Table<sup>5,7-11</sup>).

In this patient, the diaphragmatic defect was new and located close to the segment VII HCC, which was the previous RFA site, thus the diaphragmatic defect was likely to be related to RFA diaphragmatic injury rather than a congenital Bochdalek hernia. Aside from the patient reported by di Francesco et al,<sup>5</sup> this patient is probably the only one with incarcerated small bowel herniation through post-RFA diaphragmatic defect, although HCC is relatively common in our locality.

Artificially induced pleural effusion, ascites, or intra-abdominal carbon dioxide insufflation have been suggested to reduce the risk of diaphragmatic burn in percutaneous RFA.<sup>12-15</sup> Pleural effusion or ascites may improve the visibility of the lesion.<sup>12</sup> Fluid also has the ability to help conduct heat away from the ablation zone.<sup>16</sup> There is currently no clinical study using such manoeuvres to avoid complications with the open approach. Animal study has suggested that intraperitoneal injection of 5% dextrose may decrease the frequency and severity of diaphragmatic injury.<sup>16</sup> However, applicability of such manoeuvres to this patient might have been problematic. The presence of

adhesions due to prior operation may have rendered separation of the liver from the diaphragmatic surface difficult. This may also predispose to more severe thermal injury. The operator should anticipate the possibility of such complications, especially in exophytic or subdiaphragmatic lesions. This potential complication should also be considered during the case selection process.

The reason for delayed presentation of diaphragmatic hernia has not been fully elucidated. It has been suggested that partial thermal injury results from an inflammatory response that leads to fibrosis, which ultimately weakens the tissues and causes a defect.<sup>10</sup> The presence of inflammatory changes, ascites, and pleural effusion after the procedure may affect the healing process.<sup>17</sup> Co-existing medical conditions such as diabetes mellitus and poor liver function, and constant motion of the diaphragm may also impair tissue repair.<sup>11,18</sup> In this patient, previous radiotherapy may also have been a contributing factor. Radiation injury and fibrosis may further impair tissue repair after RFA-induced thermal injury. In addition, a small defect with small herniation was possibly present early, which might have been overlooked on follow-up imaging, especially when asymptomatic. Gradually, the defect enlarged and more intra-abdominal content herniated. This patient finally presented acutely with incarceration.

In addition to the thermal injury, which creates a diaphragmatic defect, contributing factors for development of diaphragmatic hernia may include chronic increase in intra-abdominal pressure such as with constipation and pressure difference between the pleural and abdominal cavities.<sup>18,19</sup> We postulate that progression of cirrhosis and the presence of an exophytic liver mass may also have contributed since this may enlarge the potential space between the

**Table.** Summary of previously reported patients with diaphragmatic hernia after radiofrequency ablation.<sup>5,7-11</sup>

Study	Age (years)/sex	Time to onset of diaphragmatic defect since RFA (months)	RFA approach	Size of defect (cm)	Herniated content	Symptoms of intestinal obstruction or incarceration	Treatment
Koda et al, 2003 <sup>7</sup>	61/F	13	Percutaneous, USG-guided	5	Large bowel	Yes	Surgery
Shibuya et al, 2006 <sup>8</sup>	72/M	18	Percutaneous, USG-guided	NR	Small bowel	No	Surgery
di Francesco et al, 2008 <sup>5</sup>	49/M	15	Percutaneous, USG-guided	3	Small bowel	Yes	Surgery
Yamagami et al, 2011 <sup>9</sup>	71/F	9	Percutaneous, CT-guided	NR	Large bowel	No	Conservative
Singh et al, 2011 <sup>10</sup>	46/F	11	Percutaneous, USG-guided	5	Large bowel	Yes	Surgery
Kim et al, 2013 <sup>11</sup>	61/M	9	Percutaneous, USG-guided	2	Large bowel	No	Conservative

Abbreviations: CT = computed tomography; NR = not reported; RFA = radiofrequency ablation; USG = ultrasonography.

posterior and lateral surface of the right lobe of the liver and the right hemidiaphragm, allowing mobile intra-abdominal contents such as small bowel to fill this space and predispose the patient to diaphragmatic hernia.

Regarding the imaging diagnosis of diaphragmatic hernias, routine chest radiograph is usually taken when a patient first presents to hospital with acute symptoms. On chest radiograph, the herniated bowel loop may appear as gas-filled lucencies or a soft tissue mass above the level of the diaphragm.<sup>20</sup> On the right side, these signs might be confused with Chilaiditi syndrome. If the hernia appears more homogeneous, it might be mistaken for consolidation, pericardial fat pad, sequestration, or other mediastinal mass.<sup>20</sup>

CT of the chest or abdomen with intravenous contrast readily clears any doubt about the radiographic findings, better demonstrates the presence of hernia, and shows the presence of complications, including bowel ischaemia and perforation. Thin-slice CT with multiplanar reformatting helps directly visualise the diaphragmatic defect.

For reporting radiologists, the integrity of the diaphragm has to be carefully reviewed. Comparison with pretreatment CT would be helpful to detect a small asymptomatic hernia. This provides valuable information for the surgeons to decide on further management for the patient. A high index of suspicion and timely investigation to confirm the diagnosis are crucial. This is especially true when there is a history of RFA performed close to the liver dome.

There have been variations in the treatment of diaphragmatic hernia after RFA. Some reports have adopted a conservative approach, while others have opted for surgical repair.<sup>5,7-11</sup> A conservative approach was adopted for two reported patients.<sup>9,11</sup> While one may argue for conservative management if the hernias are asymptomatic and there is a high operative risk in these patients due to existing liver or other medical conditions, the risk for emergency operation due to development of incarceration also needs to be considered. As illustrated by this patient, the previously asymptomatic diaphragmatic defect may become acute with incarceration and bowel ischaemia. The risk and benefit for elective operation for an asymptomatic hernia versus an emergency operation for incarcerated hernia have to be weighed and clearly communicated to the patient.

In conclusion, we present a patient with an unusual cause of intestinal obstruction due to incarceration of a diaphragmatic hernia after open RFA. Clinicians and radiologists should keep in mind the possibility of diaphragmatic hernia leading to intestinal obstruction in patients with a previous history of RFA. Prompt investigation with CT to confirm the diagnosis and timely operative treatment can be life-saving. For reporting radiologists, it is important to scrutinise the integrity of the diaphragm to assess for any subclinical diaphragmatic injury or hernia that may help to decide the further management for post-RFA patients.

## REFERENCES

1. Summary of cancer statistics in Hong Kong in 2011. Hong Kong Cancer Registry. Available from: <http://www3.ha.org.hk/cancereg/Summary%20of%20CanStat%202011.pdf>. Accessed 1 Jun 2014.
2. Lau GK, Lai CL, Wu PC. The natural history of chronic hepatitis B infection. *Hong Kong Med J*. 1997;3:283-8
3. Livraghi T, Solbiati L, Meloni MF, Gazelle GS, Halpern EF, Goldberg SN. Treatment of focal liver tumors with percutaneous radio-frequency ablation: complications encountered in a multicenter study. *Radiology*. 2003;226:441-51. [crossref](#)
4. Mulier S, Mulier P, Ni Y, Miao Y, Dupas B, Marchal G, et al. Complications of radiofrequency coagulation of liver tumours. *Br J Surg*. 2002;89:1206-22. [crossref](#)
5. di Francesco F, di Sandro S, Doria C, Ramirez C, Iaria M, Navarro V, et al. Diaphragmatic hernia occurring 15 months after percutaneous radiofrequency ablation of a hepatocellular cancer. *Am Surg*. 2008;74:129-32.
6. Lau WY, Lai EC. The current role of radiofrequency ablation in the management of hepatocellular carcinoma: a systematic review. *Ann Surg*. 2009;249:20-5. [crossref](#)
7. Koda M, Ueki M, Maeda N, Murawaki Y. Diaphragmatic perforation and hernia after hepatic radiofrequency ablation. *AJR Am J Roentgenol*. 2003;180:1561-2. [crossref](#)
8. Shibuya A, Nakazawa T, Saigenji K, Furuta K, Matsunaga K. Diaphragmatic hernia after radiofrequency ablation therapy for hepatocellular carcinoma. *AJR Am J Roentgenol*. 2006;186(5 Suppl):S241-3. [crossref](#)
9. Yamagami T, Yoshimatsu R, Matsushima S, Tanaka O, Miura H, Nishimura T. Diaphragmatic hernia after radiofrequency ablation for hepatocellular carcinoma. *Cardiovasc Intervent Radiol*. 2011;34 Suppl 2:S175-7. [crossref](#)
10. Singh M, Singh G, Pandey A, Cha CH, Kulkarni S. Laparoscopic repair of iatrogenic diaphragmatic hernia following radiofrequency ablation for hepatocellular carcinoma. *Hepatol Res*. 2011;41:1132-6. [crossref](#)
11. Kim JS, Kim HS, Myung DS, Lee GH, Park KJ, Cho SB, et al. A case of diaphragmatic hernia induced by radiofrequency ablation for hepatocellular carcinoma. *Korean J Gastroenterol*. 2013;62:174-8. [crossref](#)
12. Uehara T, Hirooka M, Ishida K, Hiraoka A, Kumagi T, Kisaka Y, et al. Percutaneous ultrasound-guided radiofrequency ablation of hepatocellular carcinoma with artificially induced pleural effusion and ascites. *J Gastroenterol*. 2007;42:306-11. [crossref](#)
13. Raman SS, Aziz D, Chang X, Sayre J, Lassman C, Lu D. Minimizing diaphragmatic injury during radiofrequency ablation: efficacy of intraabdominal carbon dioxide insufflation. *AJR Am J Roentgenol*. 2004;183:197-200. [crossref](#)

14. Iwai S, Sakaguchi H, Fujii H, Kobayashi S, Morikawa H, Enomoto M, et al. Benefits of artificially induced pleural effusion and/or ascites for percutaneous radiofrequency ablation of hepatocellular carcinoma located on the liver surface and in the hepatic dome. *Hepatogastroenterology*. 2012;59:546-50.
15. Kim YS, Rhim H, Paik SS. Radiofrequency ablation of the liver in a rabbit model: creation of artificial ascites to minimize collateral thermal injury to the diaphragm and stomach. *J Vasc Interv Radiol*. 2006;17:541-7. [crossref](#)
16. Laeseke PF, Sampson LA, Brace CL, Winter TC 3rd, Fine JP, Lee FT Jr. Unintended thermal injuries from radiofrequency ablation: protection with 5% dextrose in water. *AJR Am J Roentgenol*. 2006;186(5 Suppl):S249-54. [crossref](#)
17. Minami Y, Kudo M. Radiofrequency ablation of hepatocellular carcinoma: a literature review. *Int J Hepatol*. 2011;2011:104685. [crossref](#)
18. Hawxby AM, Mason DP, Klein AS. Diaphragmatic hernia after right donor and hepatectomy: a rare donor complication of partial hepatectomy for transplantation. *Hepatobiliary Pancreat Dis Int*. 2006;5:459-61.
19. Kanazawa A, Yoshioka Y, Inoi O, Murase J, Kinoshita H. Acute respiratory failure caused by an incarcerated right-sided adult bochdalek hernia: report of a case. *Surg Today*. 2002;32:812-5. [crossref](#)
20. Eren S, Ciriş F. Diaphragmatic hernia: diagnostic approaches with review of the literature. *Eur J Radiol*. 2005;54:448-59. [crossref](#)