
CASE REPORT

Extensive Soft Tissue Necrosis Due to Extravasation of Computed Tomography Contrast Medium

JH Kwon¹, JS Kim¹, SR Eo²

¹Department of Radiology, and ²Department of Plastic and Reconstructive Surgery, Dongguk University Medical Center, Dongguk University Graduate School of Medicine, Gyeonggi-do, South Korea

ABSTRACT

Extravasation of contrast medium is a complication of contrast-enhanced computed tomography studies. Clinical presentations include minimal swelling, erythema and, when the extravasated volume is large, ulceration, compartment syndrome, and skin necrosis. Here we present an 80-year-old woman with progressive swelling and extensive soft tissue necrosis of the dorsal left hand due to contrast medium extravasation. After treatment by skin graft, she showed no long-term complications. Patients at risk for contrast medium extravasation should be closely monitored and appropriately managed.

Key Words: Compartment syndromes; Extravasation of diagnostic and therapeutic materials; Soft tissue injuries

中文摘要

電腦斷層掃描造影劑外滲引致的廣泛性軟組織壞死

JH Kwon、JS Kim、SR Eo

造影劑外滲是電腦斷層（CT）增強掃描的一種併發症，臨床表現包括輕微腫脹和紅斑。如果大量造影劑外滲，更會出現潰爛、筋膜間室綜合徵和皮膚壞死。本文報告一名80歲女性因造影劑外滲而出現漸進性腫脹，以及左手手背廣泛性軟組織壞死。病人接受皮膚移植治療，無長期併發症發生。應密切監察造影劑外滲病人並施以適當治療。

INTRODUCTION

Extravasation of iodinated contrast medium (CM) is a well-known complication of intravenous administration for contrast-enhanced computed tomography (CT).¹⁻³ A small volume of extravasated CM may cause localised pain, oedema, and erythema; all of which resolve spontaneously.^{4,5} A large volume of extravasation is rare and may result in skin ulceration and extensive soft tissue necrosis.^{6,7} With the increased use of CT imaging in elderly people, patients with compromised

consciousness and high-speed injection, significant CM extravasation has become more common.⁵ Physicians should be aware of the signs of extravasation, its potentially serious consequences, and its appropriate management. Here, we present a patient with a large volume of CM extravasation in her dorsal hand, resulting in extensive soft tissue necrosis that was successfully treated with skin graft. This research received waiver approval by the Dongguk University Ilsan Hospital institutional review board, which also

Correspondence: Dr Jeung-Sook Kim, Department of Radiology, Dongguk University Ilsan Hospital, 814 Siksa-dong, Ilsandong-gu, Goyang-si, Gyeonggi-do, 410-773, South Korea.
Tel: +82 31 961-7823; Fax: +82 31 961-8281; Email: jeungkim@dumc.or.kr

Submitted: 16 Mar 2015; Accepted: 24 Apr 2015.

waived the requirements to obtain informed consent.

CASE REPORT

In February 2014, an 80-year-old woman underwent enhanced chest CT scan for evaluation of pulmonary embolism. She was unconscious and confined to bed due to infarction of right middle cerebral artery territory, which occurred 1 year earlier. During CT scan, 100 ml of ioversol (Optiray 320; Mallinckrodt Canada, Quebec, Canada) was injected intravenously into the dorsal left hand at a rate of 4 ml/s through a rapid injector pump (Stellant CT Injection Systems; Medrad, Pittsburgh [PA], USA). Prior to the CM injection, the intravenous route had shown no abnormal findings when checked by injection and regurgitation of normal saline. Just after completion of the CT scan, CM extravasation of the dorsal left hand became apparent, manifesting as diffuse soft tissue swelling. The extravasated material was suctioned immediately by a squeezing manoeuvre. An ice pack was then applied to reduce swelling. Because she was unconscious, the patient was unable to complain of any subjective symptoms, such as pain.

The patient was managed conservatively with ice packs,

aseptic dressing, and elevation of the arm above the level of the heart. Approximately 6 hours after the CT scan, the dorsum of her hand showed global swelling, bullae, ecchymosis, and a change in skin colour; her fingers were pale. The lesion worsened and, after 4 days, skin necrosis was evident (Figure 1). The wound was managed conservatively for 4 weeks, after which the patient underwent a split-thickness skin graft (Figure 2). The patient's hand recovered well, without any complications.

DISCUSSION

The rate of CM extravasation is between 0.25% and 0.9% in adult patients in whom automated mechanical injectors are used for rapid bolus CM injection.⁵ The mechanical injection of CM using an automated power injector was shown to be responsible for the increasing incidence of contrast extravasation.^{1,3,4} Other factors related to extravasation are use of an indwelling intravenous line, metal needles, injections through a dorsal vein of the big toe or the dorsum of the hand, and tourniquet use.⁸ Patient factors related to extravasation are arterial or venous insufficiency, poor lymphatic drainage, oedema, low muscle mass, and subcutaneous

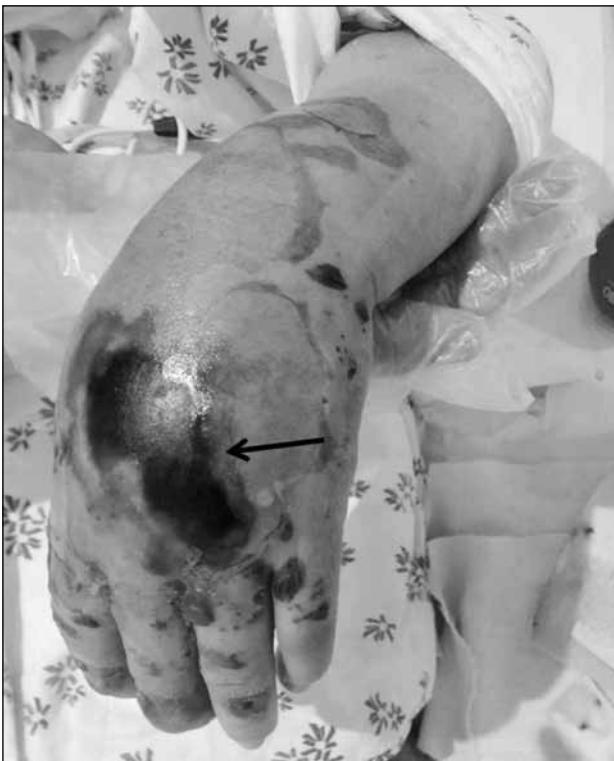

Figure 1. The left hand of an 80-year-old woman taken approximately 4 days after contrast medium extravasation. Severe soft tissue swelling, excoriation, and skin necrosis (arrow) of the dorsal left hand are seen.

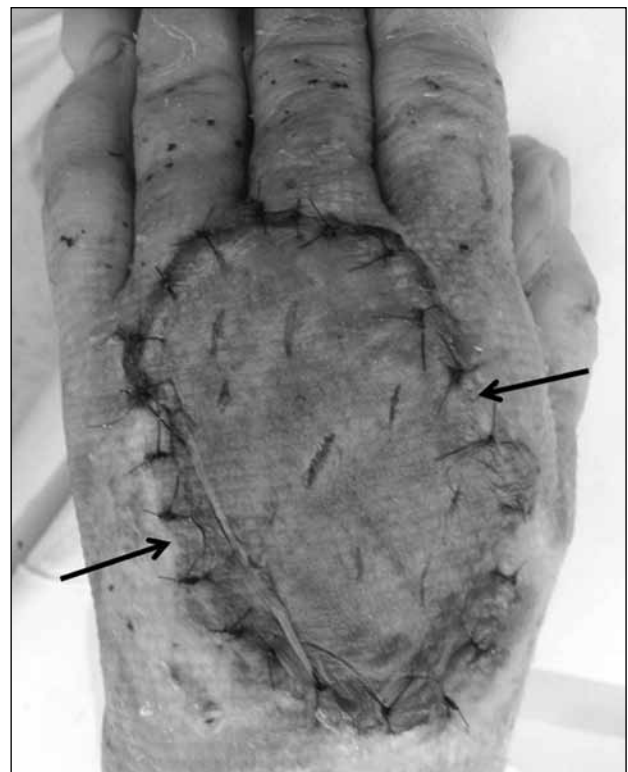


Figure 2. Photograph taken 4 weeks after contrast medium extravasation. The extensive soft tissue necrosis on the dorsal left hand is treated with a split-thickness skin graft (arrows).

tissue atrophy. Infants, young children, elderly people, and uncooperative and unconscious patients are also at higher risk of CM extravasation, as are patients receiving chemotherapy and obese patients, because of the fragility of the vein walls.^{1,2,9} Multiple factors are involved in the pathogenesis of injuries related to CM extravasation, including the osmolarity and cytotoxicity of the CM, the extravasated volume, and the mechanical compression effect of the extravasated material.^{1,8,10}

The clinical presentation of contrast extravasation varies from minor erythema, swelling, and tenderness to skin necrosis with progressive oedema and ulceration.^{1,8} Most patients have local swelling, stinging, or burning pain, whereas others may have no discomfort or symptoms.^{1,8} Most extravasation injuries resolve spontaneously in 2 to 4 days.^{1,8}

The risk of injury due to CM extravasation is in part dose-dependent, with a large volume being more likely to result in moderate or severe tissue damage.^{1,5,11} The classic five Ps (pain, pallor, paraesthesia, paralysis, and pulselessness) as well as palpable fullness (the sixth P) and pain with passive extension allow the clinical diagnosis of compartment syndrome.^{1,2,5,9,10} Extensive skin necrosis due to the extravasation of ionic, high-osmolar CM is a rare development^{6,7} and, until this patient, has not been reported as a result of the extravasation of non-ionic, low-osmolarity CM (ioversol).

There is no consensus regarding the optimum management of patients with contrast extravasation. A large proportion of extravasation injuries heal without surgery, such that a conservative approach — including elevation of the affected limb, topical application of heat or cold packs, and prevention of secondary infection — is often recommended.² Hyaluronidase, which breaks down connective tissue and facilitates the absorption of extravasated drugs into the vascular and lymphatic tissues, should be administered within 1 hour of extravasation to promote rapid dissipation.^{8,9} Surgical drainage or emergency suction within 6 hours can be effective.^{8,11} If compartment syndrome develops after CM extravasation, emergency fasciotomy must be performed within the first 6 hours to relieve neurovascular compromise.^{9,10}

This patient was unable to complain of pain caused by CM extravasation because she was unconscious. When, several hours after CM extravasation, her hand

became severely swollen and tense, with skin blistering and pale fingers, further management, such as surgical intervention or fasciotomy, rather than conservative treatment, was warranted to prevent worsening and eventual necrosis of the skin lesion.

CONCLUSION

Extensive skin necrosis is an extremely rare complication of CM extravasation in patients undergoing contrast-enhanced CT. A large volume of extravasated CM can result in severe injury, including compartment syndrome and soft tissue necrosis. Therefore, patients receiving a CM injection who are at high risk of extravasation should be closely monitored. Early identification and appropriate surgical management are essential when the extravasated volume is large and the clinical signs and symptoms suggest severe injury.

DECLARATION

The authors declare that they have no conflicts of interests.

REFERENCES

1. Tonolini M, Campari A, Bianco R. Extravasation of radiographic contrast media: prevention, diagnosis, and treatment. *Curr Probl Diagn Radiol*. 2012;41:52-5. [crossref](#)
2. Belzunegui T, Louis CJ, Torededia L, Oteiza J. Extravasation of radiographic contrast material and compartment syndrome in the hand: a case report. *Scand J Trauma Resusc Emerg Med*. 2011;19:9. [crossref](#)
3. Cohan RH, Ellis JH, Garner WL. Extravasation of radiographic contrast material: recognition, prevention, and treatment. *Radiology*. 1996;200:593-604. [crossref](#)
4. Kingston RJ, Young N, Sindhusake DP, Truong M. Study of patients with intravenous contrast extravasation on CT studies, with radiology staff and ward staff cannulations. *J Med Imaging Radiat Oncol*. 2012;56:163-7. [crossref](#)
5. Wang CL, Cohan RH, Ellis JH, Adusumilli S, Dunnick NR. Frequency, management, and outcome of extravasation of nonionic iodinated contrast medium in 69,657 intravenous injections. *Radiology*. 2007;243:80-7. [crossref](#)
6. Leung PC, Cheng CY. Extensive local necrosis following the intravenous use of X-ray contrast medium in the upper extremity. *Br J Radiol*. 1980;53:361-4. [crossref](#)
7. Ayre-Smith G. Tissue necrosis following extravasation of contrast material. *J Can Assoc Radiol*. 1982;33:104.
8. Bellin MF, Jakobsen JA, Tomassin I, Thomsen HS, Morcos SK, Thomsen HS, et al. Contrast medium extravasation injury: guidelines for prevention and management. *Eur Radiol*. 2002;12:2807-12.
9. Seleik H, Ozer H, Aygencel G, Turanlı S. Compartment syndrome in the hand due to extravasation of contrast material. *Arch Orthop Trauma Surg*. 2007;127:425-7. [crossref](#)
10. Jacobs JE, Birnbaum BA, Langlotz CP. Contrast media reactions and extravasation: relationship to intravenous injection rates. *Radiology*. 1998;209:411-6. [crossref](#)
11. D'Asero G, Tati E, Petrocelli M, Brinci L, Palla L, Cerulli P, et al. Compartment syndrome of the hand with acute bullous eruption due to extravasation of computed tomography contrast material. *Eur Rev Med Pharmacol Sci*. 2010;14:643-6.