
CASE REPORT

Radiation Dosimetry in Selective Internal Radiation Treatment in Patients with Portosystemic Shunts to Umbilical Veins

WH Ma¹, S Ng², WY Ho¹, M Law³, VHF Lee⁴, KK Wong³, WK Tso³

¹Nuclear Medicine Unit, Department of Radiology, Queen Mary Hospital, Pokfulam; ²Department of Clinical Oncology, Queen Elizabeth Hospital, Jordan; ³Department of Radiology, Queen Mary Hospital, Pokfulam; ⁴Department of Clinical Oncology, The University of Hong Kong, Pokfulam, Hong Kong

ABSTRACT

Tc-99m macroaggregate albumin (MAA) scintigraphy was routinely used to estimate the hepatopulmonary shunt prior to Yttrium-90 microsphere therapy. Visualisation of the recanalised umbilical vein / falciform artery in the breakthrough scan was not uncommon. Most centres believe that it is safe to proceed to selective internal radiation treatment with or without prophylactic embolisation based on clinical experience. This report aimed to calculate the patient-specific skin dosimetry based on the MAA single-photon emission computed tomography / computed tomography images and estimate the effect on skin after radioembolisation in patients with MAA uptake in recanalised umbilical vein.

Key Words: Radiopharmaceuticals/administration & dosage; Tomography, emission-computed, single-photon; Technetium Tc 99m aggregated albumin; Umbilical veins

中文摘要

接受選擇性體內放射治療患者從肝門脈系統分流至臍靜脈的輻射劑量

馬慧嫻、吳楚儀、何偉然、羅惠明、李浩勳、黃家建、曹偉權

鎇 [^{99m}Tc] 聚合白蛋白 (MAA) 顯像經常用於釷90微球治療前作為肝肺分流估計。掃描上觀察到的臍靜脈/鐮狀動脈的再管化並不少見。大多數治療中心認為根據臨床經驗，不論是否有預防性栓塞，進行選擇性體內放射治療都是安全的。本報告旨在根據MAA單光子發射電腦斷層/電腦斷層掃描圖像計算出特定病人的皮膚劑量，並估計在攝取了MAA臍靜脈再管化後的病人接受放射性栓塞後對皮膚的影響。

INTRODUCTION

Selective internal radiotherapy (SIRT) with Yttrium-90 is currently used to treat primary and metastatic unresectable liver tumours. Pretherapy Tc-

99m macroaggregate albumin (MAA) scan before Yttrium-90 radioembolisation is mandatory to assess lung shunting and extrahepatic uptake. Occasionally, we observe recanalised umbilical vein / falciform artery

Correspondence: Dr Wai-han Ma, Nuclear Medicine Unit, Department of Radiology, Queen Mary Hospital, Pokfulam, Hong Kong. Email: mawb@ba.org.hk

This paper was presented as a poster at the European Congress of Radiology 2015, March 4-8.

Submitted: 6 Aug 2015; Accepted: 26 Nov 2015.

in the breakthrough scan.¹

There have been some case reports of supraumbilical skin rash or even necrosis following conventional transarterial chemoembolisation or intra-arterial chemoinfusion in patients with hepatocellular carcinoma, caused by the flow of chemotherapeutic agents or ischaemic changes induced by embolisation of the hepatic falciform artery.²⁻⁴ Nonetheless, the results of several studies of SIRT in patients with patent falciform arteries — including patients who had superselective canalisation of hepatic arteries, had metal coils placed inside the falciform arteries, or had no prophylactic embolisation — suggest that the degree of radiation injury to the abdominal wall is not severe.⁵⁻⁷

This report aimed to calculate the skin dosimetry in patients with recanalised umbilical vein who underwent SIRT based on the MAA single-photon emission computed tomography / computed tomography (SPECT/CT) images.

CASE REPORT

In 2011, a routine ultrasound in a 61-year-old man revealed a liver lesion in segment VIII. Subsequent magnetic resonance imaging (MRI) scan confirmed the diagnosis of hepatocellular carcinoma. The patient was referred for radiofrequency ablation and chemotherapy. One year after treatment, MRI showed a new liver lesion in segment IVa. Given his progressive liver metastases despite chemotherapy, he was scheduled for SIRT using Yttrium-90 microspheres. Triphasic CT examination of the liver 3 weeks before MAA scan showed a 2.6 x 2.6 x 2.8 cm liver lesion with arterial enhancement and portal venous washout in segment IVa. Additionally, the patient had a similar lesion at the lateral and medial margins of the previously ablated area at segment VIII. Both lesions were suggestive of hepatocellular carcinoma. Triphasic CT examination of the liver also revealed a recanalisation of the umbilical vein and evidence of portal hypertension (Figure 1).

Three weeks after the triphasic CT scan, an angiogram was performed. The results showed normal hepatic artery anatomy without accessory or replaced hepatic artery from the superior mesenteric artery. We administered 159 MBq (4.3 mCi) Tc-99m MAA via the hepatic proper artery. Apart from uptake in the liver tumours, there was a linear pattern of tracer activity in the right paramedian region (Figure 2). The uptake was confirmed to be in the recanalised umbilical vein

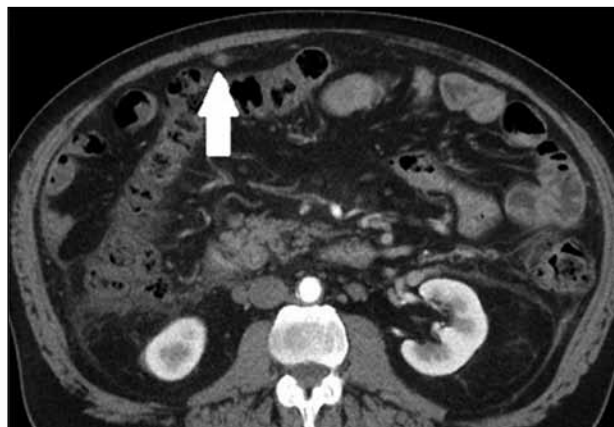

Figure 1. Axial triphasic computed tomographic scan of the abdomen shows a dilated vascular structure in the falciform ligament (arrow).

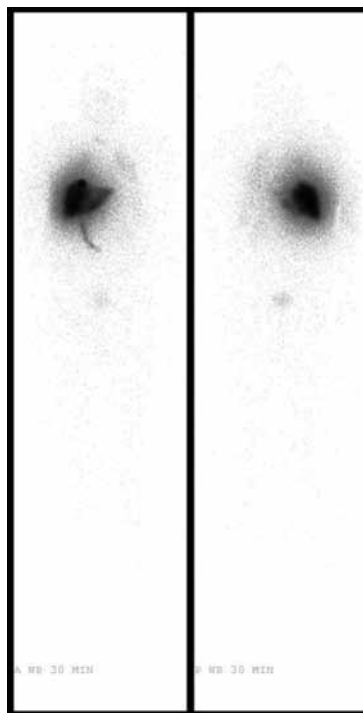


Figure 2. Whole-body planar images show a linear abdominal macroaggregate albumin uptake.

corresponding to the SPECT/CT images (Figure 3).

The dose estimation was based on the MAA SPECT/CT image (Figure 4). It was assumed that the MAA distribution was similar to the distribution of Yttrium-90. The 3D activity distribution on the Tc-99m MAA SPECT/CT images was convolved with the dose kernel of Yttrium-90 to compute the dose.^{8,9} To compute the skin dose, the patient body was revealed

on the CT transaxial images automatically using segmentation technique based on the CT density. Pixels with Hounsfield unit of > -350 were assigned as the body. Then a 5-mm wall was extracted from the body as the skin. The dose-volume histogram of the skin was computed.

Estimation of the side-effect on skin after radioembolisation was made by calculation of the maximum and mean skin dose based on this Tc-99m MAA SPECT/CT isodose map. The maximum skin dose estimated was low, with average maximum skin

dose of 1.8 Gy, and mean dose of 0.045 Gy. Acute dose-dependent effects of radiation on skin have been described. No acute effect is expected at skin doses of up to 2 Gy. Early transient erythema with a threshold dose of 2 Gy may develop as an acute reaction. In dose range of 6 Gy, erythema occurs. Between 14 and 18 Gy, dry and moist desquamation appears. For doses of >24 Gy, blister formation, ulceration, and necrosis may occur.¹⁰ In our case, it was clear that the risk of severe radiation dermatitis to the abdominal wall was minimal.

DISCUSSION

Patients with primary or metastatic non-resectable liver tumours were selected for SIRT. Tc-99m MAA was administered via the hepatic artery to simulate microsphere treatment. Tc-99m MAA scintigraphy preceded radioembolisation to assess the presence of extrahepatic deposition,^{11,12} calculate the percentage of lung shunting, and estimate the uptake in normal liver-to-tumour ratio. In case of shunting, prophylactic embolisation of the extrahepatic vessels at the time of the Tc-99m MAA assessment was recommended to prevent complications from extrahepatic deposition of microspheres.⁵

In our case, there was a linear accumulation of Tc-99m MAA in the right paramedial region on planar and SPECT/CT scan consistent with uptake in the recanalisation of the umbilical vein. Umbilical vein recanalisation occurs in about 9% of patients with portal hypertension^{13,14} or abnormal venous drainage of the liver. During fetal development, the umbilical vein directly communicates with the sinus venosus

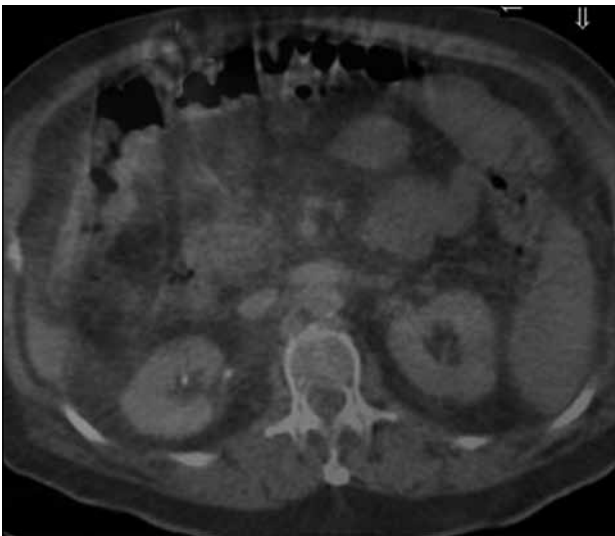

Figure 3. Axial single-photon emission computed tomography / computed tomography image shows the linear activity in a recanalised umbilical vein.

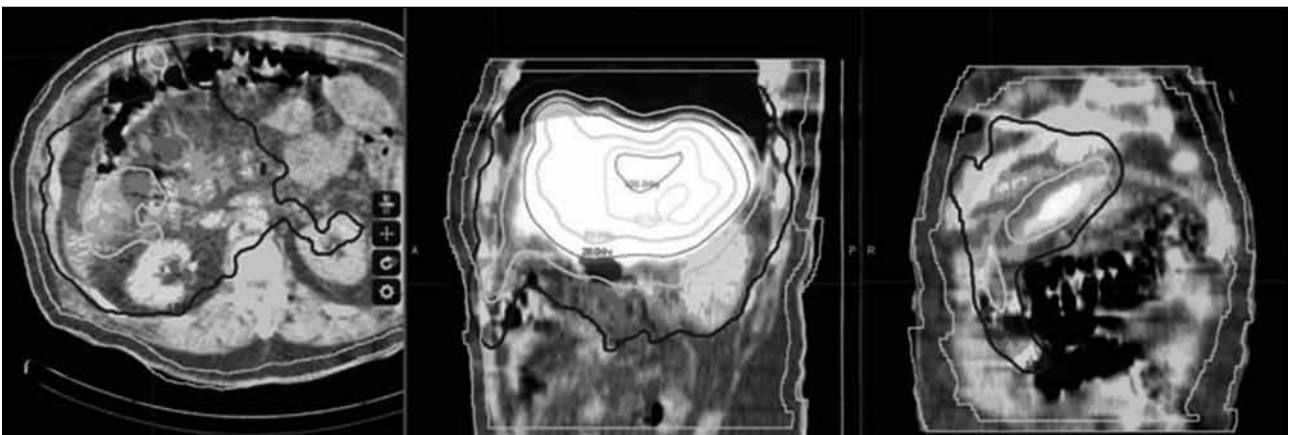


Figure 4. Dose distribution based on macroaggregate albumin single-photon emission computed tomography / computed tomography. The maximum skin dose is 1.8 Gy, and mean dose 0.045 Gy.

via the ductus venosus and eventually drains into the portal vein. The umbilical vein is obliterated within 2 to 3 weeks of birth. In portal hypertension, there is increased vascular resistance at the hepatic sinusoid that results in collateral pathways of portosystemic shunting. The importance of reopening of the umbilical vein in patients scheduled for SIRT is that the abdominal wall might receive radioactive microspheres through the recanalised umbilical vein.

To assess the feasibility of further SIRT, we generated a MAA SPECT/CT isodense map for the patient to estimate the accrual dose. The result signified that the dose received on the skin was not severe, even though no embolisation was performed or coils placed. With dose estimation, further treatment with SIRT remains feasible.

Based on the radiation dosimetry calculated from a MAA SPECT/CT-based isodose map, we conclude that it is feasible and safe to perform SIRT in patients with portal hypertension associated with recanalised umbilical vein.

ACKNOWLEDGEMENTS

We would like to acknowledge the Electronic Presentation Online System, European Society of Radiology, for reuse of images published in European Congress of Radiology 2015 "Radiation dosimetry in selective internal radiation treatment in patients with portosystemic shunts to umbilical veins" for a subsequent journal submission.¹⁵

REFERENCES

- Gupta A, Levitin A, Shrikanthan S. Macroaggregated albumin injected in hepatic artery visualized in a recanalized paraumbilical vein. *Clin Nucl Med*. 2012;37:80-1. [crossref](#)
- Umemura T, Yamamura N, Nagata A, Shibata A, Yamashita K, Ohata T, et al. Case report: Steatonecrosis in the upper abdomen following transcatheter arterial embolization for hepatocellular carcinoma. *J Gastroenterol Hepatol*. 1998;13:471-4. [crossref](#)
- Lin CC, Wu DK, Shih PM, Liu GC, Chuang WL. Supra-umbilical skin rash and fat necrosis after transcatheter arterial chemoembolization: a case report. *Kaohsiung J Med Sci*. 2004;20:36-40. [crossref](#)
- Kim HY, Bae SH, Park CH, Song MJ, Choi JY, Yoon SK, et al. Supraumbilical subcutaneous fat necrosis after transcatheter arterial chemoembolization with drug-eluting beads: case report and review of the literature. *Cardiovasc Intervent Radiol*. 2013;36:276-9. [crossref](#)
- Kao YH, Tan AE, Khoo LS, Lo RH, Chow PK, Goh AS. Hepatic falciform ligament Tc-99m-macroaggregated albumin activity on SPECT/CT prior to Yttrium-90 microsphere radioembolization: prophylactic measures to prevent non-target microsphere localization via patent hepatic falciform arteries. *Ann Nucl Med*. 2011;25:365-9. [crossref](#)
- Ahmadzadehfar H, Biersack HJ, Ezziddin S. Radioembolization of liver tumors with yttrium-90 microspheres. *Semin Nucl Med*. 2012;40:105-21. [crossref](#)
- Ahmadzadehfar H, Möhlenbruch M, Sabet A, Meyer C, Muckle M, Haslerud T, et al. Is prophylactic embolization of the hepatic falciform artery needed before radioembolization in patients with 99mTc-MAA accumulation in the anterior abdominal wall? *Eur J Nucl Med Mol Imaging*. 2011;38:1477-84. [crossref](#)
- Bolch WE, Bouchet LG, Robertson JS, Wessels BW, Siegel JA, Howell RW, et al. MIRD pamphlet No. 17: the dosimetry of nonuniform activity distributions--radionuclide S values at the voxel level. Medical Internal Radiation Dose Committee. *J Nucl Med*. 1999;40:11S-36S.
- Ng SC, Lee VH, Law MW, Liu RK, Ma VW, Tso WK, et al. Patient dosimetry for 90Y selective internal radiation treatment based on 90Y PET imaging. *J Appl Clin Med Phys*. 2013;14:212-21.
- Hall EJ, Giaccia AJ. *Radiobiology for the radiologists*. 7th ed. Philadelphia, PA: Lippincott Williams & Wilkins; 2012.
- Gupta A, Gill A, Shrikanthan S, Srinivas S. Nontargeted Y-90 microsphere radioembolization to duodenum visualized on Y-90 PET/CT and Bremsstrahlung SPECT/CT. *Clin Nucl Med*. 2012;37:98-9. [crossref](#)
- Murthy R, Brown DB, Salem R, Meranze SG, Coldwell DM, Krishnan S, et al. Gastrointestinal complications associated with hepatic arterial Yttrium-90 microsphere therapy. *J Vasc Interv Radiol*. 2007;8:553-62. [crossref](#)
- Aagaard J, Jensen LI, Sørensen TI, Christensen U, Burcharth F. Recanalized umbilical vein in portal hypertension. *AJR Am J Roentgenol*. 1982;139:1107-10. [crossref](#)
- Ibukuro K, Tsukiyama T, Mori K, Inoue Y. Transhepatic portosystemic shunts: CT appearance and anatomic correlation. *AJR Am J Roentgenol*. 2000;175:153-7. [crossref](#)
- Ma WH, Ng S, Ho WY, Law MW, Lee HF, Wong KK, et al. Radiation dosimetry in selective internal radiation treatment (SIRT) in patients with portosystemic shunts to umbilical veins. Conference: European Congress of Radiology (ECR) 2015, Vienna, Austria. DOI: 10.1594/ecr2015/C-0053.