
ORIGINAL ARTICLE

Mid-term Results and Efficacy of Uterine Artery Embolisation for Symptomatic Fibroids in the Local Population

KYK Wong¹, VWT Chan¹, PCH Kwok¹, KY Leung²

Departments of ¹Radiology and Imaging, and ²Obstetrics and Gynaecology, Queen Elizabeth Hospital, Jordan, Hong Kong

ABSTRACT

Objective: To assess the efficacy and safety of uterine artery embolisation (UAE) for treatment of symptomatic fibroids in Hong Kong Chinese women.

Methods: A retrospective analysis of consecutive patients who underwent UAE between June 2005 and December 2013 in a regional hospital in Hong Kong was performed. All patients had a magnetic resonance imaging (MRI) before and after UAE. Uterine and fibroid volumes were calculated from MRI scans to assess radiological improvement. Symptoms including abnormal uterine bleeding, dysmenorrhoea, urinary frequency, and abdominal distension were recorded.

Results: A total of 61 patients were assessed. The technical success rate was 98% with only one failure. Therapeutic hysterectomy or myomectomy was performed in 13%. The mean uterine volume decreased from 897.5 ml to 608.4 ml (32.2% reduction). The mean volume of the largest fibroid decreased from 258.7 ml to 169.9 ml (34.3% reduction). Symptomatic improvement was achieved for abnormal uterine bleeding (85%), dysmenorrhoea (86%), and urinary frequency (82%). There was an improvement in mean haemoglobin level from 100 g/l to 119 g/l and also a decreased number of patients using transamin following UAE from 72% (44/61) to 44% (22/50). Minor complications including fever, urinary tract infection, vaginal discharge, and post-embolisation syndrome occurred in a minority of patients. Three women developed permanent amenorrhoea after UAE. Fibroid expulsion occurred in three patients within 3 months of UAE without the need for hospitalisation.

Conclusion: Local data support the application of UAE as a safe and effective treatment for women with symptomatic fibroids. A high clinical success rate and fibroid volume reduction can be achieved.

Key Words: Female; Leiomyoma; Uterine artery embolization; Uterine neoplasms/therapy

中文摘要

子宮動脈栓塞術對症狀性纖維子宮肌瘤的本地患者的中期結果和療效

黃汝麒、陳偉達、郭昶熹、梁國賢

目的：評估子宮動脈栓塞術（UAE）作治療症狀性纖維子宮肌瘤的香港華籍婦女的功效和安全性。

方法：回顧分析2005年6月至2013年12月期間香港一所分區醫院接受UAE治療的所有患者。她們均在治療前後進行了磁共振成像（MRI）。使用MRI掃描影像計算子宮和肌瘤體積以評估影像學改

Correspondence: Dr Kevin YK Wong, Department of Radiology and Imaging, Queen Elizabeth Hospital, 30 Gascoigne Road, Jordan, Kowloon, Hong Kong.
Email: kevirgwong@gmail.com

Submitted: 6 Feb 2015; Accepted: 30 Jul 2015.

Disclosure of Conflicts of Interest: All authors have disclosed no conflicts of interest.

善。徵狀紀錄包括異常子宮出血、痛經、尿頻和腹脹。

結果：61名患者進行了評估。技術操作成功率98%，僅一個失敗病例。患者中13%接受治療性子宮切除術或子宮肌瘤切除術。平均子宮體積由897.5 ml減至608.4 ml（減幅35.9%）。最大肌瘤的體積從258.7 ml減至169.9 ml（減幅48.9%）。患者症狀包括異常子宮出血（85%）、痛經（86%）和尿頻（82%）均有改善。UAE治療後，56%患者的血紅蛋白水平從100 g/l升至119 g/l。少數患者出現輕微併發症，包括發熱、尿道感染、陰道分泌物和栓塞後綜合徵。3名患者在接受UAE治療後出現永久性閉經。3名患者治療後有肌瘤組織排出，無需住院治療。

結論：本地數據顯示UAE是針對症狀性纖維瘤婦女的一個安全、有效的治療，不但成功率高，纖維瘤體積也縮小。

INTRODUCTION

Uterine fibroids are common in pre-menopausal women worldwide, with as many as 40% to 60% of women at the age of 35 years showing clinical and ultrasonographic evidence of uterine fibroids.¹ Symptoms include abnormal uterine bleeding (AUB), dysmenorrhoea, and urinary frequency.

Treatment of symptomatic fibroids includes medical, surgical, and uterine-conserving procedures. Before the advent of intravascular treatment, myomectomy or hysterectomy was the mainstay of treatment for these patients. Hysterectomy, however, necessitates major surgery and a prolonged convalescent period. Uterine artery embolisation (UAE) was first introduced in 1995 as a minimally invasive alternative treatment for uterine fibroids.² Studies have shown its efficacy in symptom control as well as fibroid devascularisation and infarction.³ As well as preserving the uterus, it is also associated with a shorter hospital stay⁴ and a short recovery period of 1 to 2 weeks.^{5,6} Previous studies in the Asian population have shown good clinical and radiological response to UAE.⁷ In spite of this, a Cochrane database review in 2012 showed that UAE was associated with higher rates of minor short-term and long-term complications, more unscheduled readmissions after discharge, and an increased surgical re-intervention rate compared with hysterectomy or myomectomy.⁸ This study reports the short- to mid-term (6 months to 3 years) clinical efficacy and safety of UAE in the local population with mid- to long-term clinical results.

METHODS

This was a retrospective study based on the review of electronic patient records and written follow-up records of all women who underwent UAE for symptomatic fibroids from June 2005 to December 2013 in a regional

hospital in Hong Kong. All patients were referred from our gynaecology unit. UAE was performed in symptomatic patients who required intervention but wished to preserve the uterus, had refused surgery, or expressed a personal preference for the procedure.

All reviewed patients had a pre-procedural magnetic resonance imaging (MRI) of the pelvis performed as part of their workup.

Seven principal interventional radiologists performed all of the procedures, of whom four had more than 15 years of experience, two had more than 10 years of experience, and one had 4 years of experience. All UAEs were performed with local anaesthesia and conscious sedation. Angiography (Siemens Artis Zee; Siemens AG, Forchheim, Germany) was performed via a right femoral artery approach. A 4-French (4-Fr) or 5-Fr Cobra-1 or Sidewinder-1 catheter was used to catheterise both internal iliac arteries. Both uterine arteries were identified and selectively catheterised. A 2.9-Fr microcatheter (Terumo, Japan) was used if there was difficulty in selective catheterisation. Blood supply to the uterus and fibroids was confirmed on angiography.

Trisacryl gelatin microspheres (Embosphere; Merit Medical, South Jordan [UT], USA) with a diameter of 500-700 μm , 700-900 μm , or in some cases up to 900-1200 μm were used for embolisation of the uterine arteries bilaterally, to cause pruning of the end arterioles. Choice of microsphere size was mainly based on operator preference depending on angiographic findings and flow rate. The mean (\pm standard deviation [SD]) volume of particles injected was 11.8 ± 5.2 ml. Post-embolisation arteriography was performed to ensure occlusion of the vessels.

A patient-controlled analgesia (PCA) pump of

intravenous morphine together with oral non-steroidal anti-inflammatory drugs were prescribed for the first 24 hours post-procedure. Ketorolac suppositories were administered once prior to embolisation and prescribed after the first 24 hours post-procedure. The gynaecology unit of our institution provided post-procedural monitoring during the in-patient period following UAE. Morphine dosage for peri-procedural pain and length of hospital stay (LOS) were recorded.

Baseline parameters including age at which UAE was performed, pre-procedural and post-procedural haemoglobin level, symptoms including AUB (previously termed menorrhagia), dysmenorrhoea, urinary symptoms, and mass symptoms, use of tranexamic acid or iron supplements, and history of operative procedures related to the uterine fibroids (hysterectomy, myomectomy, or hysteroscopic resection) were also recorded.

The mid-term clinical results of patients were assessed. AUB was assessed using haemoglobin level as a measure of its severity. Other more subjective symptoms including dysmenorrhoea were assessed in terms of worsened symptoms, static symptoms, or improved symptoms.

Radiological assessments with 1.5 T MR scanner (Siemens Avanto; Siemens AG, Forchheim, Germany) before and at least once following UAE were available for comparison in all patients. MRI sequences included axial T1 fast spin echo (FSE), axial and sagittal T2 FSE, as well as axial and coronal T1 FSE post-contrast scans. Characteristics including volume of dominant fibroid, location of dominant fibroid (subserosal, intramural, submucosal), size of uterus, and enhancement characteristics were recorded. After discharge, patients were followed up clinically as well as with pelvic MRI. Most reviewed cases had pre-procedural MRI and an MRI performed at 3 months following UAE. A minority underwent follow-up MRI as long as 22 months later. Uterine size and dominant fibroid volume were documented and calculated using a formula that assumed an ovoid configuration (length x depth x width x 0.523). Other parameters including change in enhancement or disappearance of the fibroid were recorded. Although transabdominal or transvaginal ultrasonography is available in our institution for follow-up of fibroid treatment, ultrasonography is more operator-dependent and results or measurements may not be readily reproducible.^{9,10} MRI has better reproducibility and the

added advantage of visualising all fibroids in terms of size, location, and enhancement pattern.

Statistical analyses were performed using the Statistical Package for the Social Sciences (Windows version 11.0; SPSS Inc, Chicago [IL], US). Student *t* test was used to compare the mean hospital stay for febrile and afebrile patients. Paired *t* test was used for comparison of pre-treatment and post-treatment haemoglobin levels, uterine volume, and size of dominant fibroid. Wilcoxon rank-sum test analysis was used to compare dysmenorrhoea severity at different time-points following UAE. Linear regression analysis was used to determine any correlation between change in fibroid size and haemoglobin improvement.

Ethics approval was granted by the Kowloon Central Cluster Ethics Research Committee with informed consent waived due to its retrospective nature.

RESULTS

A total of 63 consecutive UAEs in 61 women performed in our hospital were reviewed during the study period. Their mean (\pm SD) age was 43.5 ± 5.0 years at the time of UAE and all women were premenopausal. The mean time for post-UAE follow-up MRI was 4.3 ± 3.8 months. The majority of women had regular follow-up in the gynaecology unit for a mean of 34.7 ± 22.3 months post-UAE. Before the current UAE, 12 women had a documented history of previous surgical myomectomy and two had undergone previous UAE. Overall, 25 (41.0%) women had one or more pregnancies prior to UAE; three (4.9%) women had a history of miscarriage while 10 (16.4%) had a history of one or more termination of pregnancy. No pregnancies were recorded following UAE.

The majority of the dominant fibroids were located in an intramural location (88.5%); the remainder were submucosal (11.5%). None of the dominant fibroids were subserosal in location.

Prior to UAE treatment, the mean uterine volume as measured on MRI was 897.5 ml and the mean dominant fibroid volume was 258.7 ml. All women had multiple fibroids and co-existing adenomyosis was identified in two women on pre-treatment MRI. In one of them, adenomyosis was known and UAE was performed after she received an adequate explanation of the increased risk of treatment failure. In the second patient, adenomyosis was not detected previously.

Technical Success

Bilateral uterine arterial catheterisation and embolisation was successfully performed in 95.1% (58/61) of patients in one session (Figure 1). In one patient, catheterisation of the left uterine artery was unsuccessful although a second attempt was successful 2 months later. In another patient, mild right uterine artery contrast extravasation was detected and the procedure was abandoned after successful UAE of the left uterine artery. The patient was kept under close observation and supportive treatment. A second UAE for the right uterine artery was successful 1 month later. In the last patient, both uterine arteries failed to be catheterised due to difficult anatomy despite the use of a microcatheter (2.9-Fr Progreat microcatheter; Terumo, Japan) [Figure 2]. For this particular patient, total abdominal hysterectomy will be performed at a future date.

Periprocedural Symptoms and Complications

The mean duration of hospital stay after UAE was 2.7 ± 1.4 days. Patients with fever stayed longer in hospital than afebrile patients for treatment (mean LOS, 3.5 days vs. 2.5 days; $p < 0.05$).

Post-procedural pain occurred in all of our patients following successful UAE and all women were prescribed PCA according to our local post-embolisation

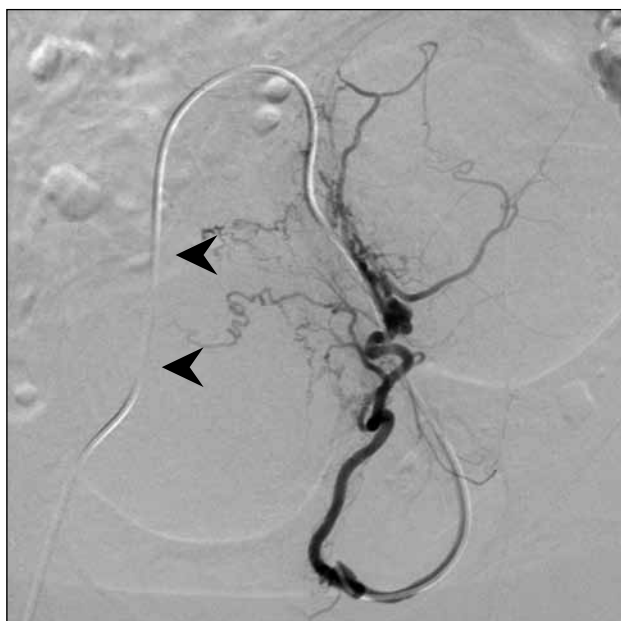

Figure 1. Angiogram of the left uterine artery. Successful cannulation of left uterine artery demonstrating arterial feeders to the fibroid (arrowheads). Subsequent embolisation with microsphere (500-700 μ m) was successful in this patient.

protocol. PCA was available immediately after the patients were transferred back to the gynaecology unit. The mean dose of morphine used from the PCA machine was 30.7 ± 31.4 mg.

An acute complication occurred in one patient which involved mild contrast extravasation that occurred during right uterine artery catheterisation. The procedure was abandoned and subsequent UAE for the right uterine

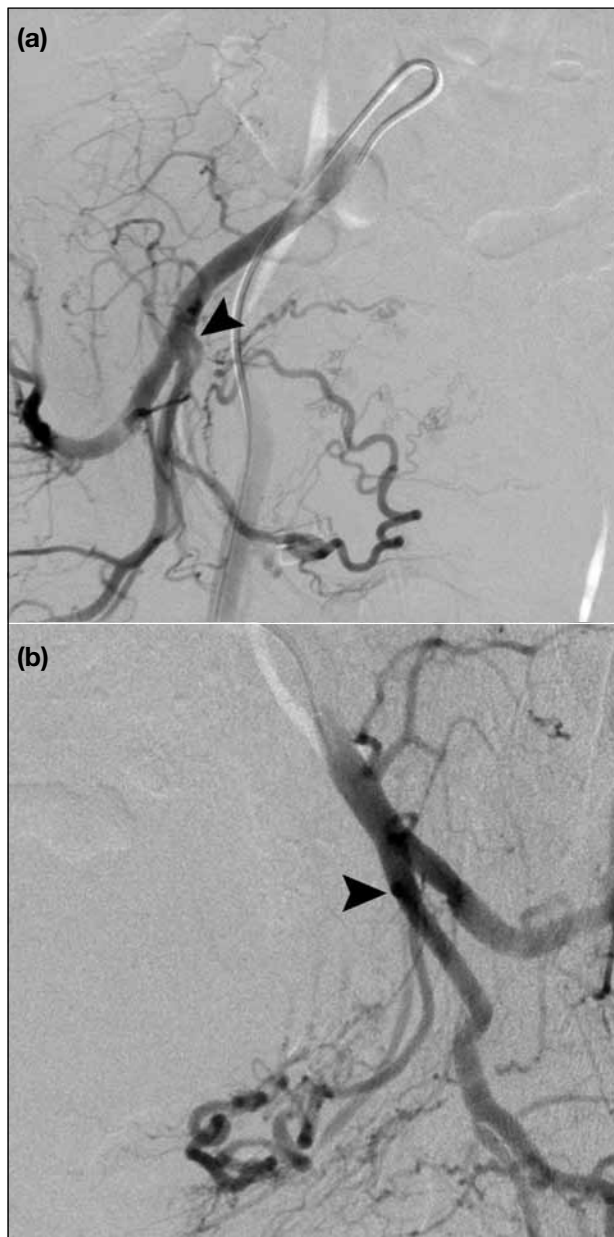

Figure 2. Angiograms of the (a) right and (b) left internal iliac arteries of a patient who failed uterine artery cannulation. (a) The right uterine artery branches off at a right angle to the internal iliac artery (arrowhead); (b) the left uterine artery has a posteriorly angled branched off (arrowhead). Cannulation of both uterine arteries failed.

artery was performed successfully 1 month later.

The most common complication was low-grade fever (23.0%) [Table 1]. One patient had a positive bacterial culture in urine and another patient had vaginal discharge; they were treated according to culture sensitivity results. Fever in the remaining patients resolved with empirical oral antibiotic administration (n = 5) and was self-limiting (n = 7).

In three (4.9%) of 61 patients, the fibroid was expelled following UAE. Two of these women had a dominant fibroid located in a submucosal location and expulsion occurred within 1 month of UAE. The third woman had an intramural fibroid and expulsion occurred 3 months after UAE. Two of the women were admitted as unscheduled admissions for fibroid expulsion-related symptoms. No further surgical treatment, including hysteroscopy, was performed after expulsion, and treatment comprised mainly analgesia. Subsequent MRI confirmed the disappearance of the fibroid and the women noted a significant improvement in their symptoms (Figure 3).

Ten women had unscheduled admissions following UAE: two related to fibroid expulsion as mentioned above, three related to possible pelvic inflammatory disease that was treated medically, four for anaemic symptoms or AUB, and one due to post-embolisation syndrome (Table 1).

Four patients reached permanent menopause after UAE, of whom three became menopausal at 0, 4, and 12 months after UAE and were aged 51, 50, and 51 years, respectively at the time of procedure. These women had raised follicle-stimulating hormone (FSH) confirmed. One other patient, aged 43 years, who became amenorrhoea immediately after UAE had a transiently raised FSH that decreased to normal on subsequent follow-up. The transient rise was attributed to blood testing during the follicular phase.

Table 1. Complication rates in patients undergoing uterine artery embolisation.

Complication	No. (%) of patients
Low-grade fever	14 (23.0)
Fibroid expulsion	3 (4.9)
Pelvic inflammatory disease	3 (4.9)
Anaemic symptoms	4 (6.6)
Post-embolisation syndrome	1 (1.6)
Unscheduled admissions	10 (16.4)

Clinical Improvement

A total of 51 (83.6%) patients had records for follow-up subsequent to UAE and 10 were lost to follow-up. Pre-treatment symptoms were not recorded in two of the 61 patients. In the remaining 59 women, common presenting symptoms included AUB in 49 (83.1%), dysmenorrhoea in 25 (42.4%), urinary frequency in 15 (25.4%), and pressure symptoms in 15 (25.4%).

Data on symptomatic improvement were recorded from patient records but was unclear in some cases. After excluding those with hysterectomies and unclear symptom presentations, of the remaining 41 women who had AUB, 35 (85%) reported improvement in symptoms. Similarly, for the 21 women with dysmenorrhoea, 18 (86%) reported decreased dysmenorrhoea. Urinary symptom and pressure symptoms decreased in 82% and 62% of patients, respectively (Table 2).

Anaemia also improved following UAE. The mean haemoglobin level increased from 100 g/l to 119 g/l ($p < 0.001$). Prior to UAE, 44 (72%) of 61 patients were taking tranexamic acid for symptom control. After UAE, only 22 (44%) of 50 patients still required tranexamic acid.

Mid-term Clinical Improvement

AUB is associated with a decreased haemoglobin level. We recorded haemoglobin level at the time of UAE, and 3, 12, 24, and 36 months after treatment. The mean haemoglobin level was 110 g/l at the time of UAE to 121 g/l at 36 months after UAE. This improvement was statistically significant compared to the baseline measurement (Table 3).

Dysmenorrhoea severity was recorded from data in the electronic patient record at baseline, and 3, 12, 24, and 36 months after UAE. Severity was ranked as improved, unchanged, or worsened. A significant improvement from baseline in dysmenorrhoea severity was evident at 3 months (Wilcoxon rank-sum test, $Z = -3.317$, $p = 0.001$). Comparison of dysmenorrhoea severity in subsequent months showed no further significant difference. This shows that UAE causes rapid improvement in dysmenorrhoea at 3 months that is sustained for up to 36 months after the procedure.

Radiological Improvement

All patients had MRI performed within 1 year of UAE and after a mean of 4.3 months. On MRI, there was

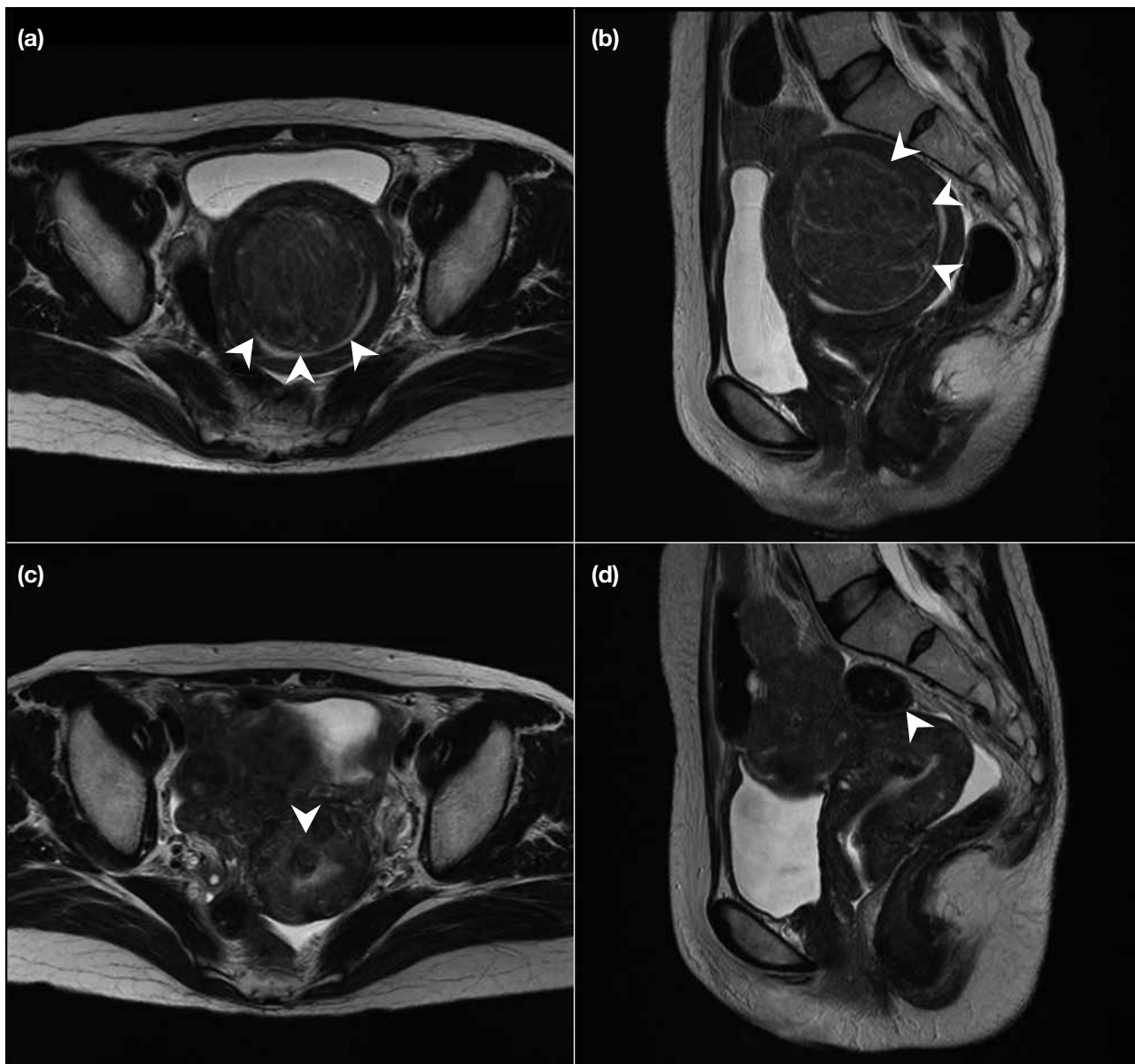


Figure 3. (a) Axial and (b) coronal T2-weighted magnetic resonance (MR) images showing a large T2 hypointense submucosal fibroid with distension of the endometrial cavity (arrowheads). (c) Axial and (d) coronal T2-weighted MR images 1 month after UAE. This patient experiences fibroid expulsion. Previous fibroid has almost completely disappeared with only small residual T2 hypointense stalk left (arrowheads). Endometrial cavity distension has markedly improved.

a significant decrease in uterine and fibroid size. The volume of the dominant fibroid decreased from a mean of 258.7 ml to 169.9 ml (34.3% decrease; $p < 0.001$). The reduction in mean uterine volume mirrored these values, showing a decrease from 897.5 ml to 608.4 ml (32.2% decrease; $p < 0.001$) [Figure 4].

Hysterectomy was performed in eight (13%) patients after UAE, but none were due to complications. These occurred at a median of 33 months after UAE (range, 7-58 months). In four patients, the indication was

persistent or worsened symptoms. In the remaining patients, the reason was increased size of fibroid, which

Table 2. Overall changes in patient symptoms.

Symptom	No. (%) of patients		
	Improved	Unchanged	Worsened
Abnormal uterine bleeding (n = 41)	35 (85)	5 (12)	1 (2)
Dysmenorrhoea (n = 21)	18 (86)	2 (10)	1 (5)
Urinary frequency (n = 11)	9 (82)	2 (18)	0 (0)
Pressure symptoms (n = 13)	8 (62)	5 (38)	0 (0)

Table 3. Mid-term changes in haemoglobin level.

Complication	Mean haemoglobin level (g/l)	p Value (as compared to baseline)
At UAE	110	-
Time after UAE		
3 months	115	< 0.05
12 months	118	< 0.05
24 months	121	< 0.05
36 months	121	< 0.05

Abbreviation: UAE = uterine artery embolisation.

was evident on later ultrasound scans. Adenomyosis and adenomyoma were found in two of the patients who subsequently underwent hysterectomy. Leiomyoma were found in all patients. No malignant pathology was detected.

Correlation of Radiological Improvement with Clinical Improvement

We investigated the relationship between the degree of fibroid shrinkage at first MRI follow-up and improvement in haemoglobin level at 12 months after

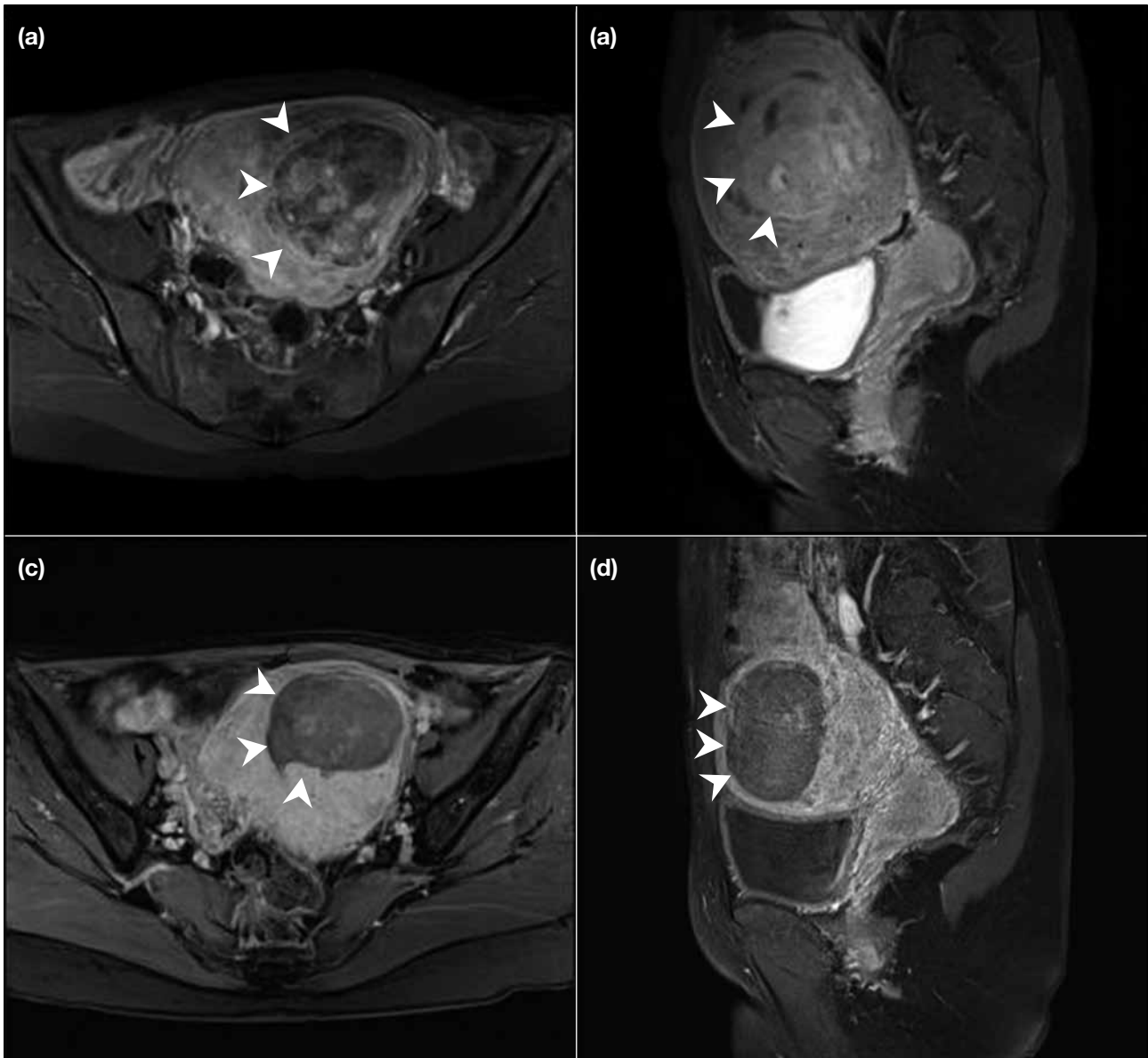


Figure 4. (a) Axial and (b) coronal T1-weighted contrast-enhanced magnetic resonance (MR) images showing a large fibroid on the left side of the uterus with internal enhancement. The uterus is also distended. Mass effect is also seen on the adjacent urinary bladder (arrowheads). (c) Axial and (d) coronal T1-weighted contrast-enhanced MR images 6 months after uterine artery embolisation showing decrease in size of the fibroid with decreased enhancement suggesting devascularisation (arrowheads). Uterine distension and mass effect on urinary bladder have also decreased.

UAE and found a weak but significant correlation between the two (linear regression, $R=0.427$, $p < 0.05$) [Figure 5].

DISCUSSION

Our overall success rate for UAE was very good. Technical success rate for bilateral embolisation in the first UAE was 96% and >98% if the second UAE was included. Only one patient failed to have both uterine arteries cannulated. This high technical success rate is similar to other published studies.^{4,6,11}

Many different embolic agents are available for UAE including Bead Block (Biocompatibles; Terumo, Japan), Embosphere (Merit Medical Inc), and polyvinyl alcohol (PVA) particles (Contour SE; Boston Scientific, Natick [MA], USA). A previous study showed superiority of Bead Block and PVA particles in individual patients with regard to decreased fibroid enhancement.¹² Recent meta-analysis including randomised and non-randomised trials of embolic agents in UAE showed no significant difference between different agents but a trend favouring the use of Embosphere for uterine and fibroid volume reduction. It also demonstrated a significant advantage of Embosphere over PVA particles in fibroid devascularisation.¹³ Although large randomised controlled trials (RCTs) are lacking, the result provides more evidence to support the use of certain embolic agents such as Embosphere over simple operator preference.

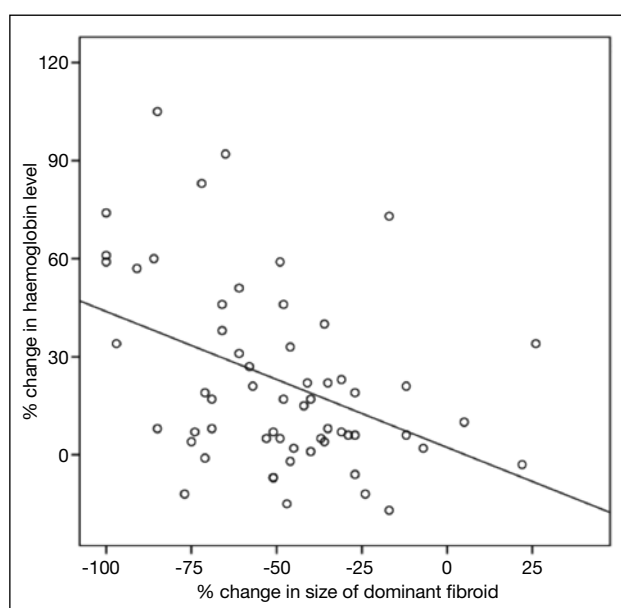


Figure 5. Correlation of change in dominant fibroid size with change in haemoglobin level.

The main objective of uterine fibroid embolisation is symptom improvement. Our data show that clinical improvement was significant in the majority of women. Symptoms including AUB, dysmenorrhoea, urinary frequency, and pressure symptoms were responsive to UAE in more than 80% of patients. The response rate of these symptoms is similar to previous local and international published data on UAE.¹⁴⁻¹⁹ Furthermore, there was significant radiological improvement in both uterine and dominant fibroid volume in our study population. We found a 48.9% decrease in dominant fibroid size as measured by MRI after UAE. This is similar to the results of a Cochrane review and other studies that reported a 30% to 46% decrease in dominant fibroid size.^{20,21}

In our mid-term clinical results, we were able to achieve a significant improvement in haemoglobin level 3 months after UAE, a level that showed continuous improvement of up to 36 months. These results are in line with the high rates of improvement in AUB over the short term as well as relatively low treatment failure rates in our study population. Dysmenorrhoea symptoms showed rapid improvement at 3 months after UAE and were sustained up to 36 months after treatment. These data suggest that treatment effect is sustainable in the short to mid term. The change in haemoglobin level and dysmenorrhoea may not be directly related but can be indirectly related to trough fibroid size. Nonetheless, other factors can also affect haemoglobin level or dysmenorrhoea including intake of iron and use of over-the-counter medication. These may help explain the difference in trend of haemoglobin change (continuous improvement) and dysmenorrhoea (plateau after 3 months). Further research may be needed to better understand the effects of these factors.

Several studies have previously investigated change in MR appearance of fibroids after UAE.^{22,23} In these studies, there was a significant reduction in fibroid size in a majority of patients. The degree of fibroid shrinkage was also shown to be weakly correlated with 12-month clinical response as measured by improvement in haemoglobin level.

Aside from volume reduction, other MR parameters have been investigated to predict clinical outcome including percentage of fibroid infarction. Comparison of the percentage enhancement change in pre- and post-UAE MRI can indicate degree of fibroid infarction. One such study demonstrated significant improvement in clinical

outcome and less need for re-intervention for patients with 90% or more infarction on post-UAE imaging.²⁴

Rates of hysterectomy due to treatment failure were similar to other large RCTs. We found a hysterectomy rate of 13% while other large RCTs have shown a rate of 20%.⁴ None of these were related to acute complications such as infection for which the reported rate can be up to 2%.^{16,25,26}

Expulsion of necrotic fibroid is an uncommon complication of UAE and occurs in up to 3% to 5% of such patients.²⁷⁻²⁹ It occurred in three women in our study population and was confirmed on MRI by disappearance of the original fibroid mass. In these three patients, it was associated with significant improvement in symptoms; their times to expulsion were 4 to 8 weeks, which are much shorter than 14 weeks in a previous study by Shlansky-Goldberg et al.³⁰

Patients can experience transient amenorrhoea for 1 to 2 months after UAE. Permanent amenorrhoea occurs in <5% of patients, however.^{16,18,31} Chrisman et al³² showed that up to 43% of women >45 years of age could become menopausal following UAE. In our study population, three of the women who developed amenorrhoea were >45 years old. The prevailing explanation for ovarian failure is the passage of small amounts of embolic particles into the ovarian vessels through uterine-ovarian vascular anastomosis causing ovarian failure.³³ Histopathological studies of patients who experience ovarian failure after UAE have shown particles in the specimen.³⁴ No definite particles were demonstrated to have entered ovarian circulation in our patients and no abnormal contrast enhancement of the ovaries was demonstrated during embolisation.

Other rare but serious complications including pulmonary embolism³⁵ did not occur in our study population.

UAE has been associated with a shorter hospital stay when compared with conventional surgical treatment in many series. Reported LOS ranges from 1 to 4 nights in different studies.^{4,36-38} The mean LOS for our patients was 2.7 days. Patients with LOS of more than 4 days experienced complications that included self-limiting pyrexia or infection such as urinary tract infection or pelvic inflammatory disease. Those with documented infections were treated with oral antibiotics and discharged without complications.

Overall, UAE has its own benefits and risks. The rates of treatment satisfaction are similar to other available treatments (surgery or medical treatment). UAE is associated with shorter LOS, faster recovery, and decreased need for blood transfusion. It is also associated with a higher rate of post-procedural complications and re-intervention, however.³⁹

As this is a retrospective analysis, one limitation was that some patients were lost to follow-up, of whom 9% (6/61) sought further follow-up in the private sector. One patient was not a Hong Kong resident and likely returned to her home country for further medical advice. Also, logistic regression analysis to study the relationship between UAE, fibroid symptom improvement, and MRI findings was not feasible due to incomplete data. Furthermore, we recognise that the clinical outcome measures were only semi-objective as no formal questionnaire was given for follow-up. We hope to perform prospective studies of local UAE results to enable more accurate measurement of clinical improvement. To date, no questionnaire about uterine fibroid symptoms has been validated for use in the Chinese population. This needs to be addressed. An example is the UFS-QOL-Hysterectomy that has been validated for use in uterine fibroid embolisation.⁴⁰

CONCLUSION

We have shown that UAE for treatment of symptomatic fibroids is safe and efficacious with good and sustained mid-term results. It is associated with a high technical success rate and offers significant symptomatic relief as well as reduction in fibroid size. The degree of radiological shrinkage in the dominant fibroid shows a positive correlation with improvement in anaemia. Long-term evaluation and follow-up to look for subsequent recurrence and sustained symptomatic control are needed to confirm the sustainability of these results.

REFERENCES

1. Khan AT, Shehmar M, Gupta JK. Uterine fibroids: current perspectives. *Int J Womens Health*. 2014;6:95-114. [crossref](#)
2. Ravina JH, Herbreteau D, Ciraru-Vigneron N, Bouret JM, Houdart E, Aymard A, et al. Arterial embolisation to treat uterine myomata. *Lancet*. 1995;346:671-2. [crossref](#)
3. Bradley LD. Uterine fibroid embolization: a viable alternative to hysterectomy. *Am J Obstet Gynecol*. 2009;201:127-35. [crossref](#)
4. Edwards RD, Moss JG, Lumsden MA, Wu O, Murray LS, Twaddle S, et al. Uterine-artery embolization versus surgery for symptomatic uterine fibroids. *N Engl J Med*. 2007;356:360-70. [crossref](#)
5. Walker WJ, Pelage JP. Uterine artery embolisation for symptomatic fibroids: clinical results in 400 women with imaging follow up. *BJOG*. 2002;109:1262-72. [crossref](#)
6. Spies JB, Ascher SA, Roth AR, Kim J, Levy EB, Gomez-Jorge

- J. Uterine artery embolization for leiomyomata. *Obstet Gynecol.* 2001;98:29-34. [cross ref](#)
7. Mak HL, Kwok PC, Chau HH, Chan MK, Chan SC, Chan SC. Uterine fibroid embolisation in Chinese women: medium-term results. *Hong Kong Med J.* 2006;12:361-7.
 8. Gupta JK, Sinha A, Lumsden MA, Hickey M. Uterine artery embolization for symptomatic uterine fibroids. *Cochrane Database Syst Rev.* 2012;(5):CD005073. [cross ref](#)
 9. Volkens NA, Hehenkamp WJ, Spijkerboer AM, Moolhuijzen AD, Birnie E, Ankum WM, et al. MR reproducibility in the assessment of uterine fibroids for patients scheduled for uterine artery embolization. *Cardiovasc Intervent Radiol.* 2008;31:260-8. [cross ref](#)
 10. Dueholm M, Lundorf E, Sørensen JS, Ledertoug S, Olesen F, Laursen H. Reproducibility of evaluation of the uterus by transvaginal sonography, hysterosonographic examination, hysteroscopy and magnetic resonance imaging. *Hum Reprod.* 2002;17:195-200. [cross ref](#)
 11. Siskin GP, Stainken BF, Dowling K, Meo P, Ahn J, Dolen EG. Outpatient uterine artery embolization for symptomatic uterine fibroids: experience in 49 patients. *J Vasc Interv Radiol.* 2000;11:305-11. [cross ref](#)
 12. Abramowitz SD, Israel GM, McCarthy SM, Pollak JS, White RI Jr, Tal MG. Comparison of four embolic materials at uterine artery embolization by using postprocedural MR imaging enhancement. *Radiology.* 2009;250:482-7. [cross ref](#)
 13. Das R, Champaneria R, Daniels JP, Belli AM. Comparison of embolic agents used in uterine artery embolisation: a systematic review and meta-analysis. *Cardiovasc Intervent Radiol.* 2014;37:1179-90. [cross ref](#)
 14. Bradley EA, Reidy JF, Forman RG, Jarosz J, Braude PR. Transcatheter uterine artery embolisation to treat large uterine fibroids. *Br J Obstet Gynaecol.* 1998;105:235-40. [cross ref](#)
 15. Worthington-Kirsch RL, Popky GL, Hutchins FL Jr. Uterine arterial embolization for the management of leiomyomas: quality-of-life assessment and clinical response. *Radiology.* 1998;208:625-9. [cross ref](#)
 16. Goodwin SC, McLucas B, Lee M, Chen G, Perrella R, Vedantham S, et al. Uterine artery embolization for the treatment of uterine leiomyomata midterm results. *J Vasc Interv Radiol.* 1999;10:1159-65. [cross ref](#)
 17. Walker W, Green A, Sutton C. Bilateral uterine artery embolisation for myomata: Results, complications and failures. *Minim Invasive Ther Allied Technol.* 1999;8:449-54. [cross ref](#)
 18. Pelage JP, Le Dref O, Soyer P, Kardache M, Dahan H, Abitbol M, et al. Fibroid-related menorrhagia: treatment with superselective embolization of the uterine arteries and midterm follow-up. *Radiology.* 2000;215:428-31. [cross ref](#)
 19. Brunereau L, Herbreteau D, Gallas S, Cottier JP, Lebrun JL, Tranquart F, et al. Uterine artery embolization in the primary treatment of uterine leiomyomas: technical features and prospective follow-up with clinical and sonographic examinations in 58 patients. *AJR Am J Roentgenol.* 2000;175:1267-72. [cross ref](#)
 20. Gupta JK, Sinha AS, Lumsden MA, Hickey M. Uterine artery embolization for symptomatic uterine fibroids. *Cochrane Database Syst Rev.* 2006;(1):CD005073. [cross ref](#)
 21. Zlotnik E, de Lorenzo Messina M, Nasser F, Affonso BB, Baroni RH, Wolosker N, et al. Predictive factors for pelvic magnetic resonance in response to arterial embolization of a uterine leiomyoma. *Clinics (Sao Paulo).* 2014;69:185-9. [cross ref](#)
 22. deSouza NM, Williams AD. Uterine arterial embolization for leiomyomas: perfusion and volume changes at MR imaging and relation to clinical outcome. *Radiology.* 2002;222:367-74. [cross ref](#)
 23. Katsumori T, Nakajima K, Tokuhira M. Gadolinium-enhanced MR imaging in the evaluation of uterine fibroids treated with uterine artery embolization. *AJR Am J Roentgenol.* 2001;177:303-7. [cross ref](#)
 24. Kroencke TJ, Scheurig C, Poellinger A, Gronewold M, Hamm B. Uterine artery embolization for leiomyomas: percentage of infarction predicts clinical outcome. *Radiology.* 2010;255:834-41. [cross ref](#)
 25. Hutchins FL Jr, Worthington-Kirsch R, Berkowitz RP. Selective uterine artery embolization as primary treatment for symptomatic leiomyomata uteri. *J Am Assoc Gynecol Laparosc.* 1999;6:279-84. [cross ref](#)
 26. Pron G, Bennett J, Common A, Wall J, Asch M, Sniderman K; Ontario Uterine Fibroid Embolization Collaboration Group. The Ontario Uterine Fibroid Embolization Trial. Part 2. Uterine fibroid reduction and symptom relief after uterine artery embolization for fibroids. *Fertil Steril.* 2003;79:120-7. [cross ref](#)
 27. Radeleff B, Eiers M, Bellemann N, Ramsauer S, Rimbach S, Kauczor HU, et al. Expulsion of dominant submucosal fibroids after uterine artery embolization. *Eur J Radiol.* 2010;75:e57-63. [cross ref](#)
 28. Pelage JP, Le Dref O, Jacob D, Soyer P, Herbreteau D, Rymer R. Selective arterial embolization of the uterine arteries in the management of intractable post-partum hemorrhage. *Acta Obstet Gynecol Scand.* 1999;78:698-703. [cross ref](#)
 29. Andersen PE, Lund N, Justesen P, Munk T, Elle B, Floridon C. Uterine artery embolization of symptomatic uterine fibroids . Initial success and short-term results. *Acta Radiol.* 2001;42:234-8. [cross ref](#)
 30. Shlansky-Goldberg RD, Coryell L, Stavropoulos SW, Trerotola SO, Mondschein J, Beshara M, et al. Outcomes following fibroid expulsion after uterine artery embolization. *J Vasc Interv Radiol.* 2011;22:1586-93. [cross ref](#)
 31. Spies JB, Scialli AR, Jha RC, Imaoka I, Ascher SM, Fraga VM, et al. Initial results from uterine fibroid embolization for symptomatic leiomyomata. *J Vasc Interv Radiol.* 1999;10:1149-57. [cross ref](#)
 32. Chrisman HB, Saker MB, Ryu RK, Nemcek AA Jr, Gerbie MV, Milad MP, Smith SJ, et al. The impact of uterine fibroid embolization on resumption of menses and ovarian function. *J Vasc Interv Radiol.* 2000;11:699-703. [cross ref](#)
 33. Tulandi T, Sammour A, Valenti D, Stein L. Images in endoscopy: uterine artery embolization and utero-ovarian collateral. *J Am Assoc Gynecol Laparosc.* 2001;8:474. [cross ref](#)
 34. Payne JF, Robboy SJ, Haney AF. Embolic microspheres within ovarian arterial vasculature after uterine artery embolization. *Obstet Gynecol.* 2002;100:883-6. [cross ref](#)
 35. Czeyda-Pommersheim F, Magee ST, Cooper C, Hahn WY, Spies JB. Venous thromboembolism after uterine fibroid embolization. *Cardiovasc Intervent Radiol.* 2006;29:1136-40. [cross ref](#)
 36. Pinto I, Chimeno P, Romo A, Paul L, Haya J, de la Cal MA, et al. Uterine fibroids: uterine artery embolization versus abdominal hysterectomy for treatment — a prospective, randomized, and controlled clinical trial. *Radiology.* 2003;226:425-31. [cross ref](#)
 37. Pron G, Mocarski E, Bennett J, Vilos G, Common A, Zaidi M, et al. Tolerance, hospital stay, and recovery after uterine artery embolization for fibroids: the Ontario Uterine Fibroid Embolization Trial. *J Vasc Interv Radiol.* 2003;14:1243-50. [cross ref](#)
 38. Jun F, Yamin L, Xinli X, Zhe L, Min Z, Bo Z, et al. Uterine artery embolization versus surgery for symptomatic uterine fibroids: a randomized controlled trial and a meta-analysis of the literature. *Arch Gynecol Obstet.* 2012;285:1407-13. [cross ref](#)
 39. Khan AT, Shehmar M, Gupta JK. Uterine fibroids: current perspectives. *Int J Womens Health.* 2014;6:95-114. [cross ref](#)
 40. Coyne KS, Margolis MK, Murphy J, Spies J. Validation of the UFS-QOL-hysterectomy questionnaire: modifying an existing measure for comparative effectiveness research. *Value Health.* 2012;15:674-9. [cross ref](#)