

---

---

## ORIGINAL ARTICLE

---

---

# Stereotactic-guided Vacuum-assisted Breast Biopsy in the Asian Population: What Factors Affect Marker Migration?

VYK To, KM Wong, WS Mak, KM Kwok, CW Wong

Department of Diagnostic and Interventional Radiology, Kwong Wah Hospital, Yaumatei, Hong Kong

### ABSTRACT

**Objective:** Stereotactic-guided vacuum-assisted biopsy (VAB) can be performed in small breast masses, distortions, and microcalcifications. A metallic marker is deployed at the corresponding biopsy site to facilitate localisation if additional surgery is required. There is currently limited literature on the accuracy of marker placement in Asian breasts that tend to be smaller and denser than those in Caucasians. The objective of this study was to evaluate the factors that may affect marker migration in stereotactic VAB at a regional hospital in Hong Kong.

**Methods:** From January 2010 to June 2015, all stereotactic VAB performed in the screening population at Kwong Wah Hospital were reviewed through the Hologic Selenia workstations and electronic patient records. Consensus between the local breast surgeons and radiologists defined marker migration of <1 cm as insignificant displacement. Marker migration of >1 cm could affect surgical localisation. Factors including age, indication, Breast Imaging–Reporting and Data System (BIRADS) category, needle approach, breast density, breast compression thickness, depth of the lesion, number of biopsy cuttings, complications, and duration of the procedure were recorded. The distance of marker migration from the biopsy site in cranio-caudal and medial-lateral oblique views was measured.

**Results:** A total of 154 Asian patients underwent stereotactic VAB during the study period. One patient was excluded due to technical failure during deployment of the marker. Of the remaining 153 patients, there was migration of 45 (29.4%) markers, of which 19 (12.4%) were <1 cm, 16 (10.5%) 1-3 cm, 7 (4.6%) 3-5 cm, and 3 (2.0%) >5 cm. Factors including older age, thicker breasts, greater number of biopsy cuttings, and longer duration of the procedure showed statistical significance in affecting marker migration ( $p < 0.05$ ).

**Conclusion:** This study identified four factors that could influence marker migration, namely age, breast compression thickness, number of biopsy cuttings, and duration of procedure. Awareness of these factors during the planning of the procedure could potentially decrease the effect of marker migration and thus enable more accurate surgical localisation.

**Key Words:** Biopsy; Breast neoplasms; Foreign-body migration; Mammography; Stereotaxic techniques

---

---

**Correspondence:** Dr Victoria YK To, Department of Diagnostic and Interventional Radiology, Kwong Wah Hospital, Yaumatei, Hong Kong.

Email: vykto911@gmail.com

Submitted: 29 Dec 2015; Accepted: 22 Apr 2016.

Disclosure of Conflicts of Interest: All authors have no relevant conflicts of interest to disclose.

## 中文摘要

### 亞洲人口的立體定向引導真空輔助乳腺活檢：哪些因素影響標記遷移位？

杜婉筠、黃嘉敏、麥詠詩、郭勁明、黃鎮威

**目的：**立體定向引導真空輔助活檢（VAB）可以用於治療小乳房腫塊、變畸形和微鈣化的情況下進行。如還需進行額外手術，會在相應的活檢部位部署植入金屬標記以便定位。亞洲婦女的乳房一般比外國人小，乳房組織的密度也較高，放置關於標記物的植入準確性的現存文獻較少。所以本研究的目的是評估香港一所分區醫院內立體定向VAB中可能影響標記遷移位的因素。

**方法：**通過Hologic Selenia工作站和病人電子病歷回顧研究2010年1月至2015年6月期間在廣華醫院接受立體定向VAB的患者。乳房外科醫生和放射科醫生一致認為將少於1 cm的標記移位定為非顯著位移。標記移位多於1 cm則可能影響手術定位。記錄影響因素包括年齡、適應症、乳房成像報告和數據系統（BIRAD）分級、針法、乳房密度、乳房壓縮厚度、病變深度、活檢切口數、併發症和操作持續時間。記錄標記位於頭尾位和內外斜位。

**結果：**研究期間共有154名亞洲患者接受立體定向VAB。其中1例因標記植入過程中出現故障而被排除出本研究。餘下153例中，45例（29.4%）出現標記物移位，當中19例（12.4%）移位少於1 cm，16例（10.5%）移位1-3 cm，7例（4.6%）移位3-5 cm，3例（2.0%）移位大於5 cm。年齡較大、乳房較厚、活檢切口數量較多和操作時間較長與標記物移位有統計學顯著的相關性（ $p < 0.05$ ）。

**結論：**這項研究確定了可能影響標記遷移的四項因素，即年齡、乳房壓縮厚度、活檢切割的數量和操作的持續時間。如在規劃操作過程中意識到這些因素則可能減少標記物遷移的影響，從而能夠進行更精確的定位。

## INTRODUCTION

Different techniques can be used to perform breast biopsy. Radiologically guided methods include stereotactic, ultrasound, or magnetic resonance imaging guidance and these in turn include core needle biopsy and vacuum-assisted biopsy (VAB). Both core needle biopsy and VAB are minimally invasive outpatient day procedures that can be performed on breast masses, distortions, and grouped microcalcifications. The VAB needle is usually larger, 7 Gauge (G), 10G, or 11G compared with that used for core needle biopsy, usually 14G. VAB requires more local anaesthetic and the incision is slightly larger than that in core needle biopsy. Both procedures require the patient to lie still in the prone position for the entire process. Core needle biopsy requires several insertions through the same incision whereas VAB can obtain a larger sample volume by vacuum assistance through a single insertion. The increase in the sample volume enables a more accurate histological diagnosis and decreases the re-biopsy rate.

Furthermore, VAB can potentially completely remove the suspicious radiological abnormality.<sup>1-4</sup>

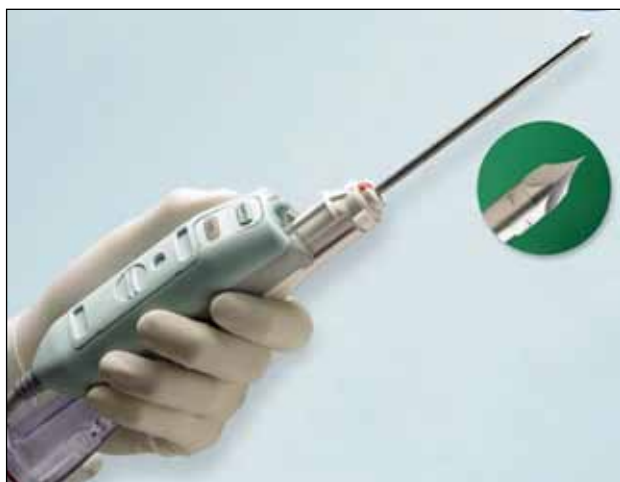At the end of the procedure, a marker made of stainless steel surrounded by air-impregnated pellets can be deployed at the corresponding biopsy site to facilitate target localisation if additional surgery is required. The stainless steel marker permits long-term visualisation in mammography and causes no pain or harm. The surrounding air-impregnated pellets cause acoustic shadowing that can be identified under ultrasound for several weeks before they are being absorbed by the body. There have been reports of marker migration in the western population.<sup>4-8</sup>

There is currently limited literature on the accuracy of marker placement in Asian breasts that tend to be smaller and more dense. The objective of this study was to evaluate the factors that could affect marker migration in stereotactic VAB at a local regional hospital.

## METHODS

At Kwong Wah Hospital, stereotactic VAB is performed as an outpatient day procedure. Patients suitable for stereotactic VAB were carefully selected following consultation by a multidisciplinary panel comprising breast radiologists and breast surgeons. The procedure was performed by breast radiologists with 3 months to 15 years of experience. On the day of the procedure, the radiologist explained to the patient how the procedure would be conducted and the potential risks. Any allergy to local anaesthetic or intake of anticoagulants was double-checked.

The patients in this study had VAB performed in the prone position on the prone biopsy table (MultiCare Platinum prone table). The direction of percutaneous needle entry was selected and the lesion coordinates (x, y, and z) identified. After disinfection of the breast, lignocaine was injected. An incision was made and the 10G biopsy needle (EnCor; Breast Biopsy System; Bard Biopsy Systems, USA; Figure 1) inserted for sampling under vacuum assistance. The number of biopsy cuttings depended on size of the lesion and was at the discretion of the radiologist. After adequate sampling,



**Figure 1.** Vacuum assisted biopsy needle (EnCor).

a metallic marker (Gel Mark; Bard Biopsy Systems, USA; Figure 2) was deployed at the corresponding site. The incision required no sutures. Compression of the wound to decrease haematoma formation was applied for at least 20 minutes. The patient underwent post-biopsy mammogram in both cranio-caudal (CC) and medio-lateral oblique (MLO) views after 4 hours. Marker migration in any direction would be routinely stated in the report to facilitate follow-up and future surgery.

## Subjects

From January 2010 to June 2015, all patients who underwent stereotactic VAB at Kwong Wah Hospital were included for review via the electronic patient records and Hologic Selenia workstations.

Patient factors including age, breast density according to Breast Imaging–Reporting and Data System (BIRADS: entirely fatty, scattered areas of fibroglandular density, heterogeneously dense, or extremely dense) and breast compression thickness were noted.

Lesion characteristics including indication for biopsy (mass, distortion, or grouped microcalcification), BIRADS category, needle approach for biopsy (CC, reverse CC, lateral-medial, or medio-lateral), depth of the lesion within the breast (z value) and whether it was periareolar in location were documented.

Procedure-related factors including the number of biopsy cuttings, any complications such as haematoma, and total duration of the entire procedure including planning were also obtained.

Finally, in our local practice, any degree of marker migration was routinely stated in the report. All images and reports were retrospectively reviewed by one of our breast radiologists. The maximum marker migration in CC or MLO view measured from the centre of the radiological abnormality was recorded. With consensus between the radiology and the breast surgery departments at our hospital, marker migration of <1 cm



**Figure 2.** Metallic marker (Gel Mark).

was considered acceptable and would not affect surgical localisation. Marker migration of >1 cm could potentially affect surgical planning.

In cases with marker migration and where further surgery was needed, more accurate localisation could still be achieved by radioguided occult lesion localisation using a radioactive substance or by hookwire localisation. The level of required accuracy depended on the histology of the radiological abnormality and the intended resection margin.

The patients provided written informed consent, and approval was obtained from the local ethics committee.

### Statistical Analysis

Chi-square test was used to analyse categorical variables including breast density, BIRADS category, needle approach, whether it was periareolar in location, and presence of complications in association with marker

migration. The independent *t*-test was used to analyse continuous variables including age, breast compression thickness, number of biopsy cuttings, and duration in correlation with marker migration.

### RESULTS

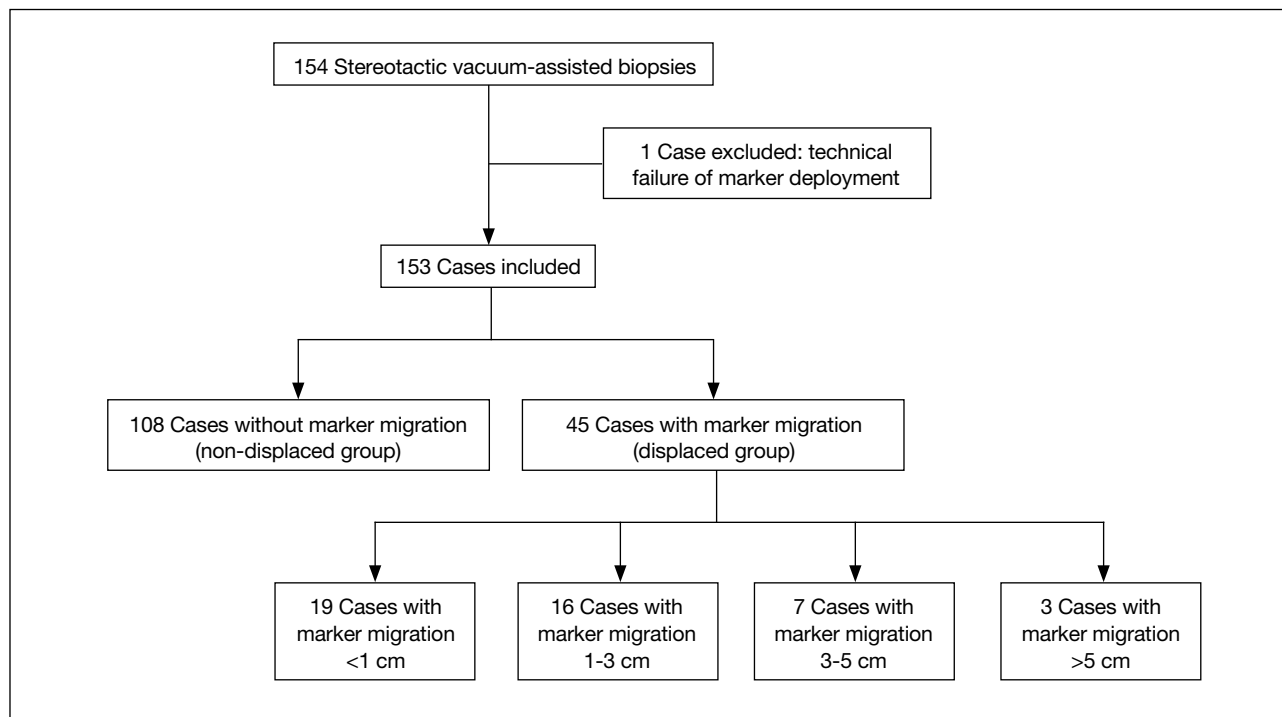
A total of 154 Asian patients underwent stereotactic VAB during the study period. One patient was excluded due to technical failure during deployment of marker (Table).

Of the 153 patients, overall accuracy of marker placement was 71% (Figure 3). There was migration of 45 (29%) metallic markers, of which 19 (12.4%) were <1 cm, 16 (10%) 1-3 cm (Figure 4), 7 (5%) 3-5 cm, and 3 (2%) >5 cm. Management was not affected in the 12% of patients with marker migration of <1 cm. All cases with marker displacement of >1 cm were reviewed at the multidisciplinary breast meeting between the radiologists and surgeons. A follow-up plan was

**Table.** Summary of results according to subgroups.

	Displaced marker group (n = 45)	Non-displaced marker group (n = 108)	p Value
Age (years)*	56 (42-73)	53 (39-70)	0.03
Lesion type			
Grouped microcalcifications	44 (98%)	88 (81%)	0.23
Distortion	1 (2%)	14 (13%)	
Mass	0	6 (6%)	
BIRADS category			
2	14 (31%)	23 (21%)	0.34
3	12 (27%)	46 (43%)	
4a	11 (24%)	23 (21%)	
4b	4 (9%)	12 (11%)	
4c	3 (7%)	4 (4%)	
5	1 (2%)	0	
Breast density			
Entirely fatty	0	0	0.10
Scattered fibroglandular	19 (42%)	20 (19%)	
Heterogeneously dense	22 (49%)	78 (72%)	
Extremely dense	4 (9%)	10 (9%)	
Needle approach			
Cranio-caudal (CC)	3 (7%)	6 (6%)	0.23
Reverse CC	0	1 (1%)	
Lateral-medial	33 (73%)	60 (56%)	
Medial-lateral	9 (20%)	41 (38%)	
Breast compression thickness (mm)*	47 (31-67)	43 (23-70)	0.05
Depth of the lesion (z value in mm)*	28 (13-41)	27 (10-46)	0.61
Location			
Anterior third	13 (29%)	38 (35%)	0.39
Middle third	30 (67%)	68 (63%)	
Posterior third	2 (4%)	2 (2%)	
Periareolar location	1	0	0.48
No. of biopsy cuttings*	11 (4-28)	9 (1-17)	0.03
Complications: hematoma	5 (56%)	4 (44%)	0.83
Procedure time (mins)*	45 (20-90)	39 (20-75)	0.04

\* Mean (range) is shown.



**Figure 3.** Flowchart showing displaced and non-displaced groups.

devised depending on the indication, histology, family history, and requirement for future surgery. Among patients with >5 cm marker migration, two showed no malignancy and the third required operation for atypical ductal hyperplasia but the patient refused.

The following shows statistical significance between the displaced and non-displaced groups: mean age (56 vs. 53 years;  $p = 0.03$ ), mean breast compression thickness (47 vs. 43 mm;  $p = 0.05$ ), mean number of biopsy cuttings (11 vs. 9;  $p = 0.03$ ), and mean procedure time (45 vs. 39 mins;  $p = 0.04$ ) [Table].

The type of lesions (grouped microcalcifications, distortion, and mass), breast density (entirely fatty, scattered fibroglandular, and heterogeneously and extremely dense), BIRADS category, approach of needle entry, location of radiological abnormalities, and depth of the lesion (z value) show no statistical significance between the displaced and non-displaced groups (Table).

Complications were reported in nine patients, all were haematoma (Figure 5) that ranged from 1 cm to 3 cm of which five (56%) occurred in the displaced group

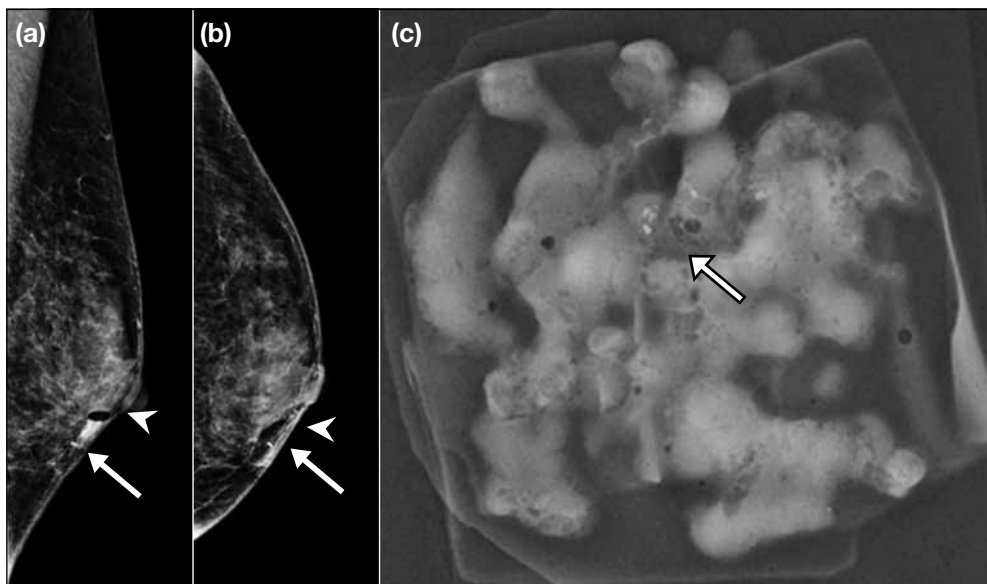
and four (44%) in the non-displaced group. This did not show a statistical difference.

## DISCUSSION

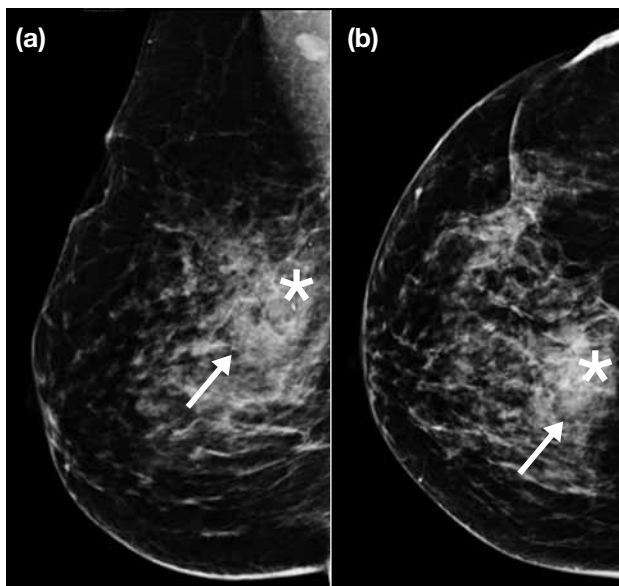
More elderly women would find the prone position difficult to tolerate for long periods of time. The prone position is difficult to hold and uncomfortable, especially in the shoulder and neck region. Therefore appropriate patient selection and adequate explanation to the patient is crucial.

With regard to breast compression thickness, thicker breasts tend to have more displacement. It is postulated that in thicker breasts, as the compression force is released, more breast tissue re-expands and can lead to the ‘accordion effect’ as described in previous literature.<sup>9-11</sup> Previous studies recommend that the compression be partially released immediately prior to clip deployment to minimise the accordion effect.<sup>9</sup>

As the number of biopsy cuttings increases, the biopsy cavity becomes larger. It is postulated that this allows more space for the marker to be deployed into and therefore increases the chance for migration. This is in line with previous literature.<sup>9-13</sup> The number of



**Figure 4.** The (a) medio-lateral oblique and (b) cranio-caudal views showing the metallic marker (arrows) displaced 1 cm inferior and medial to the corresponding site of biopsy (arrowheads). (c) Sample showing removal of the grouped microcalcifications (arrow).



**Figure 5.** The (a) medio-lateral oblique and (b) cranio-caudal views showing haematoma (arrows) at the site of biopsy and non-displaced metallic marker (asterisks).

biopsy cuttings also depends on the size of radiological abnormality.

It is also postulated that patient movement potentially changes the x, y, z coordinates and therefore likely increases the chance of marker migration. The longer

the duration of the procedure, the more difficult it is to lie still in an uncomfortable prone position with the breast compressed, thus resulting in a higher chance of marker displacement. Therefore patients with neck or back problems should be identified well beforehand.

There are limitations in this study. First, the sample size was relatively small so the number of complications such as haematoma cannot be adequately evaluated to determine a true effect on marker migration. Second, marker migration can occur immediately after the procedure but delayed migration is also possible, therefore further studies with follow-up mammograms could help analyse factors that affect delayed migration.

## CONCLUSION

Marker migration after stereotactic VAB can influence subsequent follow-up and treatment. This study identified four statistically significant factors including older age, thicker breasts, greater number of biopsy cuttings, and longer procedure time that could cause marker migration. Awareness of these factors for appropriate patient selection and planning of the procedure could help decrease the effect of marker migration and thus lead to more accurate surgical localisation.

## REFERENCES

1. Kettritz U, Rotter K, Schreer I, Muraier M, Schulz-Wendtland R, Peter D, et al. Stereotactic vacuum-assisted breast biopsy in 2874

- patients: a multicenter study. *Cancer*. 2004;100:245-51. [cross ref](#)
2. Park HL, Kim LS. The current role of vacuum assisted breast biopsy system in breast disease. *J Breast Cancer*. 2011;14:1-7. [cross ref](#)
  3. Park HL, Hong J. Vacuum-assisted breast biopsy for breast cancer. *Gland Surg*. 2014;3:120-7.
  4. Tongegutti M, Girardi V. Stereotactic vacuum-assisted breast biopsy in 268 nonpalpable lesions. *Radiol Med*. 2008;113:65-75. [cross ref](#)
  5. Birdwell RL, Jackman RJ. Clip or marker migration 5-10 weeks after stereotactic 11-gauge vacuum-assisted breast biopsy: report of two cases. *Radiology*. 2003;229:541-4. [cross ref](#)
  6. Philpotts LE, Lee CH. Clip migration after 11-gauge vacuum-assisted stereotactic biopsy: case report. *Radiology*. 2002;222:794-6. [cross ref](#)
  7. Harris AT. Clip migration within 8 days of 11-gauge vacuum-assisted stereotactic breast biopsy: case report. *Radiology*. 2003;228:552-4. [cross ref](#)
  8. Parikh J. Ultrasound demonstration of clip migration to Skin within 6 weeks of 11-gauge vacuum-assisted stereotactic breast biopsy. *Breast J*. 2004;10:539-42. [cross ref](#)
  9. Esserman LE, Cura MA, DaCosta D. Recognizing pitfalls in early and late migration of clip markers after imaging-guided directional vacuum-assisted biopsy. *Radiographics*. 2004;24:147-56. [cross ref](#)
  10. Burbank F, Forcier N. Tissue marking clip for stereotactic breast biopsy: initial placement accuracy, long-term stability, and usefulness as a guide for wire localization. *Radiology*. 1997;205:407-15. [cross ref](#)
  11. Rosen EL, Vo TT. Metallic clip deployment during stereotactic breast biopsy: retrospective analysis. *Radiology*. 2001;218:510-6. [cross ref](#)
  12. Liberman L, Dershaw DD, Morris EA, Abramson AF, Thornton CM, Rosen PP. Clip placement after stereotactic vacuum-assisted breast biopsy. *Radiology*. 1997;205:417-22. [cross ref](#)
  13. Bernaerts A, De Schepper A Jr, Van Dam P, Pouillon M. Clip migration after vacuum-assisted stereotactic breast biopsy: a pitfall in preoperative wire localization. *JBR-BTR*. 2007;90:172-5.