Hong Kong J Radiol. 2016;19:303-7 | DOI: 10.12809/hkjr1615328

PICTORIAL ESSAY

Magnetic Resonance Imaging of Breast Augmentation and Complications: a Pictorial Essay

HHC Tsang, JWC Wai, JLF Chiu

Department of Radiology and Imaging, Queen Elizabeth Hospital, Jordan, Hong Kong

ABSTRACT

With an increasing number of women undergoing breast augmentation and later presenting with breast symptoms, radiologists need to be familiar with the different imaging appearances. Mammography and ultrasonography is one of the first steps in the diagnostic workup of a woman who presents with breast symptoms. In the absence of typical features of implant rupture, however, further evaluation with magnetic resonance imaging is often necessary to determine implant integrity and complications or to detect a possibly malignant lesion.

Key Words: *Breast implantation; Magnetic resonance imaging; Mammoplasty; Postoperative complications; Prosthesis failure*

中文摘要

隆胸和術後併發症的磁共振成像：圖文回顧

曾凱晴、衞穎莊、趙朗峯

隨着越來越多女性接受隆胸手術，隨之而來的術後併發症也越見普遍。放射科醫生須要熟悉不同表現的成像。出現乳房症狀的婦女往往須要首先進行乳房X線成像和超聲檢查。但假如成像結果未顯示有植入物破裂，必須使用磁共振成像來進一步評估植入物的完整性，以及有否併發症，甚至檢查惡性病變的可能。

INTRODUCTION

The first recorded breast augmentation was described by Czerny in 1985 and used autologous fat.[1] Since then, numerous techniques have been employed to address the need for breast augmentation in women, whether it be for cosmetic benefit or for patients who require post-mastectomy reconstructions. The most common method is implantation of a breast prosthesis, although many other forms of breast augmentation with free injection of different materials (e.g. liquid paraffin wax, liquid silicone, and polyacrylamide gel) are still seen.

With an increasing number of women undergoing breast augmentation and later presenting with breast

Correspondence: *Dr Hailey HC Tsang , Department of Radiology and Imaging, Queen Elizabeth Hospital, Jordan, Hong Kong. Email: drhaileytsang@gmail.com*

Submitted: 13 May 2015; Accepted: 1 Dec 2015.

Disclosure of Conflicts of Interest: All authors have disclosed no conflicts of interest.

symptoms, radiologists need to be familiar with different imaging appearances. Mammography and ultrasonography is one of the first steps in the diagnostic workup of a woman who presents with breast symptoms. In the absence of typical features of implant rupture, however, further evaluation with magnetic resonance imaging (MRI) is often necessary to determine implant integrity and complications or to detect possible malignancy.

This pictorial essay aimed to describe the various types of breast augmentation and their complications on MRI.

BREAST PROSTHESES

There are numerous kinds of breast implants available, with a few common ones frequently encountered.[2] The two main types are the saline-filled and single-lumen silicone gel-filled prostheses.[1] These implants consist of a silicone elastomer shell or envelope filled with saline or silicone gel. Those filled with silicone gel can be single-lumen (Figure 1), double-lumen, or reverse double-lumen. Breast prostheses can be positioned deep to the fibroglandular tissue (retroglandular or subglandular) or deep to the pectoralis major muscle (retropectoral or subpectoral). Once the implant has been placed, the process of encapsulation ensues wherein a thin layer of fibrous tissue develops around the implant as a normal physiological response to a foreign substance within the body.

IMPLANT COMPLICATIONS

In the early post-implantation period, the most common complications include haematoma and infection (Figures 4b to 4e). As previously mentioned, encapsulation of the implant occurs as a normal physiological response to a foreign body. When the normal thin fibrous capsule thickens, abnormal constriction can occur and result in capsular contracture, usually within the first few postoperative months. This is usually a clinical diagnosis when patients present with distorted, tender, and inflamed breasts. It is often not appreciated radiologically unless there are alterations to the shape of the implant.

Implant rupture is the most common delayed implant complication. The incidence of rupture increases with implant age. Saline implant ruptures are usually readily detected clinically with rapid implant decompression.

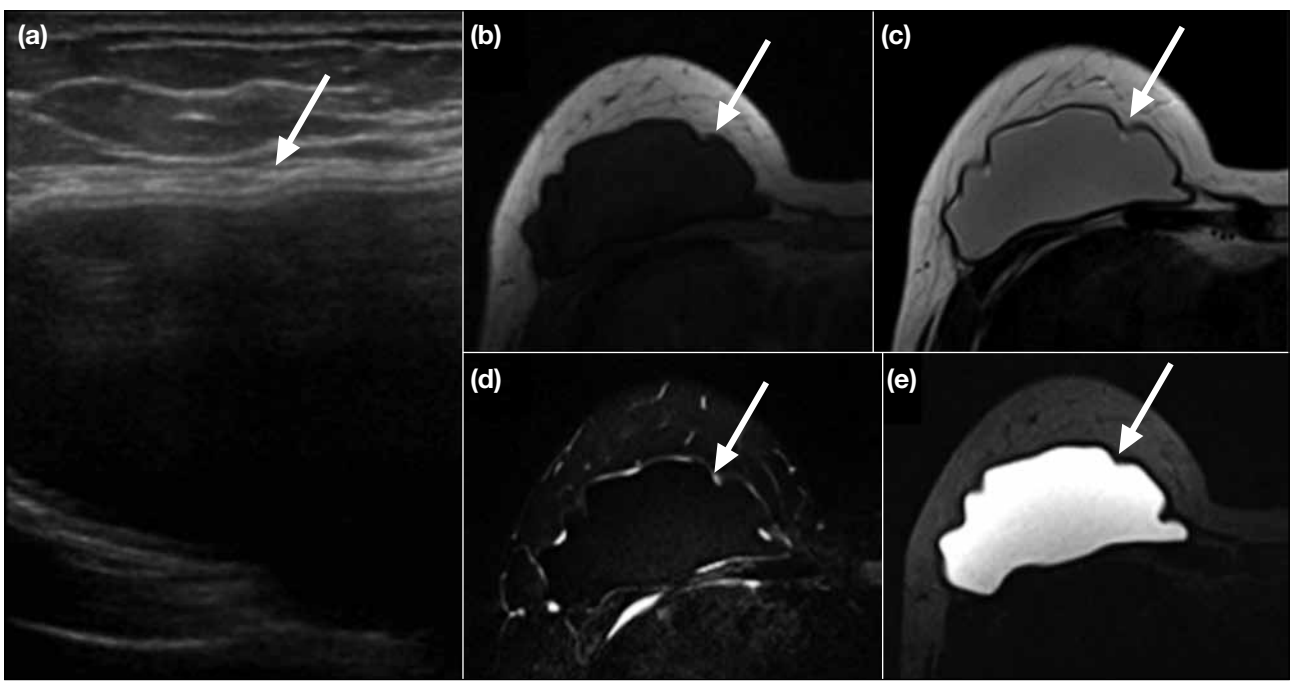

Figure 1. A 38-year-old woman with a history of single lumen silicone implant (arrows). (a) Ultrasound image shows intact implant. Subsequent magnetic resonance imaging (MRI) is performed to ascertain the implant integrity. (b) T1-weighted MRI scan, (c) T2-weighted (T2W) turbo spin echo MRI scan, (d) T2W MRI scan with fat and silicone saturation, and (e) T2W MRI scan with fat and water suppression. Intact silicone implant showing T2W hyperintense signal that is a suppressed on silicone suppression image and not on water suppression image (e).

If imaged, the collapsed silicone shell will appear wrinkled and folded. Silicone implant ruptures may be more difficult to detect clinically. A study in Alabama, USA that included 687 women with silicone implants estimated that the median age of implant rupture was 10.8 years and was more commonly observed in implants in a submuscular location.[3] Silicone implant ruptures can be classified as intra- or extra-capsular, with the majority being intra-capsular (77%-89%).[3]

Intra-capsular rupture of a silicone breast implant is defined as rupture of the implant shell with silicone leakage that does not macroscopically extend beyond the fibrous capsule. On MRI, intra-capsular rupture with collapse can be illustrated by the linguine sign: presence of multiple curvilinear low-signal intensity ruptured shell floating within the T2-weighted high-signal intensity silicone gel (Figure 2). When there is intra-capsular rupture without collapse, free silicone can be detected in between the outer fibrous capsule and the inner implant shell and produce the subcapsular line, teardrop or noose, and key-hole signs on MRI. The

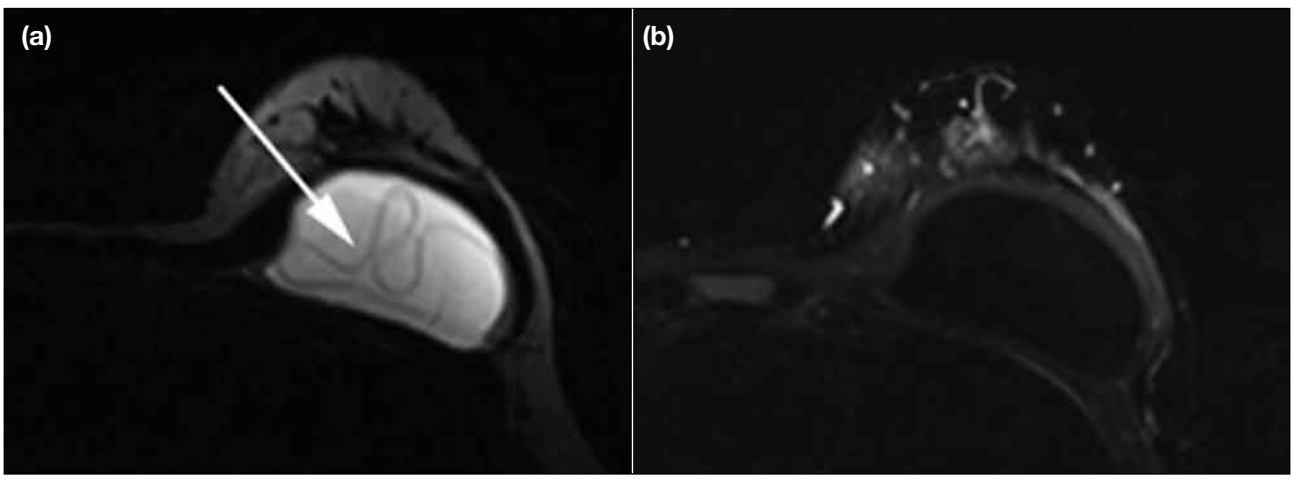

Figure 2. Magnetic resonance imaging of a 41-year-old woman with bilateral breast implants showing left implant rupture: (a) axial water-suppression and (b) axial silicone-suppression images. Intra-capsular rupture of a single lumen silicone filled implant with presence of 'linguine sign' (arrow) in the left breast.

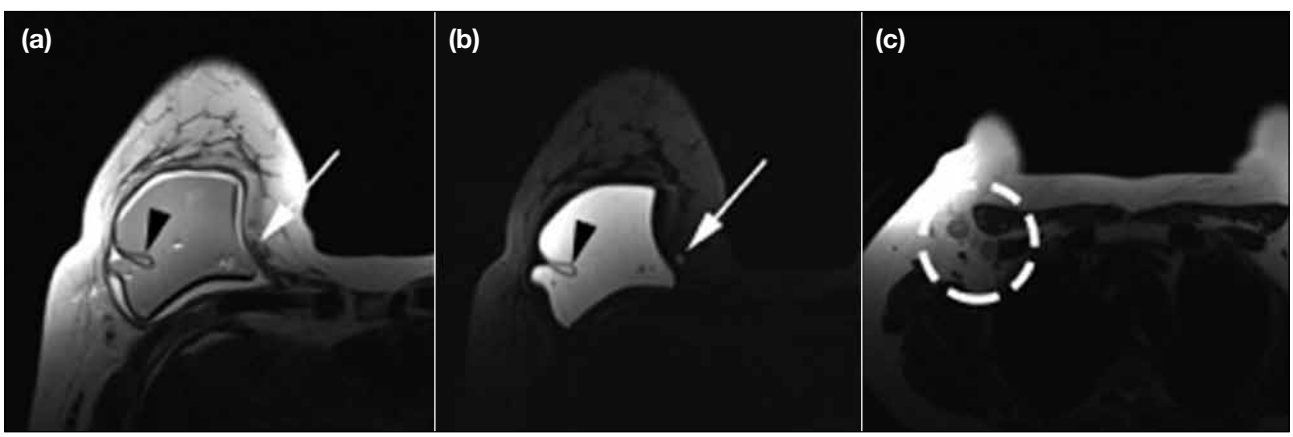

Figure 3. A 42-year-old woman presenting with hardening of a right breast silicone implant. (a) Axial T2-weighted magnetic resonance imaging (a) turbo spin echo scan, (b) scan with fat and water suppression, and (c) turbo spin echo scan at a higher level than (a). Right intra-capsular rupture is seen with presence of 'tear-drop sign' (arrowheads). The small focus (arrows) of hyperintense signal on water suppression image (b), with signal intensity parallel to the silicone implant at the medial aspect is indicative of extra-capsular silicone and therefore extra-capsular rupture. (c) Prominent level I axillary lymph nodes (dotted circle) are present, likely reactive and related to underlying intra- and extra-capsular implant rupture.

subcapsular line sign describes lines running almost parallel to and just beneath the fibrous capsule. The teardrop / noose sign and the key-hole sign describe small invagination of the shell and differ in that the two membranes in the former do not touch and in the latter they do (Figure 3).[4]

Extra-capsular silicone implant rupture describes the rupture of both the outer fibrous capsule and the inner implant shell with macroscopic silicone leakage into the surrounding tissues. On MRI, this can be detected by the presence of high signal intensity areas parallel to the signal of the silicone gel outside the fibrous capsule (Figures 3a and 3b).[5]

Gel bleed differs from implant rupture as it represents normal transudation of microscopic amounts of silicone gel through an intact implant shell.[6] This phenomenon is closely related to the chemical affinity between the outer silicone implant shell and the silicone gel inside. Transudate silicone gel can migrate, even reaching the upper limbs, liver, inguinal lymph nodes, synovium, skin, and plural fluid. Gel bleeds have not been reported with the new cohesive gel implants.[7] Most normal transudation of microscopic amounts of silicone gel is undetected by MRI unless the gel bleed is extensive.

BREAST AUGMENTATION WITH FREE INJECTION

Prior to the widespread use of breast implants, various synthetic materials consisting of petroleum jelly, paraffin, or injectable silicone gel (Figures 4a, 4d to 4f) were commonly used, particularly in Asian countries in the 1950s. Since the 1990s, injectable hydrogel such as polyacrylamide has also been used.[8] These injected foreign materials can also result in complications such as migration, infection (Figure 5), inflammation, discolouration, and the formation of granulomas,

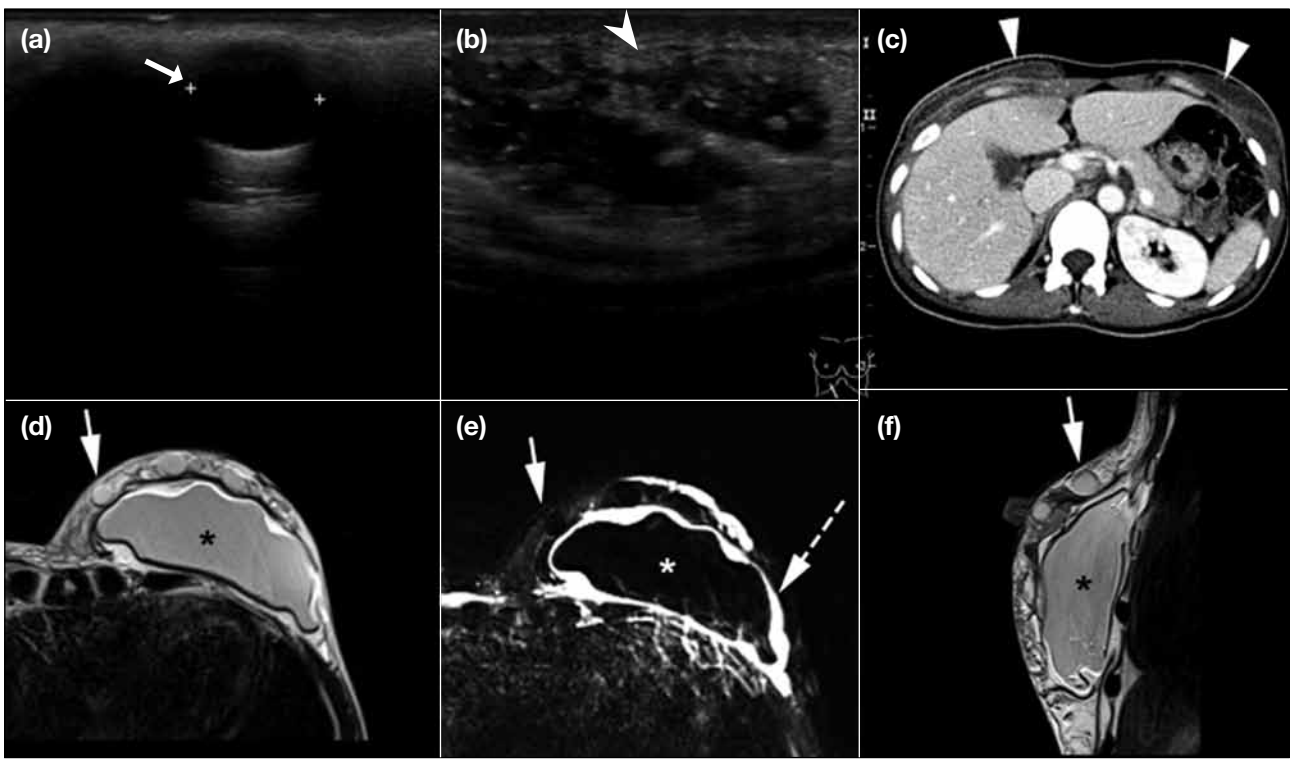

Figure 4. A 48-year-old woman with bilateral silicone implants and silicone injections presenting with upper abdominal wall pus discharge. (a and b) Ultrasound of left breast, (c) axial contrast computed tomography (CT) of the upper abdomen, (d) axial T2-weighted (T2W) turbo spin echo magnetic resonance imaging (MRI) scan, (e) axial T2W MRI scan with silicone suppression, and (f) sagittal T2W turbo spin echo MRI scan. Silicone implant (*) is seen in the left breast showing T2W hyperintense signal (d and f) that is suppressed on silicone-suppression image (e). Multiple subcutaneous nodules (arrows) are seen on (a) ultrasound and (d, e, f) MRI scans with parallel signal to the silicone implant, compatible with free injection of silicone. There is also a rim of T2 hyperintense fluid (dotted arrow) surrounding the left breast implant, corresponding to a known infected collection. Bilateral rim enhancing collections (arrowheads) are seen at the anterior upper abdominal wall bilaterally as shown on (b) ultrasound and (c) CT.

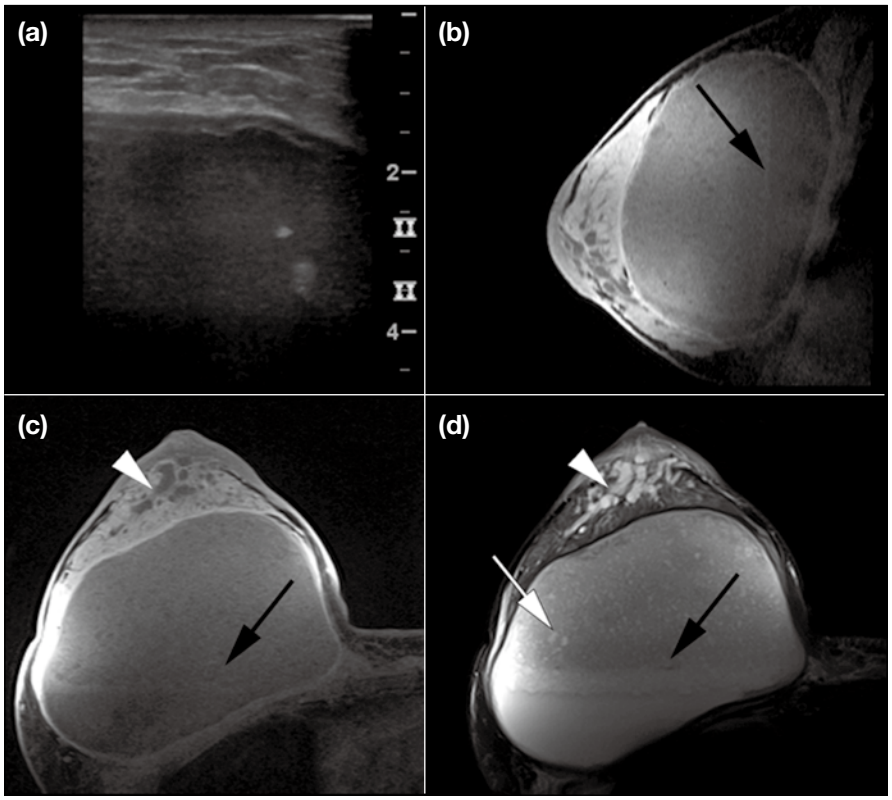

Figure 5. A 34-year-old lactating mother, with a history of breast augmentation by injection, presenting with engorgement, erythema, and tenderness of bilateral breasts. (a) Transverse ultrasound image, (b) sagittal and (c) axial T1-weighted gradient echo magnetic resonance imaging (MRI) with fat saturation and (d) T2-weighted turbo spin echo MRI with fat saturation. Huge retroglandular fluid collection is seen in the right breast. On ultrasound (a), only the superficial parts can be evaluated. On MRI, the imaging modality of choice, there is dependent layering of infected material (black arrows) and injected foreign substance (white arrow). Engorgement of ducts (white arrowheads) is seen in the retroareolar region, consistent with lactating history. The patient subsequently underwent incision and drainage of the right breast collection that yielded more than 1200 ml of purulent fluid with gelatinous debris.

ulceration, and fistulae.

Although the use of mammography can help distinguish between saline and silicone implants due to their difference in densities, its use in differentiating injectable substances is limited. Ultrasound is also of little value in substance differentiation. Although breast MRI can be utilised in the assessment of implant complications and integrity, identification of the type of substance injected may not be always possible, even with the use of different pulse sequences. This may be due to injection of a mixture of different substances, formation of granuloma, or different degrees of foreign body reaction towards each injected lobule of foreign substance within the breasts.

REFERENCES

1. Spear SL, Parikh PM, Goldstein JA. History of breast implants and the food and drug administration. Clin Plast Surg. 2009;36:15-21,v. cross ref
2. Middleton MS, McNamara MP Jr. Breast implant classification with MR imaging correlation: (CME available on RSNA link). Radiographics. 2000;20:E1. cross ref
3. Brown SL, Middleton MS, Berg WA, Soo MS, Pennello G. Prevalence of rupture of silicone gel breast implants revealed on MR imaging in a population of women in Birmingham, Alabama. AJR Am J Roentgenol. 2000;175:1057-64. cross ref
4. Roller R, Chetlen A, Kasales C. Imaging of breast implants and their associated complications. J Am Osteopath Coll Radiol. 2014;3:2-9.
5. Hölmich LR, Vejborg I, Conrad C, Sletting S, McLaughlin JK. The diagnosis of breast implant rupture: MRI findings compared with findings at explantation. Eur J Radiol. 2005;53:213-25. cross ref
6. Yang N, Muradali D. The augmented breast: a pictorial review of the abnormal and unusual. AJR Am J Roentgenol. 2011;196:W451-60. cross ref
7. Colombo G, Ruvolo V, Stifanese R, Perillo M, Garlaschi A. Prosthetic breast implant rupture: imaging — pictorial essay. Aesthetic Plast Surg. 2011;35:891-900. cross ref
8. Kawahara S, Hyakusoku H, Ogawa R, Ohkubo S, Igarashi H, Hirakawa K. Clinical imaging diagnosis of implant materials for breast augmentation. Ann Plast Surg. 2006;57:6-12. cross ref