

---

---

## CASE REPORT

---

---

# Percutaneous Transcatheter Embolisation of the Renal Artery for Chronic Unilateral Haematuria

S Park<sup>1</sup>, JH Kwon<sup>1</sup>, YH Han<sup>1</sup>, KS Lee<sup>2</sup>

<sup>1</sup>Department of Radiology and <sup>2</sup>Department of Urology, Dongguk University Ilsan Hospital, Dongguk University, Dongguk-ro 27, Ilsandong-gu, Goyang-si, Gyeonggi-do, Republic of Korea.

### ABSTRACT

*Chronic unilateral haematuria is an intermittent or continuous gross haematuria that cannot be diagnosed using standard radiological or haematological tests. Electrocoagulation or laser coagulation through flexible ureteroscopy has been widely used for its diagnosis and treatment. We report the first case of percutaneous transcatheter embolisation of the renal artery for chronic unilateral haematuria.*

*Key Words: Embolization, therapeutic; Hematuria; Kidney; Ureteroscopy*

## 中文摘要

### 經皮導管栓塞腎動脈治療慢性單側血尿

S Park, JH Kwon, YH Han, KS Lee

慢性單側血尿是間歇性或連續性血尿，無法使用標準放射學或血液學檢查進行診斷。通過輸尿管軟鏡進行電凝或激光凝固已被廣泛用於診斷和治療。本文報告首例經皮導管栓塞腎動脈治療慢性單側血尿。

### INTRODUCTION

Chronic unilateral haematuria is an intermittent or continuous gross haematuria that cannot be diagnosed using standard radiological and haematological tests.<sup>1,2</sup> Traditional treatments include palliative therapy and nephrectomy. Flexible ureteroscopy has enabled more effective options of electrocoagulation and laser coagulation.<sup>1,3-5</sup> We report the first case of percutaneous transcatheter embolisation of the renal artery for chronic unilateral haematuria.

### CASE REPORT

In October 2014, a 34-year-old man presented with a 1-year history of intermittent gross haematuria and anaemia. He had no history of parenchymal renal disease, urinary tract infection, analgesic abuse, flank trauma, use of anticoagulants, bleeding disorder, or any type of renal surgery (including biopsy). Approximately 2.3 years previously, contrast-enhanced abdomen-pelvic computed tomography (CT) and renal angiography performed elsewhere revealed no definitive abnormal

---

*Correspondence: Dr JH Kwon, Department of Radiology, Dongguk University Ilsan Hospital, Dongguk University, Dongguk-ro 27, Ilsandong-gu, Goyang-si, Gyeonggi-do, 410-773, Republic of Korea.  
Email: jhkwon17@naver.com*

Submitted: 10 Aug 2015; Accepted: 1 Dec 2015.

Disclosure of Conflicts of Interest: All authors have disclosed no conflicts of interest.


finding in the urinary system. Cystoscopy revealed haematuria from the right ureteral orifice. He was transferred to our hospital where flexible ureteroscopy revealed a small, pulsating, purple-coloured nodular lesion in the mid-posterior calyx of the right kidney (Figure 1). The patient was treated conservatively and gross haematuria resolved. One year later, he again presented with intermittent gross haematuria and received several blood transfusions to manage anaemia.

His physical examination was unremarkable. His haemoglobin level was 109 g/l, and haematocrit level was 35.7%. Urinalysis revealed proteinuria and gross haematuria. Red blood cells were recorded as >50% per high-power field in urine. Bleeding time, activated partial thromboplastin time, prothrombin time, platelet count, serum creatinine, and blood urea nitrogen were normal. Urine and blood cultures for bacteria and fungi were negative. Cystoscopy showed bleeding from the right ureteral orifice. Contrast-enhanced kidney CT showed a small, low-attenuating lesion within the mid-posterior calyx of the right kidney (Figure 2).

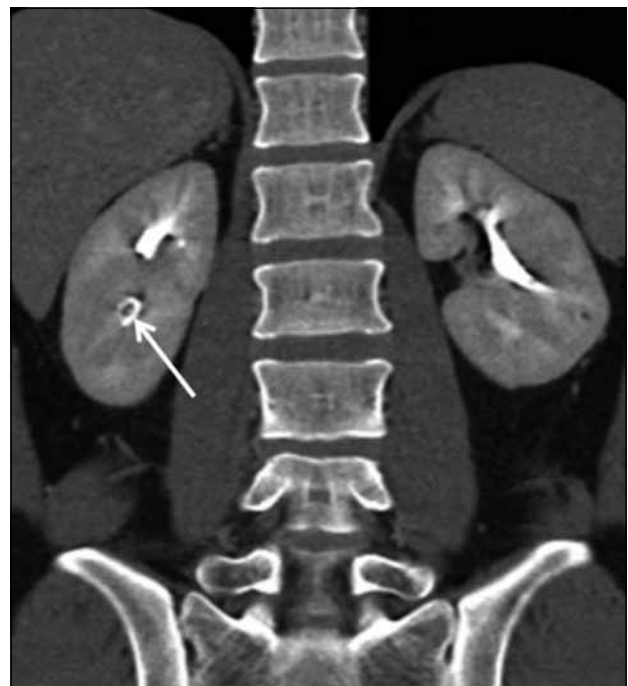Embolisation of the renal artery supplying the mid-posterior calyx of the right kidney (rather than nephrectomy) was planned. Diagnostic right renal artery angiography via a 5 Fr catheter and a 6 Fr renal guiding

sheath showed no detectable abnormality such as hypervascular lesion or contrast extravasation (Figure 3). A 2.0 Fr microcatheter and a 0.016-inch guidewire were used to select the interlobar arteries supplying the mid-posterior parenchyma of the right kidney. Embolisation was performed blindly for these targeted interlobar arteries using polyvinyl alcohol (PVA) particles (300–500 µm; Cook Medical, Bloomington [IN], USA) and microcoils (Tornado; Cook Medical, Bloomington [IN], USA). An abnormal vascular structure or hypervascular staining was not apparent.

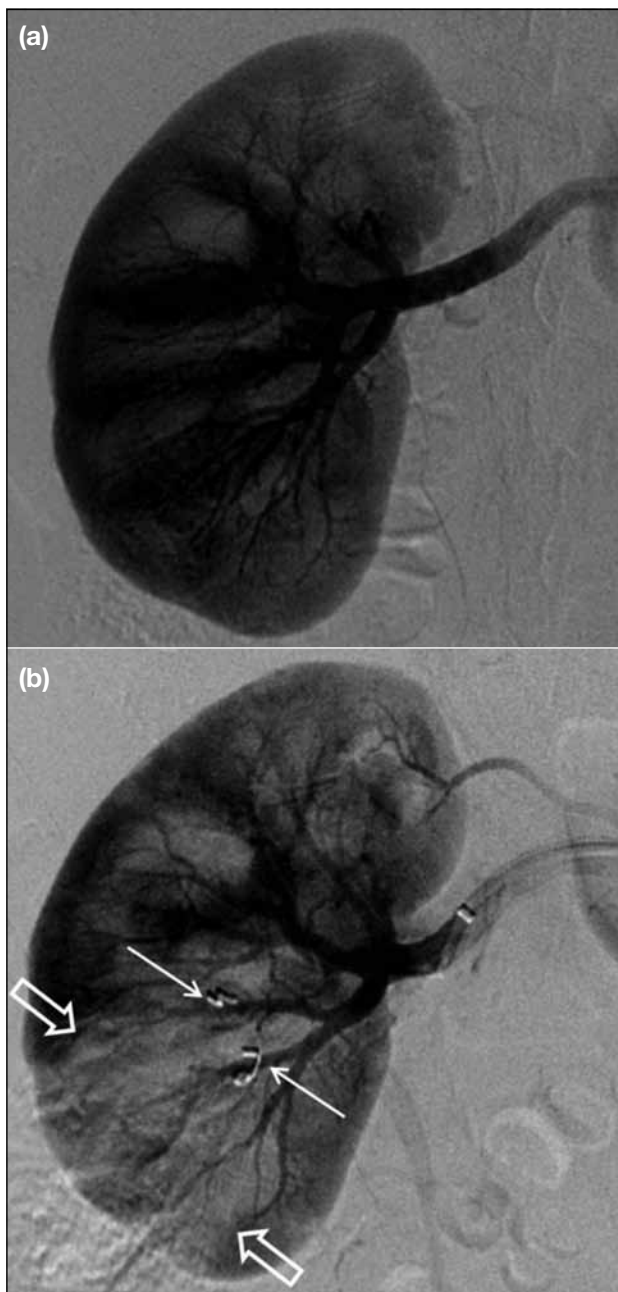
Post-embolisation angiography revealed decreased parenchymal loading in the lower posterior segment of the right kidney and preserved blood flow to the remaining portion (Figure 3). There was no acute procedure-related complication, except mild pain in the right flank induced by focal ischaemia. Renal function tests including serum creatinine and blood urea nitrogen tests were normal. Gross haematuria disappeared immediately. The patient's hospital stay was uneventful and he was discharged after 3 days. He remains well without any complications 8 months later.



**Figure 1.** Ureteroscopy showing a small, pulsating, purple-coloured nodular lesion in the mid-posterior calyx of the right kidney (arrows).



**Figure 2.** Coronal reconstructed image of the excretory phase of contrast-enhanced computed tomography showing a small, low-attenuating nodular lesion within the mid-posterior calyx of the right kidney (arrow).



**Figure 3.** Angiography of the right kidney showing (a) no detectable abnormal staining or vascular abnormality before percutaneous transcatheter embolisation of interlobar renal arteries, and (b) partial defect in renal parenchymal staining (hollow arrows) in mid-to-lower pole of the kidney and microcoils (arrows) after embolisation.

## DISCUSSION

Patients with chronic unilateral haematuria are diagnosed as having unilateral, benign, or lateralising essential haematuria, upper track haematuria, or benign lateralising haematuria.<sup>1,4,6</sup> In 56% of such patients,

intermittent or persistent gross haematuria may continue for 4 to 18 years following conservative management. Most patients show a relatively low rate of anaemia, do not develop renal failure, and remain in good health without the need for surgical intervention.<sup>2</sup>

The aetiology and pathogenesis of chronic unilateral haematuria are poorly understood. Various conditions cause haematuria such as renal haemangioma, transitional cell carcinoma, focal erythema, ureteric stenosis, varices of the renal papilla, haemorrhagic papillitis, pyelovenous fistula, renal forniceal haemorrhages, minute venous rupture, calculus, and renal venous hypertension.<sup>1,3,5</sup> Haemangioma is the most common finding by ureteroscopy, but in 16% of patients there is no detectable lesion.<sup>1</sup> Precise pathological and histological assessment is lacking because of limited biopsies.<sup>1,3,5</sup> The use of digital flexible ureteroscopy has enabled easier diagnosis and treatment, and chronic unilateral haematuria is no longer an ‘idiopathic’ disease.<sup>7</sup>

Most cases of chronic unilateral haematuria have a microscopic pathophysiology, and a definitive diagnosis cannot be made through standard radiological studies such as intravenous pyelography, retrograde pyelography, renal ultrasonography, renal CT, renal angiography, or renal magnetic resonance imaging.<sup>5,6,8</sup>

Cystoscopy can reveal the haematuria to be supravescical in origin from one or both ureteral orifices.<sup>1,6</sup> Comprehensive endoscopic examination of the entire collecting system and ureter is needed for a definitive diagnosis. Flexible ureteroscopy is useful to locate the precise site of bleeding.<sup>5,6</sup> In our patient, cystoscopy revealed bleeding from the right ureteral orifice, and flexible ureteroscopy showed a small, pulsating, purple-coloured nodular lesion in the mid-posterior calyx of the right kidney. These findings suggested a tiny haemangioma, although the possibility of a benign lesion or other vascular lesion could not be excluded. Kidney CT revealed the small low-attenuating lesion with no growth or change.

Traditional treatment for recurrent, prolonged gross haematuria is bed rest, blood transfusion, and instillation of silver nitrate into the renal pelvis. Life-threatening haematuria can be treated with partial or total nephrectomy.<sup>1,3,6</sup> Flexible ureteroscopy enables nephron-sparing treatment with minimum complications and has become the mainstay of treatment for chronic

unilateral haematuria.<sup>1,3</sup> Ureteroscopic treatment achieves an overall success rate of 92% in patients with discrete ureteroscopic abnormalities, 76% in those with diffuse lesions, and 64% in those with no ureteroscopic lesions.<sup>1</sup> Electrocoagulation is used in >80% of cases and is an established treatment for bladder lesions.<sup>3,8</sup> It is safe, effective, inexpensive, and widely available, with a success rate of 90%.<sup>3</sup> The use of a holmium:YAG laser and neodymium:YAG laser is also effective for coagulating lesions in the upper urinary tract that cause chronic unilateral haematuria.<sup>1,5</sup> Laser coagulation is effective for all tissue types and can deliver sufficient energy to lesions of the thin-walled renal calyx. The small size of the laser fibre and its flexibility are useful for ureteroscopic application.<sup>5,6</sup> Disadvantages of laser coagulation include the high cost of the equipment, need for anaesthesia, occasional inability of the ureteroscope to access the upper tract, inability or difficulty in inspecting all the calyces, and spillage of tumour cells into the renal parenchyma and vascular circulation. Complications of ureteroscopy include ureteral avulsion and ureteral stenosis.<sup>9</sup>

Renal artery embolisation can be used for treatment, palliation, and prevention of various conditions.<sup>10</sup> It is mandatory to exclude the possibility of a malignant lesion. We performed percutaneous transcatheter embolisation of the renal artery because electrocoagulation or laser coagulation was not available in our hospital. The interlobar arteries supplying the mid-posterior parenchyma of the kidney were embolised using PVA particles and microcoils in a blind manner.

Renal angiography showed no abnormal tumour staining or arteriovenous malformation or shunting, and thus there was no concern that PVA particles could cause paradoxical ischaemic complications when passing through arteriovenous fistula or shunting. Microcoils were used to permanently embolise the proximal portion of the interlobar arteries.

## REFERENCES

1. Rowbotham C, Anson KM. Benign lateralizing haematuria: the impact of upper tract endoscopy. *BJU Int.* 2001;88:841-9. [cross ref](#)
2. Lano MD, Wagoner RD, Leary FJ. Unilateral essential hematuria. *Mayo Clin Proc.* 1979;54:88-90.
3. Araki M, Uehara S, Sasaki K, Monden K, Tsugawa M, Watanabe T, et al. Ureteroscopic management of chronic unilateral hematuria: a single-center experience over 22 years. *PLoS One.* 2012;7:e36729. [cross ref](#)
4. Bagley DH. Removal of upper urinary tract calculi with flexible ureteropyeloscopy. *Urology.* 1990;35:412-6. [cross ref](#)
5. Brito AH, Mazzucchi E, Vicentini FC, Danilovic A, Chedid Neto EA, Srougi M. Management of chronic unilateral hematuria by ureterorenoscopy. *J Endourol.* 2009;23:1273-6. [cross ref](#)
6. Dooley RE, Pietrow PK. Ureteroscopy for benign hematuria. *Urol Clin North Am.* 2004;31:137-43. [cross ref](#)
7. Takazawa R, Kitayama S, Tsujii T. Digital ureteroscopic visualization of lesions responsible for chronic unilateral hematuria, so-called idiopathic renal bleeding. *Int J Urol.* 2014;21:227-8. [cross ref](#)
8. Mugiya S, Ozono S, Nagata M, Takayama T, Furuse H, Ushiyama T. Ureteroscopic evaluation and laser treatment of chronic unilateral hematuria. *J Urol.* 2007;178:517-20. [cross ref](#)
9. Yazaki T, Kamiyama Y, Tomomasa H, Shimizu H, Okano Y, Iiyama T, et al. Ureteropyeloscopy in the diagnosis of patients with upper tract hematuria: an initial clinical study. *Int J Urol.* 1999;6:219-25. [cross ref](#)
10. Ginat DT, Saad WE, Turba UC. Transcatheter renal artery embolization: clinical applications and techniques. *Tech Vasc Interv Radiol.* 2009;12:224-39. [cross ref](#)