
ORIGINAL ARTICLE

Bismuth Radioprotective Gonadal Shields: Prevalence of Use and Effect on Image Quality during Paediatric Pelvic Radiography

V Karami¹, M Zabihzadeh^{2,3}, N Shams⁴

¹*School of Allied Medical Sciences, Dezful University of Medical Sciences, Dezful, Iran*

²*Medical Physics Department, School of Medical Sciences, Ahvaz Jundishapur University of Medical Sciences, Ahvaz, Iran*

³*Clinical Oncology Department, Golestan Hospital, School of Medicine, Ahvaz Jundishapur University of Medical Sciences, Ahvaz, Iran*

⁴*Oral and Maxillofacial Radiology Department, School of Dentistry, Ahvaz Jundishapur University of Medical Sciences, Ahvaz, Iran*

ABSTRACT

Objective: Traditional lead gonadal shields may not be effective to reduce radiation exposure, owing to poor compliance from radiographers and frequent repeated examinations due to obscured diagnostic areas. This study aimed to evaluate the effect of bismuth shields on image quality during paediatric pelvic radiography.

Methods: We previously developed bismuth radioprotective gonadal shields for use in paediatric pelvic radiography at our institution. We retrospectively retrieved and reviewed radiographic images from an existing digital image library. All images were examined for the presence and accurate positioning of gonadal shields. The diagnostic image quality was assessed by an experienced evaluation panel with selected imaging criteria adapted from the European guidelines.

Results: A bismuth shield was present in 154 of 198 radiographs of boys and in 170 of 182 radiographs of girls. In boys, the shield protected the testes area adequately in 92 images and partially in 51 images. The shield obscured the remaining 11 images, rendering image quality suboptimal according to the European guidelines. In girls, the shield protected the ovaries adequately in 169 images and partially in one image. No significant differences were seen between the quality of shielded and non-shielded images.

Conclusion: Our study demonstrated that these shields do not have a detrimental effect on image quality and can be recommended for routine use.

Key Words: Bismuth; Gonads; Radiation protection

Correspondence: Dr M Zabihzadeh, Medical Physics Department & Clinical Oncology Department, School of Medicine, Ahvaz Jundishapur University of Medical Sciences, Ahvaz, Iran.
Email: manzabib@gmail.com

Submitted: 21 Feb 2017; Accepted: 7 Apr 2017.

Disclosure of Conflicts of Interest: All authors have no conflicts of interest to disclose.

Funding/Support: This study was a part of MSc thesis results of the first author and supported financially by the research affairs of Ahvaz Jundishapur University of Medical Sciences, Ahvaz, Iran (Grant No. U-94150).

中文摘要

新研發的鉍輻射防護性腺屏蔽：放射師的依從性和對兒科盆腔放射攝影圖像質量的影響

V Karami、M Zabihzadeh、N Shams

目的：由於放射師對使用鉛性腺屏蔽的遵從性欠佳，加上在診斷時往往因出現遮蓋之處而須重覆檢查，這種傳統屏蔽減少輻射欠為有效。本研究旨在評估鉍屏蔽對兒科患者盆腔造影質量的影響。

方法：我們曾開發鉍輻射防護性腺屏蔽作兒科盆腔放射造影時使用。本研究回溯及回顧現存圖庫中的X線圖像以檢視是否放置到位屏蔽性腺，並由經驗豐富的評核小組根據歐洲成像評選標準評估這些診斷圖像的質量。

結果：在198張男性和182張女性X線圖像中，使用鉍屏蔽分別為154和170例。男性患者中，92張圖像顯示屏蔽充分保護睪丸區域，局部保護的有51張，其餘11張因放置不佳影響根據歐洲標準訂立的圖像質量。女性患者中，169張圖像顯示屏蔽充分保護卵巢範圍，局部保護的則有1張。屏蔽和非屏蔽圖像的質量沒有顯著差異。

結論：研究結果顯示使用這種屏蔽對圖像質量沒有不良影響，可考慮作常規用途。

INTRODUCTION

Radiography of the pelvis is frequently requested by paediatricians to assess clinical problems in paediatric patients.¹⁻³ In the United Kingdom, pelvic radiography has been identified as the third highest contributor to radiation exposure from medical imaging.⁴ Owing to the location of the reproductive organs in the primary radiation field, it is essential that their absorbed dose is kept as low as reasonably achievable. Thus, shielding the gonads with 1-mm lead sheet has been common practice among radiographers since the 1950s.⁵ However, positioning of such shields is frequently incorrect. This results in repeated examinations that consequently increase the total radiation dose.^{1,6} Moreover, variability of the ovarian position within the pelvic region is an added challenge for using lead shields for female patients.¹ Accordingly, the use and effectiveness of traditional gonad lead shields during female pelvic radiography has been challenged by some researchers in recent decades.^{1,6-11} For male patients, use of lead shields is also controversial and the effectiveness depends on the skill and effort of radiographers.⁸ Therefore, materials that attenuate the primary beam before reaching the patient but allow sufficient radiation to pass through the shield to generate diagnostic image should be considered. Bismuth is an appropriate alternative to lead and has these favourable characteristics. The effectiveness of bismuth in reducing radiation exposure from tissues included in the primary beam has previously been shown

for computed tomography procedures.^{12,13} In a previous study, we designed bismuth radioprotective gonadal shields for paediatric patients and verified their efficacy in reducing the received radiation dose and maintaining image quality.¹⁴ The shield for girls consists of a square bismuth garment (0.06 mm lead equivalent) intended to cover the entire pelvic region. A lead piece at the cranial edge of the shield absorbs scatter radiation to protect the radiosensitive organs located outside of the primary field. The shield for boys consists of an ellipsoid lead piece with a 2-cm bismuth fringe. Extensive thermoluminescent dosimetry measurements and visual grading analysis (VGA) of the resultant images revealed a 62% reduction in absorbed radiation dose of the ovaries without adversely affecting image quality.¹⁴

The present study aimed to investigate the prevalence of use and effect on image quality of bismuth gonadal shields during paediatric pelvic radiography.

METHODS

We used bismuth gonadal shields that we previously developed for use in paediatric pelvic radiography at our institution.¹⁴ In the present retrospective study, we reviewed our experience using these shields for a 6-month period (July 2016 to January 2017) and assessed the efficacy of these developed shields for anteroposterior projection paediatric pelvic radiography. Radiographs were considered eligible for inclusion if

the patients were aged ≤ 15 years, a commonly used cut-off value,^{2,6-8,15-17} and in the supine position when the radiographs were taken. Patients who had multiple radiographs taken were also included in the study. An evaluation panel of two radiographers, a medical physicist and a radiologist, all with at least 4 years of experience in general radiography, examined all images for evidence of the gonadal shield. Images with visible protection were then further evaluated for accuracy of the positioning of the gonadal shield. According to the standard protocols, the shield should cover the entire pelvic region in girls and the scrotal region in boys, without adversely affecting the image quality or obscuring diagnostic areas.

For VGA image quality assessments, we defined seven criteria for each image according to European guidelines (Table 1¹⁸). Following Grondin et al,¹⁹ for each criterion, a 4-point VGA scoring scale was applied: 0 (unacceptable and not diagnostic), 1 (diagnostically acceptable, but lower than the reference image), 2 (optimum, equal to the reference image), or 3 (excellent, better than the reference image). Because assessing all images in terms of image quality and VGA is time consuming,⁴ the VGA was piloted on 15% ($n = 25$) of the available shielded images and 25 non-shielded images, selected at random from the 170 pelvic radiographs of girls included in the study.

Table 1. Image criteria adopted from European guidelines for assessing image quality.¹⁸

1. Visualisation of the sacrum and its intervertebral foramina depending on bowel content
2. Reproduction of the lower part of the sacroiliac joints
3. Reproduction of the necks of the femora
4. Visualisation of the trochanters consistent with age
5. Visualisation of the peri-articular soft tissue planes
6. Reproduction of the pubic and ischial rami
7. Reproduction of the spongiosa and corticalis

A gold-standard reference image (non-shielded) was provided from the digital image library in which each criterion was independently interpreted as optimum by all members of the evaluation panel. All shielded and non-shielded images were compared with this reference image on adjacent negatoscopes with equal light intensity. The evaluation panel was blinded to the concept of the study.

Statistical Analysis

Data were transferred to an Excel spreadsheet (Microsoft, Redmond [WA], US), and statistical analysis was performed using SPSS (Windows version 16.0; SPSS Inc, Chicago [IL], US). The statistical differences between shielded and non-shielded radiographs of girls in terms of VGA scores were assessed parametric Student's *t* test.³ The mean and standard deviation were calculated for all image quality scores. A *P* value < 0.05 was considered statistically significant.

RESULTS

A total of 380 pelvic radiographs were identified from 323 paediatric patients. A gonadal shield was present in 154 of 198 radiographs of boys and in 170 of 182 radiographs of girls.

In radiographs of boys, the shield protected the testes area adequately in 92 cases and partially in 51 cases. The shield obscured the remaining 11 radiographs, three of which obscured important anatomical landmarks; however, no repeat radiographs were found. In 73 radiographs, the positioning of the gonad shielding was considered unsatisfactory because the pelvis was partially covered. However, the image quality remained diagnostically acceptable in 62 of these radiographs because the bismuth fringe provided additional filtering, allowing diagnostic assessment of the pelvis in these images (Table 2 and Figure 1).

Table 2. Positioning of the developed gonadal shields in paediatric pelvic radiography.*

Gonadal shield	Boys (n = 198)	Girls (n = 182)	Total (n = 380)
No protection	44 (22.2)	12 (6.6)	56 (14.7)
Satisfactory protection	92 (59.7)	169 (99.4)	261 (80.6)
Partial protection	51 (33.1)	1 (0.6) [†]	52 (16.0)
Unsatisfactory positioning (obscuring diagnostic criteria)	11 (7.1) [†]	0	11 (3.4)

* Data are shown as No. (%) of subjects.

[†] In three radiographs the shield obscured important anatomical landmarks and should have been repeated; however, no repeat radiographs were found.

[‡] The ovaries were adequately protected, but the shield did not cover the entire pelvic region.

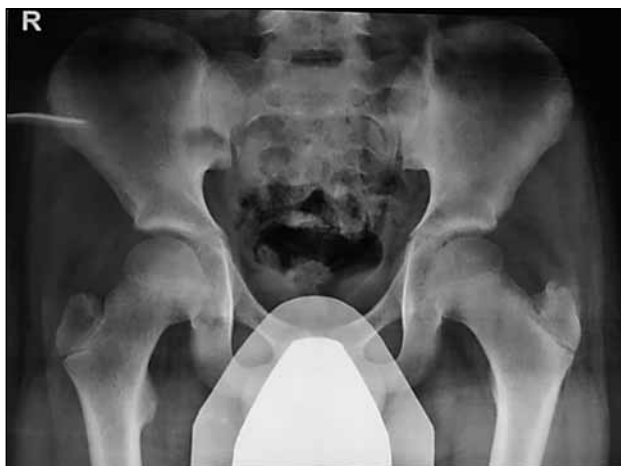

Figure 1. Pelvic radiograph of boy with newly developed testes shield. Although the actual positioning of the shield is unsatisfactory, the image quality is diagnostically acceptable.

Table 3. Mean visual grading analysis (VGA) scores in shielded and non-shielded radiographic images of girls.

Girl patients	VGA scores \pm standard deviations (from 0 to 3)
Shielded	1.314 \pm 0.523
Non-shielded	1.497 \pm 0.555

In radiographs of girls, the shield protected the ovaries area adequately in 169 cases and partially in one case. VGA showed that 23 of 25 (15%) images with shielding and 24 of 25 non-shielded images had diagnostically acceptable image quality; the remaining three images were unacceptable and not diagnostic. The exposure parameters (kVp and/or mAs) recorded on these images indicate that these settings were incorrect. These incorrect settings were likely the main source for deterioration of image quality. Although shielded images had more noise than in non-shielded images (Table 3), the mean (standard deviation) VGA scores were not significantly different (1.314 ± 0.523 vs 1.497 ± 0.555 ; $P > 0.05$). We found no radiographs of “excellent” quality (better than the reference image). Representative samples of “optimum”, “diagnostically acceptable”, and “unacceptable and not diagnostic” are shown in Figure 2.

DISCUSSION

Radiation protection and image quality are two fundamental principles of radiology science.²⁰ Our results indicate that, where a gonadal shield is used, its positioning is adequate in 99.4% (169 of 170) of radiographs of girls and 59.7% (92 of 154) of radiographs

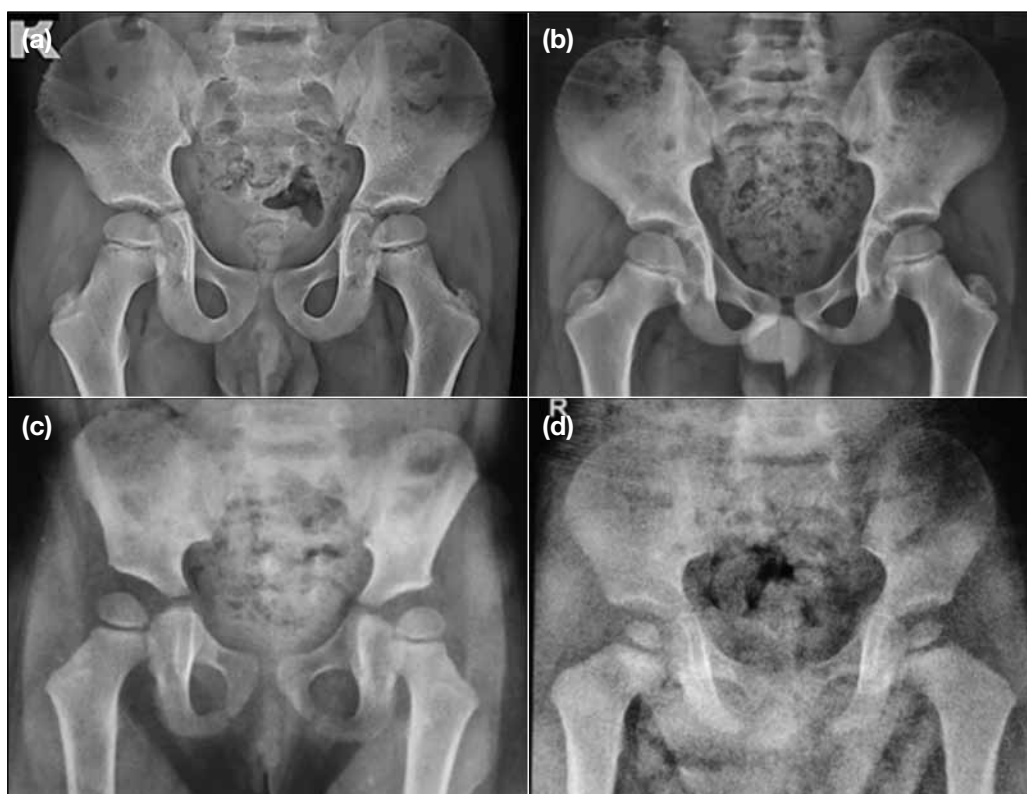


Figure 2. Radiographs of different qualities. (a) Reference image, (b) “optimum”, (c) “diagnostically acceptable”, and (d) “unacceptable and not diagnostic”. No image was found with excellent quality (better than the reference image).

of boys. Moreover, VGA of images of girls revealed 92% (23 of 25) of images with shielding and 96% (24 of 25) of images without shielding had diagnostically acceptable quality. Although the actual positioning of the shield was unsatisfactory in 73 radiographic images of boys, the image quality was considered acceptable in 62 images because the bismuth fringe allowed diagnostic evaluation (Figure 1). In a similar study with a traditional lead shield,⁶ gonadal shields were used in only 5.4% of girl and 16.4% of boy pelvic radiographs; unsatisfactory shield positioning was found in 84.3% and 55.3% and repeat imaging required in 21.5% and 10.6% of these cases, respectively. Similar findings have been reported elsewhere in the literature.^{9,21}

Gonad protection is significant in pelvic radiography; the germ cells within the gonads are susceptible to radiation damage such as genetic and somatic malignancies.⁶ Irradiating the lower part of the colon and pelvis bone is an added concern in paediatric pelvic radiography.¹ The risk of exposure-induced cancer death arising from anteroposterior pelvic radiography in an individual patient aged ≤ 15 years has been estimated to be 10.94 per million population for boys and 6.76 per million population for girls, respectively.²² Special attention to radiation protection is required for paediatric patients due to the relatively high radiosensitivity of their gonads

and because their longer life expectancy allows more time to manifest radiation effects.⁶ This is consistent with recommendations of the International Commission on Radiological Protection, which states that the risk of radiation-induced cancer per Sievert is 2.6-times higher for paediatric patients compared with the population as a whole (13% vs 5%).²³

The low adherence rate of radiographers applying lead shields is reported to result from the complexity in identifying gonadal position in relation to surface landmarks and the risk of obscuring bony structures.^{5,24,25} Our developed bismuth ovarian shield protects the ovaries, colon, and pelvis bone by covering the entire pelvic region. Because bismuth shields can be placed more easily without concern for obscuring diagnostic features, these developed shields are easier to use, especially in crowded and emergency radiology centres. An example of bismuth radioprotective gonadal shields in boy and girl subjects is presented in Figure 3. Its applicability for patients with diagnosed or suspected sacral trauma is an added benefit. Although radiographs of girls with gonadal shields were noisier than those of girls without, the quality of both remained diagnostically acceptable. Training to improve the skills and qualifications of radiographers is key to improving accurate positioning of gonadal shields for boys undergoing pelvic radiography.

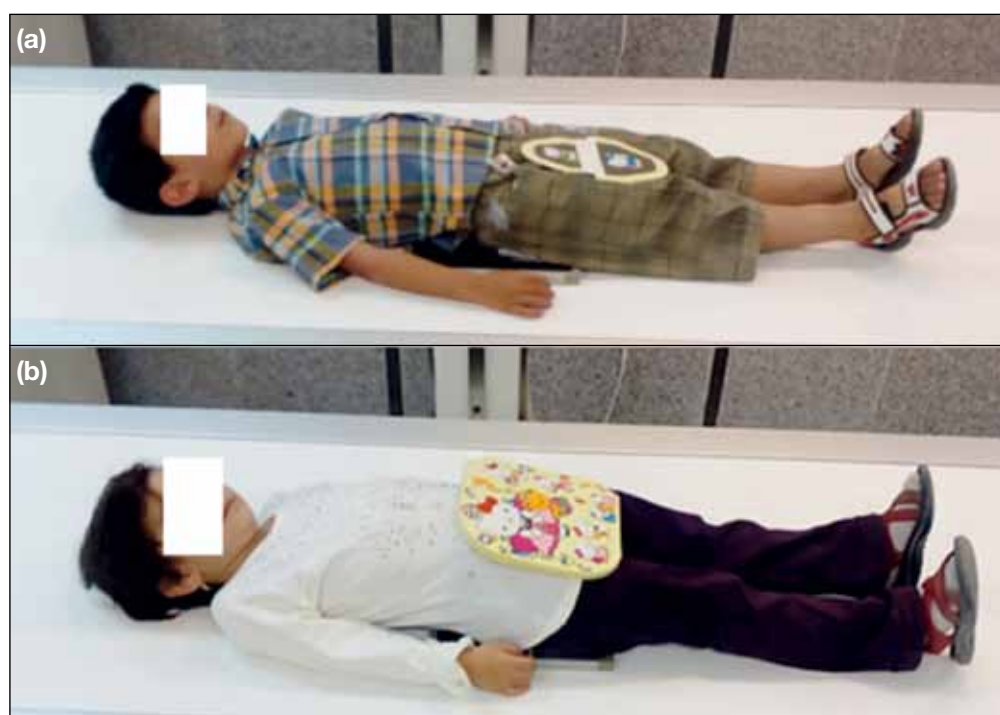

Figure 3. Bismuth radioprotective gonadal shields in boy (top) and girl (bottom) subjects.

CONCLUSION

Our developed bismuth shield protects the gonads, colon, and pelvic bone by covering the entire pelvic region, without obscuring radiological landmarks, and reduces the possibility of repeat radiographs owing to poor shield location. These shields do not have a detrimental effect on image quality and have the potential to be recommended for routine use. More studies are needed to assess the prevalence of this developed gonadal shield in pelvic radiography.

REFERENCES

1. Karami V, Zabihzadeh M, Shams N, Saki Malehi A. Gonad shielding during pelvic radiography: a systematic review and meta-analysis. *Arch Iran Med*. 2017;20:113-23.
2. Gul A, Zafar M, Maffulli N. Gonadal shields in pelvic radiographs in pediatric patients. *Bull Hosp Jt Dis*. 2005;63:13-4.
3. Chan CT, Fung KK. Dose optimization in pelvic radiography by air gap method on CR and DR systems — a phantom study. *Radiography*. 2015;21:214-23. [Crossref](#)
4. Heath R, England A, Ward A, Charnock P, Ward M, Evans P, et al. Digital pelvic radiography: increasing distance to reduce dose. *Radiol Technol*. 2011;83:20-8.
5. Karami V, Zabihzadeh M, Gholami M. Gonad shielding for patients undergoing conventional radiological examinations: is there cause for concern? *Jentashapir J Health Res*. 2016;7:e31170. [Crossref](#)
6. Karami V, Zabihzadeh M, Shams N, Sarikhani S. Evaluation of the prevalence and utility of gonad shielding in pediatrics undergoing pelvic X-Ray. *Int J Pediatr*. 2016;4:3735-40.
7. Warlow T, Walker-Birch P, Cosson P. Gonad shielding in pediatric pelvic radiography: effectiveness and practice. *Radiography*. 2014;20:178-82. [Crossref](#)
8. Frantzen MJ, Robben S, Postma AA, Zoetelief J, Wildberger JE, Kemerink GJ. Gonad shielding in paediatric pelvic radiography: disadvantages prevail over benefit. *Insights imaging*. 2012;3:23-32. [Crossref](#)
9. Liakos P, Schoenecker PL, Lyons D, Gordon JE. Evaluation of the efficacy of pelvic shielding in preadolescent girls. *J Pediatr Orthop*. 2001;21:433-5. [Crossref](#)
10. Bardo DM, Black M, Schenk K, Zaritzky MF. Location of the ovaries in girls from newborn to 18 years of age: reconsidering ovarian shielding. *Pediatr Radiol*. 2009;39:253-9. [Crossref](#)
11. Fawcett SL, Gomez AC, Barter SJ, Ditchfield M, Set P. More harm than good? The anatomy of misguided shielding of the ovaries. *Br J Radiol*. 2012;85:442-7. [Crossref](#)
12. McLaughlin D, Mooney R. Dose reduction to radiosensitive tissues in CT. Do commercially available shields meet the users' needs? *Clinical radiology*. 2004;59:446-50. [Crossref](#)
13. Fricke BL, Donnelly LF, Frush DP, Yoshizumi T, Varchena V, Poe SA, et al. In-plane bismuth breast shields for pediatric CT: effects on radiation dose and image quality using experimental and clinical data. *American Journal of Roentgenology*. 2003;180:407-11. [Crossref](#)
14. Karami V, Zabihzadeh M, Shams N, Gholami M. Radioprotection to the gonads in pediatric pelvic radiography: Effectiveness of developed bismuth shield. *Int J Pediatr*. 2017;5:5153-66.
15. Sikand M, Stinchcombe S, Livesley PJ. Study on the use of gonadal protection shields during paediatric pelvic X-rays. *Ann R Coll Surg Engl*. 2003;85:422-5. [Crossref](#)
16. Fawcett SL, Barter SJ. The use of gonad shielding in paediatric hip and pelvis radiographs. *Br J Radiol*. 2009;82:363-70. [Crossref](#)
17. Masud S, Mehra A, Clothier JC. Study on the use of gonadal shields in paediatric pelvic X-rays. *J Bone Joint Surg Br*. 2008;90-B:338.
18. Directorate-General XII-Science R, Development. European Guidelines on Quality Criteria for Diagnostic Radiographic Images in Paediatrics. European Union, European Commission; 1996.
19. Grondin Y, Matthews K, McEntee M, Rainford L, Casey M, Tonra M, et al. Dose-reducing strategies in combination offers substantial potential benefits to females requiring X-ray examination. *Radiat Prot Dosimetry*. 2004;108:123-32. [Crossref](#)
20. Zabihzadeh M, Karami V. Poor collimation in digital radiology: A growing concern. *Internet J Med Update*. 2016;11:29-30. [Crossref](#)
21. Doolan A, Brennan PC, Rainford LA, Healy J. Gonad protection for the antero-posterior projection of the pelvis in diagnostic radiography in Dublin hospitals. *Radiography*. 2004;10:15-21. [Crossref](#)
22. Nahangi H, Chaparian A. Assessment of radiation risk to pediatric patients undergoing conventional X-ray examinations. *Radioprotection*. 2015;50:19-25. [Crossref](#)
23. International Commission on Radiological Protection. 1990 Recommendations of the International Commission on Radiological Protection. Oxford Pergamon; 1991.
24. MacKay M, Hancy C, Crowe A, D'Rozario R, Ng C. Attitudes of medical imaging technologists on use of gonad shielding in general radiography. *Radiographer*. 2013;59:35-9. [Crossref](#)
25. Kenny N, Hill J. Gonad protection in young orthopaedic patients. *BMJ*. 1992;304:1411-3. [Crossref](#)