Hong Kong J Radiol. 2018;21:196-212 | DOI: 10.12809/hkjr1816853

PICTORIAL ESSAY

CME

Review of Normal Anatomy and Common Pathologies in Dental Imaging

JHM Cheng, SY Luk, DCW Tang, JAWK Tang, DTF Lee, ACW Tam, WKW Leung, WK Kan, JLS Khoo

Department of Radiology, Pamela Youde Nethersole Eastern Hospital, Chai Wan, Hong Kong

ABSTRACT

In imaging of the head and neck regions, the dental space is an area which many radiologists are less familiar with and which often does not receive adequate attention. Dental and periodontal pathologies are hence often overlooked and underreported in daily practice. This article reviews the normal anatomy and imaging findings of the common pathologies in the dental region. Dental infection and inflammation are commonly encountered and have a variety of manifestations with different degrees of severity, ranging from asymptomatic incidental findings, local infection confined within the dental space, and inflammation of the adjacent paranasal sinuses (i.e. odontogenic sinusitis), to severe and extensive deep neck infection. Odontogenic cysts and neoplasms are occasionally seen, most of which are benign. The challenge in the imaging of these lesions is to distinguish them from other mandibular lesions that demonstrate similar radiological appearances. A detailed clinical history and careful imaging interpretation are very helpful in narrowing the differential diagnosis and guiding management. Developmental anomalies (eg, supernumerary teeth, ectopic tooth) of the dentition are usually isolated incidental findings or a manifestation of a syndromal disease such as Gorlin-Goltz syndrome and cleidocranial dysostosis. Finally, dental injury should be carefully evaluated in the context of head and neck trauma, including injury to the tooth itself, the periodontal structures and the associated complications (eg, aspiration of fractured tooth). Learning and becoming familiar with the basic dental anatomy and common pathologies are essential in identifying diseases and making accurate diagnoses.

Key Words: *Head/anatomy & histology; Neck/anatomy & histology; Odontogenic cysts; Odontogenic tumors; Periodontal diseases*

中文摘要

牙科成像中正常解剖學和常見病理學回顧

鄭希敏、陸嬈、鄧峻樺、鄧永健、李騰飛、譚枝慧、梁錦榮、簡偉權、邱麗珊

在頭部和頸部成像中，牙齒區域是不少放射科醫生不太熟悉且沒有充份關注的範疇。因此，牙科和牙周病變經常在日常診症中被忽視和低估。本文回顧牙齒區域常見病理的正常解剖學和影像學表現。牙齒感染和炎症是常見病症且具有不同重度的各種表現，包括無症狀的偶然發現、牙齒內的局

Correspondence: *Dr JHM Cheng, Department of Radiology, Pamela Youde Nethersole Eastern Hospital, 3 Lok Man Road, Chai Wan, Hong Kong.*
Email: chenghmj@gmail.com

Submitted: 25 Jan 2017; Accepted: 13 Apr 2017.

Disclosure of Conflicts of Interest: The authors have no conflicts of interest to disclose.

部感染和鄰近鼻旁竇的炎症（即牙源性鼻竇炎），及至嚴重和廣泛深頸部感染。牙源性囊腫和腫瘤偶發大多屬良性。在成像學角度將上述病變與表現類似的下頜骨病變區分是一項挑戰。詳盡的臨床病史和仔細的成像詮釋有助鑑別診斷和指導治療。牙齒發育異常（如多生牙、異位牙）通常是個別偶然發現或如Gorlin-Goltz綜合徵和鎖骨顱骨發育不全等綜合症的表現。此外，在頭頸部創傷時應仔細評估牙齒損傷，包括牙齒本身的損傷、牙周結構和相關併發症（如吸入斷牙）。學習並熟悉基本牙科解剖學和常見病理對於識別疾病和作出準確診斷至關重要。

INTRODUCTION

Imaging of the head and neck region is challenging due to the diverse spectrum of pathologies and the complicated anatomy that is composed of multiple compartments. Dental pathologies, although frequently encountered as incidental findings during investigations for other head and neck conditions, have not received equal attention in the literature and are often overlooked compared with other head and neck pathologies.

This pictorial review summarises the clinical and radiological features of some common dental conditions, including those of inflammation and infection, odontogenic cysts and neoplasms, developmental abnormalities, and tooth trauma.

NORMAL ANATOMY

The mandibular and maxillary teeth are each embedded within the respective alveolar processes that divide the oral cavity into two compartments: the more central compartment adjacent to the tongue is the oral cavity proper, while the more peripheral compartment adjacent to the buccal mucosa is the oral vestibule.[1]

There are two sets of dentition: primary (deciduous) and permanent. The adult permanent dentition contains 32 teeth, 16 in the mandible and 16 in the maxilla, and includes two incisors, one canine, two premolars, and three molars in each quadrant. A fully dentured paediatric jaw contains 20 teeth, lacking the premolars and one molar from each quadrant.[1,2]

There are several naming systems for teeth, including the American Dental Association (ADA) universal numbering system, the Fédération Dentaire Internationale system, and the Palmer notation system.[2,3] The ADA numbering system is illustrated in Figure 1.

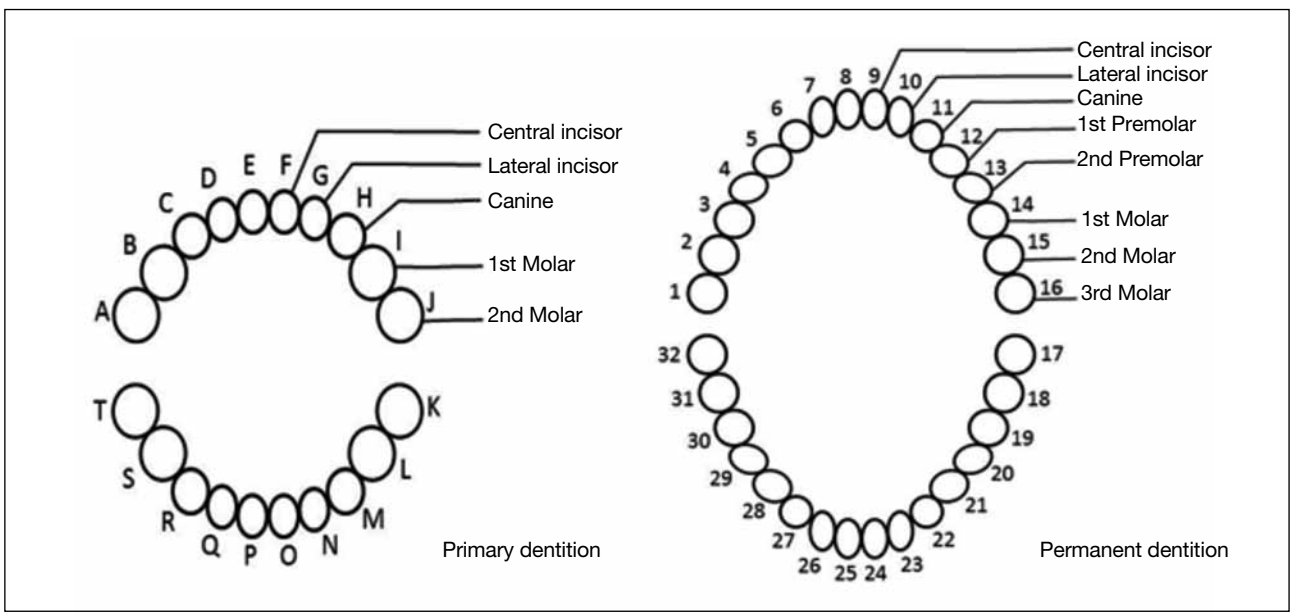

Figure 1. The universal numbering system adopted by the American Dental Association.

Each tooth has several components. The exposed portion in the oral cavity is called the crown, and that embedded within the bony socket is called the root. The crown is covered by enamel that is densely radio-opaque and is of higher attenuation than cortical bone. On the contrary, the root is covered by a thin layer of dense cementum. The junction where the crown and root meets is referred to as the cervical constriction or the cementoenamel junction.

There are five free surfaces on each crown: occlusal surface, the inner surface (palatal surface in the maxilla and lingual surface in the mandible), the outer or facial surface (labial surface for incisors and canines, buccal surface for premolars and molars), and the two contact surfaces with the neighbouring teeth (Figure 2).

Deep to the enamel is the dentine, the component that makes up most of the tooth and envelops the pulp chamber and root canal. Dentine is isodense to cementum, and both are less radio-opaque than enamel. At the centre of the tooth is the relatively radiolucent pulp chamber that contains the neurovascular bundles that enter the tooth via the apical foramen located at the root apex.

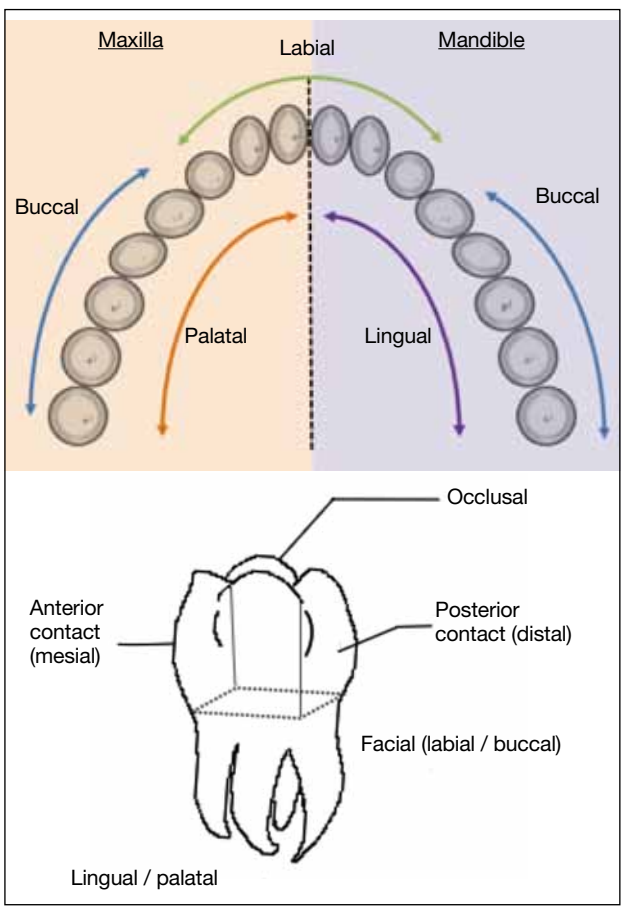

Figure 2. Schematic drawings illustrating crown surfaces.

The bony tooth sockets are lined by lamina dura that provides attachment for the periodontal ligaments. The periodontal ligaments are highly specialised structures that hold the teeth in place within the bony sockets and at the same time allow small degrees of tooth movement. They appear as radiolucencies between the cementum and the lamina dura. A normal periodontal space measures between 0.1 mm and 0.2 mm in width and is not visualised on computed tomography (CT). Any expansion of this space indicates an underlying pathological process.[1,2,4,5]

INFLAMMATION AND INFECTION

Dental inflammation or infection is frequently encountered in daily practice, either as an incidental finding or as the underlying cause of a patient's presenting symptoms. It may be endodontal or periodontal.

Endodontal Disease

Endodontal disease refers to erosion and cavitation of the crown of an erupted tooth due to demineralisation of enamel and dentin by the acidic metabolic products of carbohydrate-fermenting bacteria.

All dental caries start at the tooth surface and gradually erode through the enamel to reach the dentin and tooth pulp, forming a carious lesion. They occur more often at the occlusal and contact surfaces, ie, the chewing surfaces and in between the teeth.

On imaging, carious lesions appear as focal areas of enamel and dentin loss extending from the surface of the tooth. The enamel lesions may not be evident until 30% to 40% demineralisation has occurred. An early carious lesion can be fissural (Figure 3), triangular or mushroom-shaped in appearance. The narrow stalk of the 'mushroom' locates at the enamel, while the larger 'mushroom cap' represents the area within dentin and is less resistant to demineralisation (Figure 4). A typical carious lesion of the enamel is a triangular lucency with a broad base at the tooth surface. Other common appearances include a notch, rod-shaped or linear lucencies.[1,2,6]

Carious lesions are most commonly seen on the occlusal surfaces. Those that occur at the contact surfaces are referred to as an interproximal carious lesion, either mesial (anterior) or distal (posterior). Recurrent caries refers to caries formed after dental restoration.[1]

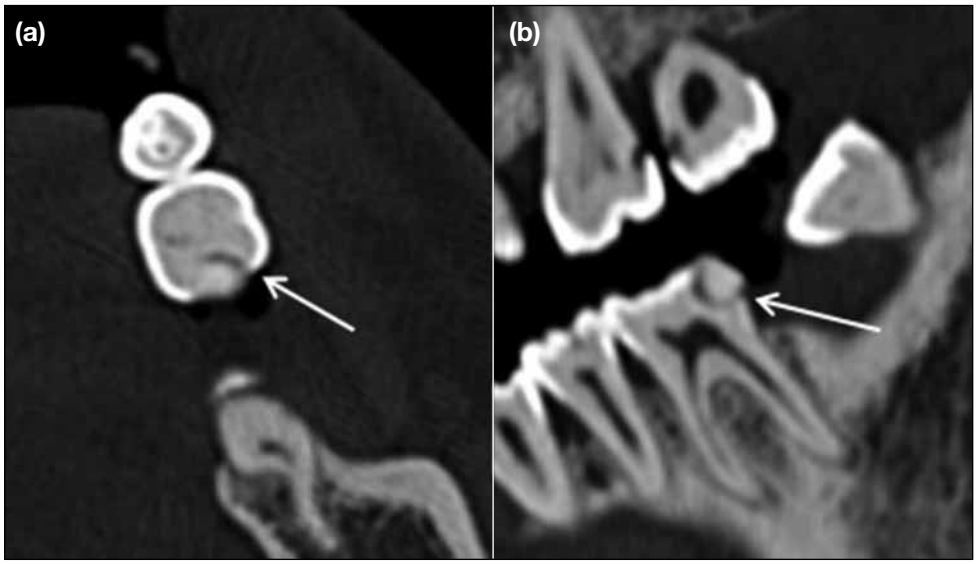

Figure 3. Early endodontal disease. (a) Axial and (b) oblique sagittal computed tomographic images showing lucent fissure over the left mandibular molar extending from occlusal to posterior contact surfaces (arrows). Small distal interproximal lesions are also seen over the maxillary molars.

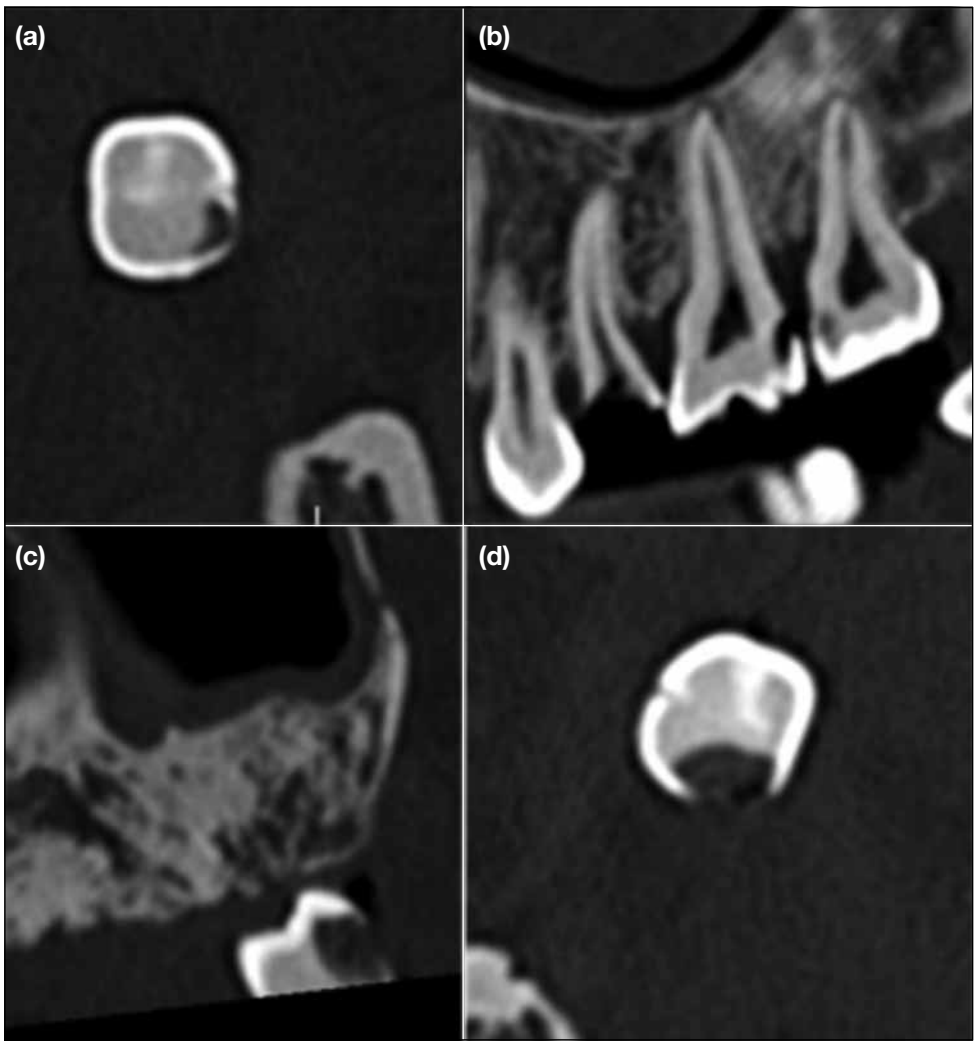

Figure 4. Endodontal disease. (a) Axial computed tomographic (CT) image showing inverted triangular lucency over the crown of a left maxillary molar. (b) Oblique sagittal CT image of the same patient showing carious lesions involving several maxillary teeth, with erosion of most of the premolar crown. (c) Oblique sagittal and (d) axial CT images of another patient with edentulous maxilla showing presence of a mushroom-shaped carious lesion over the dorsal contact surface of a mandibular molar, with larger area of demineralisation in the dentin than in the enamel.

Periodontal Disease

Periodontal disease refers to inflammation of the tooth socket and usually begins with gingivitis and dental plaque accumulation. As plaque accumulates, it invades the periodontal ligament space causing a deepened gingival sulcus. Infection then spreads along the periodontal ligament and is followed by an inflammatory cascade with consequent destruction of the periodontal ligament, ulceration of the pocket epithelium, and resorption of the supporting bone of the tooth. Eventually tooth loosening and uncovering of the root ensue.[4,6]

On imaging, periodontal disease appears as widened lucent periodontal spaces that are normally not well visualised on CT. As infection progresses, uncovering of the root and increased bone loss are observed.

Pericoronitis is a distinct subtype of periodontitis and refers to inflammation of the gingiva around the crown that is usually a partially erupted tooth and is commonly seen affecting the third mandibular molar.[4]

Complications of Periodontal and Endodontal Diseases

Sometimes, a focal periapical lucency is seen in cases with periodontitis or severe endodontal disease and can be a periapical granuloma, cyst, or abscess. These differential diagnoses form a spectrum of the same pathological process.

A periapical cyst forms when inflammation causes proliferation of epithelial rests within the periodontal ligament, resulting in an epithelial-lined cavity and resorption of the surrounding bone. Alternatively, the inflammation may progress from a carious lesion through the tooth pulp to the root. A periapical cyst is a chronic process that demonstrates well-defined sclerotic borders. It usually appears as round or pear-shaped lucency around the tooth root, with a target-like appearance on axial imaging with the root apex in the centre. Smaller lesions appear as crescent-shaped lucencies capping the root apex. They are commonly <1 cm in diameter (Figure 5). Periapical granulomas are an early form of periapical cyst and as such are smaller in size with ill-defined borders (Figure 6).

Periapical abscess (or phlegmon) results when a periapical granuloma or cyst becomes infected. They appear as periapical lucencies with ill-defined borders. Associated soft tissue inflammation or bone marrow signal changes may also be seen (Figure 7).

In severe cases of periodontal disease, further progression of infection involving the maxillary sinuses can lead to odontogenic sinusitis (Figure 8); extension to the alveolar process of the maxilla or mandible can cause osteomyelitis (Figure 9), or even extend through the lingual cortex to involve the deep spaces of the neck with abscess formation.

ODONTOGENIC CYSTS

Odontogenic cysts refer to cysts of the jaw arising from tooth derivatives. They are classified as developmental or inflammatory.

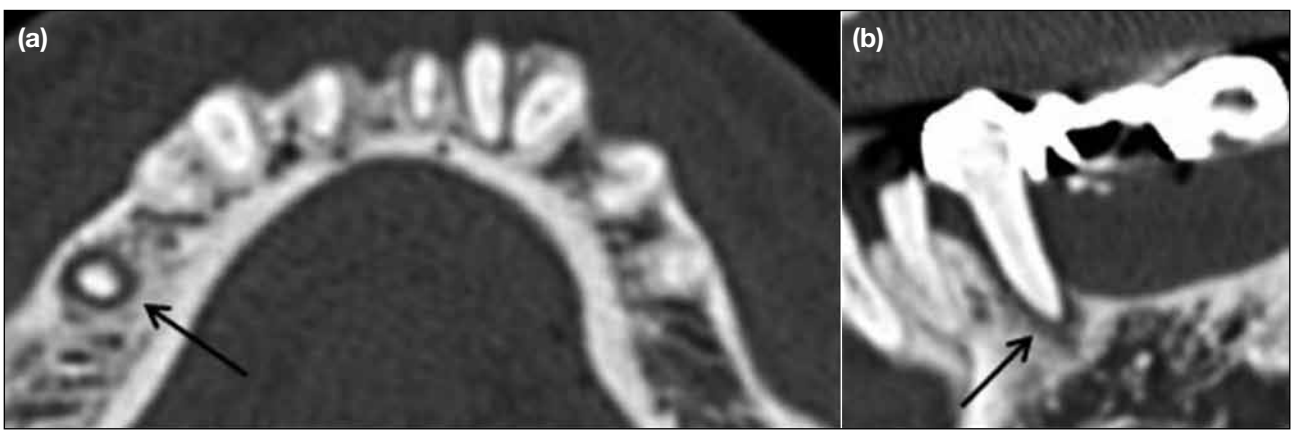

Figure 5. Apical periodontitis. (a) Axial and (b) oblique sagittal computed tomographic images showing widened periodontal lucency over the right mandibular first premolar with a target-like appearance (arrows), which separates the root of the tooth from the lamina dura (compared with the normal relationship of roots of teeth and lamina dura of the other included teeth).

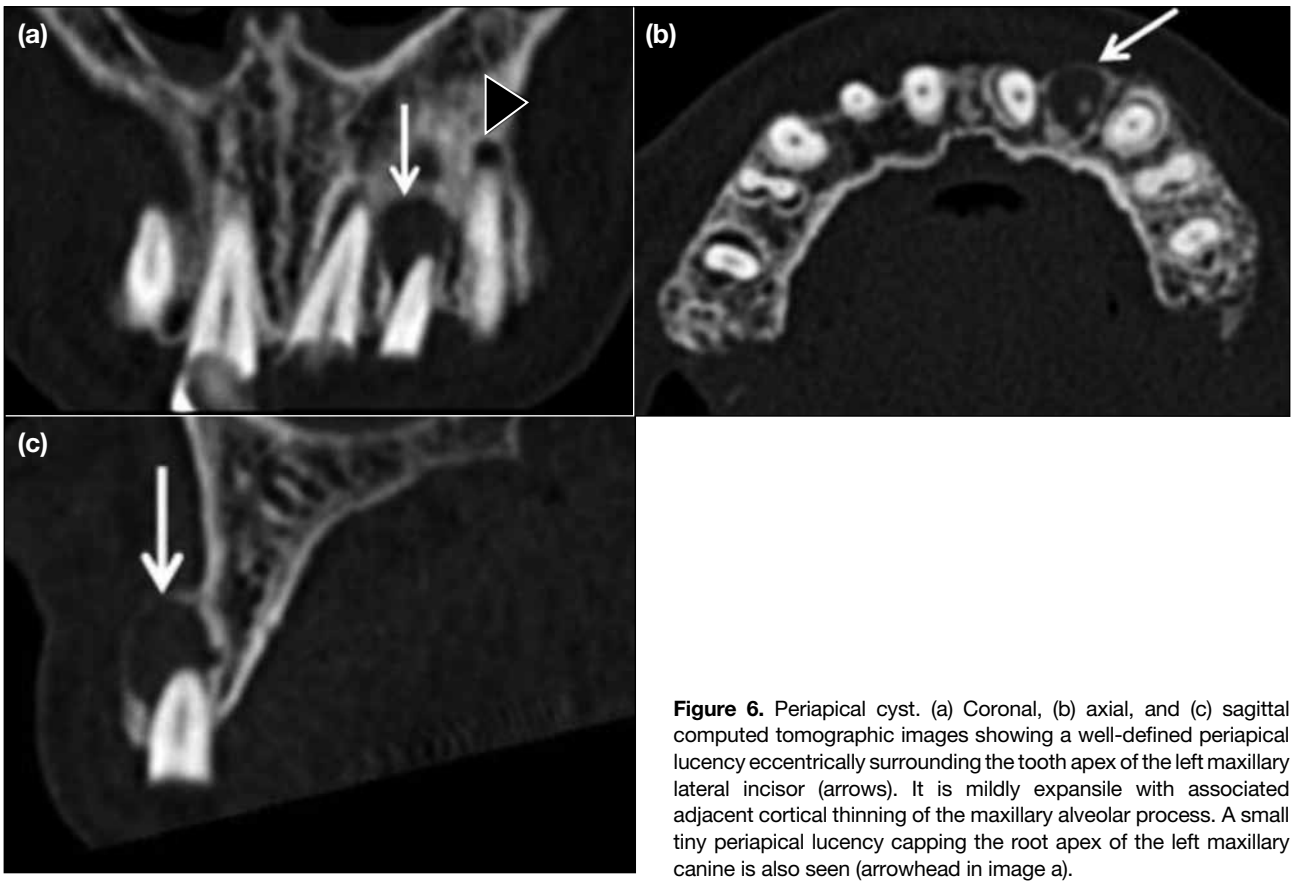

Figure 6. Periapical cyst. (a) Coronal, (b) axial, and (c) sagittal computed tomographic images showing a well-defined periapical lucency eccentrically surrounding the tooth apex of the left maxillary lateral incisor (arrows). It is mildly expansile with associated adjacent cortical thinning of the maxillary alveolar process. A small tiny periapical lucency capping the root apex of the left maxillary canine is also seen (arrowhead in image a).

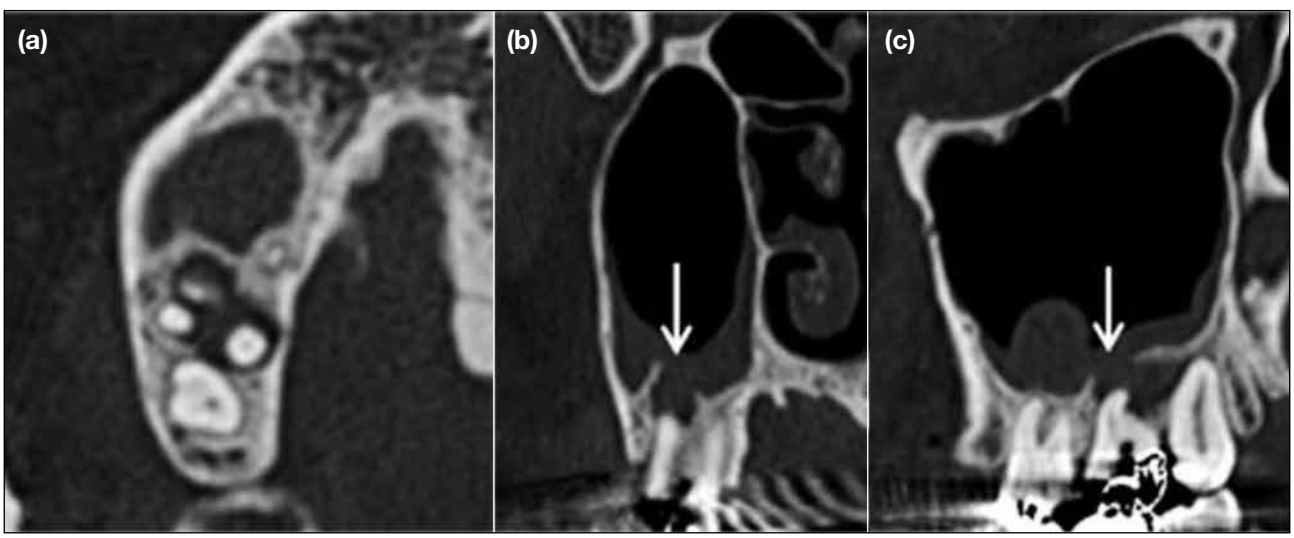

Figure 7. Periapical abscess with odontogenic sinusitis. (a) Axial, (b) coronal, and (c) sagittal computed tomographic images showing an irregular periapical lucency with surrounding bony sclerosis over the right maxillary second molar. It shows mildly ill-defined borders with erosion of the floor of the right maxillary sinus (arrows), showing mucosal thickening, suggesting odontogenic sinusitis.

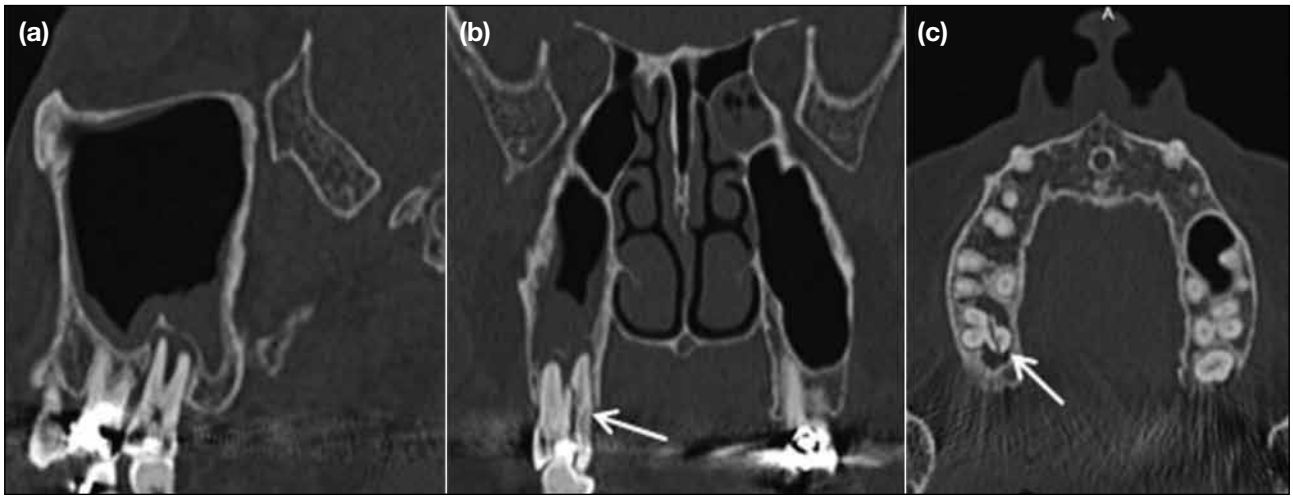

Figure 8. Periodontal disease complicated by root fracture and odontogenic sinusitis. (a) Sagittal, (b) coronal, and (c) axial computed tomographic images showing periapical lucency of the right maxillary molar suggesting periapical disease, with a lucent fracture line across the tooth root (arrows). Mucosal and wall thickening of the right maxillary sinus are also seen.

Figure 9. Periodontal disease complicated by osteomyelitis. (a) Orthopantogram showing subtle ill-defined sclerosis over the right posterior mandibular body (arrows), with internal irregular lucent tract (arrowheads). (b) Contrast computed tomographic (CT) image showing periapical lucency with surrounding sclerosis of the right second mandibular molar, suggestive of apical periodontal disease. (c) A radiolucent sinus track extends from the periapical lucency to the buccal cortex of mandibular body. (d) Contrast CT image in soft tissue window showing soft tissue densities extending to the skin surface (arrow).

Periapical (Radicular) Cyst

Periapical cyst is the most commonly encountered odontogenic cyst and its pathogenesis has been described above. It has a slight male predominance and can be seen at any age although more often between the ages of 30 and 50 years. Apart from dental caries, it may also occur following trauma. A large periapical cyst can cause tooth resorption, cortical expansion, or displace adjacent teeth or mandibular canal (Figure 10). Rim enhancement is seen in infected cysts. Treatment is directed to the underlying carious lesion.[1,5]

Residual Cyst

Residual cyst is a common subtype of periapical cyst and refers to a retained cyst after dental extraction. Radiologically, it appears similar to periapical cysts, except that there is always a missing tooth. It is usually small (<1 cm) in size but can occasionally enlarge with bony expansion or cause mass effect on adjacent teeth.[1]

Dentigerous (Follicular) Cyst

Dentigerous or follicular cysts are the second most common odontogenic cyst, commonly seen in the third to fourth decades. It is a benign non-inflammatory odontogenic cyst, believed to be developmental in origin, and develops when fluid collects between the epithelial layers or between epithelium and enamel. A normal follicle space is 2 to 3 mm wide; if it is wider than 5 mm, a follicular cyst is to be suspected.

Radiologically, dentigerous cysts are well-circumscribed unilocular lucent lesions with an associated fully formed crown of an unerupted tooth. The roots of the tooth are typically located outside the cyst. They may vary in size. Larger ones may show undulating borders and have the potential to cause bony expansion and displacement of teeth. In contrast to periapical cysts, they are not commonly associated with root resorption (Figure 11). Complicated cysts may be seen in cases with superimposed infection or pathological fractures. Bilateral lesions may be seen in association with a syndrome such as mucopolysaccharidosis (type 4) and cleidocranial dysostosis.

Treatment is usually enucleation of the cyst although larger ones may require drainage or marsupialisation for relief of pressure.[1,5]

Differentials of Odontogenic Cysts

Several other non-odontogenic lesions, although less often seen, may also cause radiolucent lesions of the jaw and should be considered in the differentials.

Incisive canal cysts (nasopalatine duct cysts) are the most

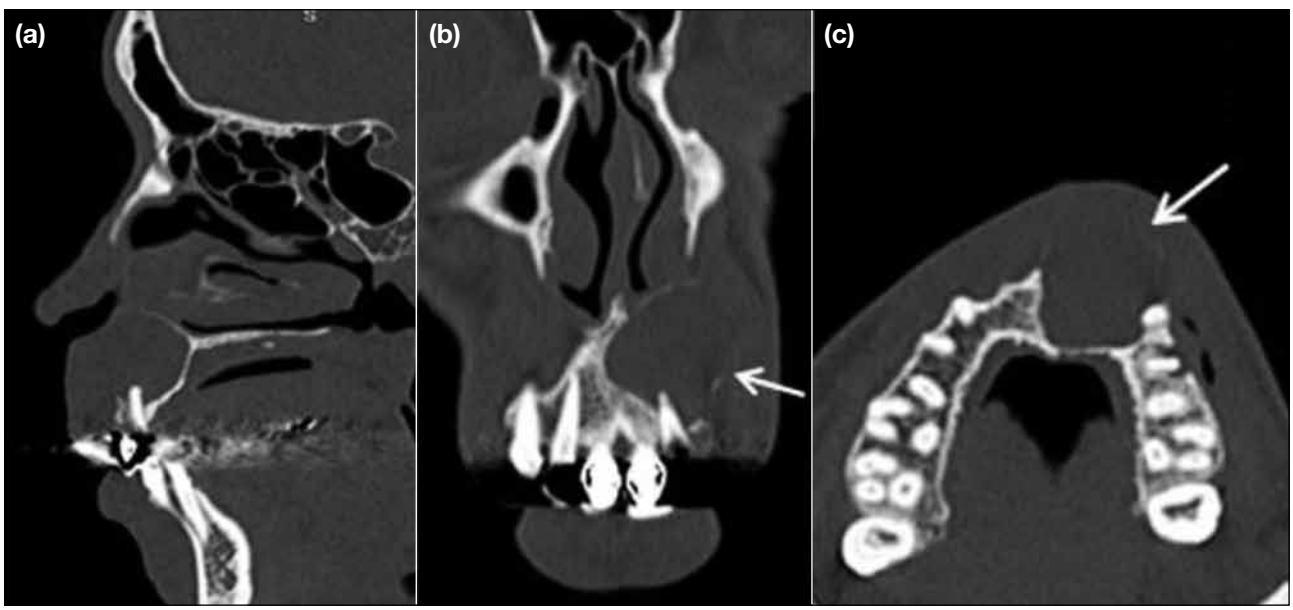

Figure 10. (a) Sagittal, (b) coronal, and (c) axial computed tomographic images showing a unilocular expansile radiolucent lesion over the left anterior maxillary alveolar process, surrounding the root of the left maxillary canine. Associated cortical thinning and superior extension to the floor of left nasal cavity is noted. The lesion was surgically proven to be a periapical (radicular) cyst (arrows).

common non-odontogenic cyst. They are developmental cysts that occur due to cystic degeneration of the residual ductal epithelium of nasopalatine ducts. They locate over the anterior midline between the central incisors, and appear as solitary well-defined, oval or round unilocular lucency (Figure 12).[1]

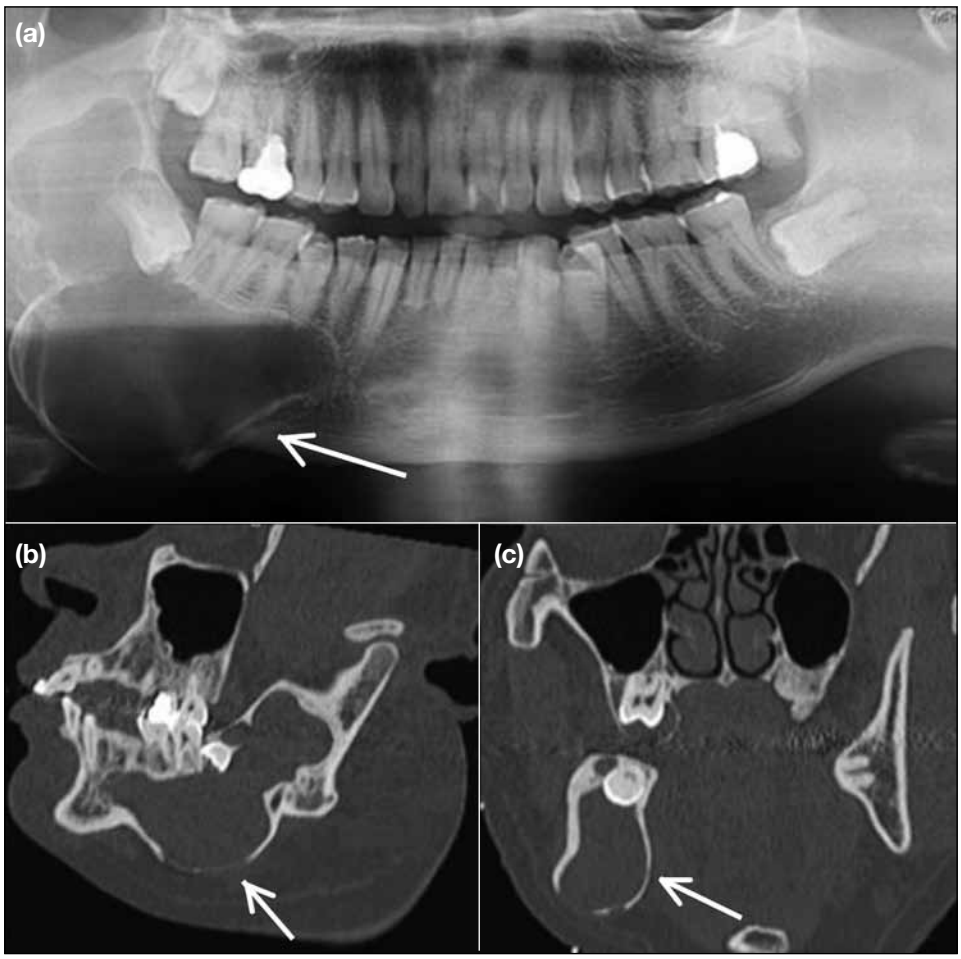

Figure 11. Dentigerous cyst. (a) Orthopantogram, (b) oblique-sagittal, and (c) oblique-coronal computed tomographic images in bone window showing a large unilocular cyst (arrows) with undulating borders over the right mandibular body, surrounding the crown of an unerupted right maxillary molar. Associated bony expansion and cortical thinning are observed.

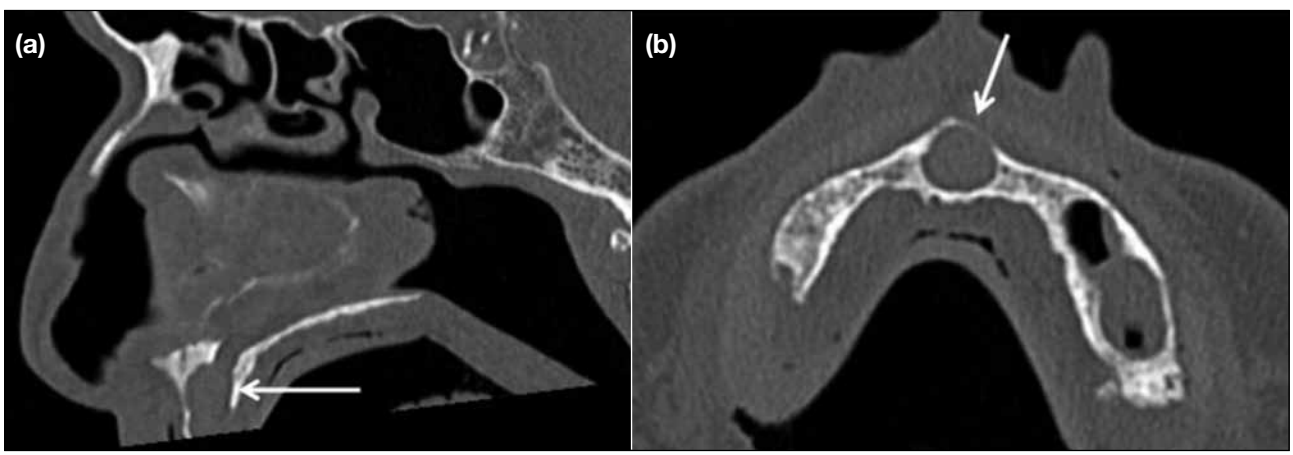

Figure 12. (a) Sagittal and (b) axial computed tomography in bone window of an edentulous patient showing a well-defined unilocular oval lucency (arrows) over the anterior midline along the nasopalatine duct, suggestive of incisive canal cyst.

Stafne cyst (static bone cavity), though not a true cystic lesion, is another differential for a solitary ovoid radiolucent lesion in the mandible. It is in fact a cortical defect over the lingual surface of the mandible. Radiologically, they are small with a well-defined sclerotic border and locate below the inferior alveolar canal. Typically, the cavity contains the herniated submandibular gland and remains static in size over time (Figure 13).[1,7]

Aneurysmal bone cyst is a benign bone lesion characterised by blood-filled spaces lined by epithelium, containing immature connective tissue, osteoid, and inflammatory cells. Patients usually present with painless and rapid progressive facial swelling. On imaging, these lesions are often multiloculated with internal fluid-fluid levels; areas of bony destruction may also be present.[1]

ODONTOGENIC NEOPLASMS

Odontogenic tumours occur when there is abnormal proliferation of odontogenic cells and are classified according to stage of tooth development.[1,6] Most are cystic in appearance, and differentiation between benign and malignant lesions can be difficult. One of the key distinguishing features is the presence of pressure-related directional root resorption in benign lesions, while root resorption in malignant lesions is non-directional.[8]

Keratocystic Odontogenic Tumour

Formally known as odontogenic keratocyst (OKC),

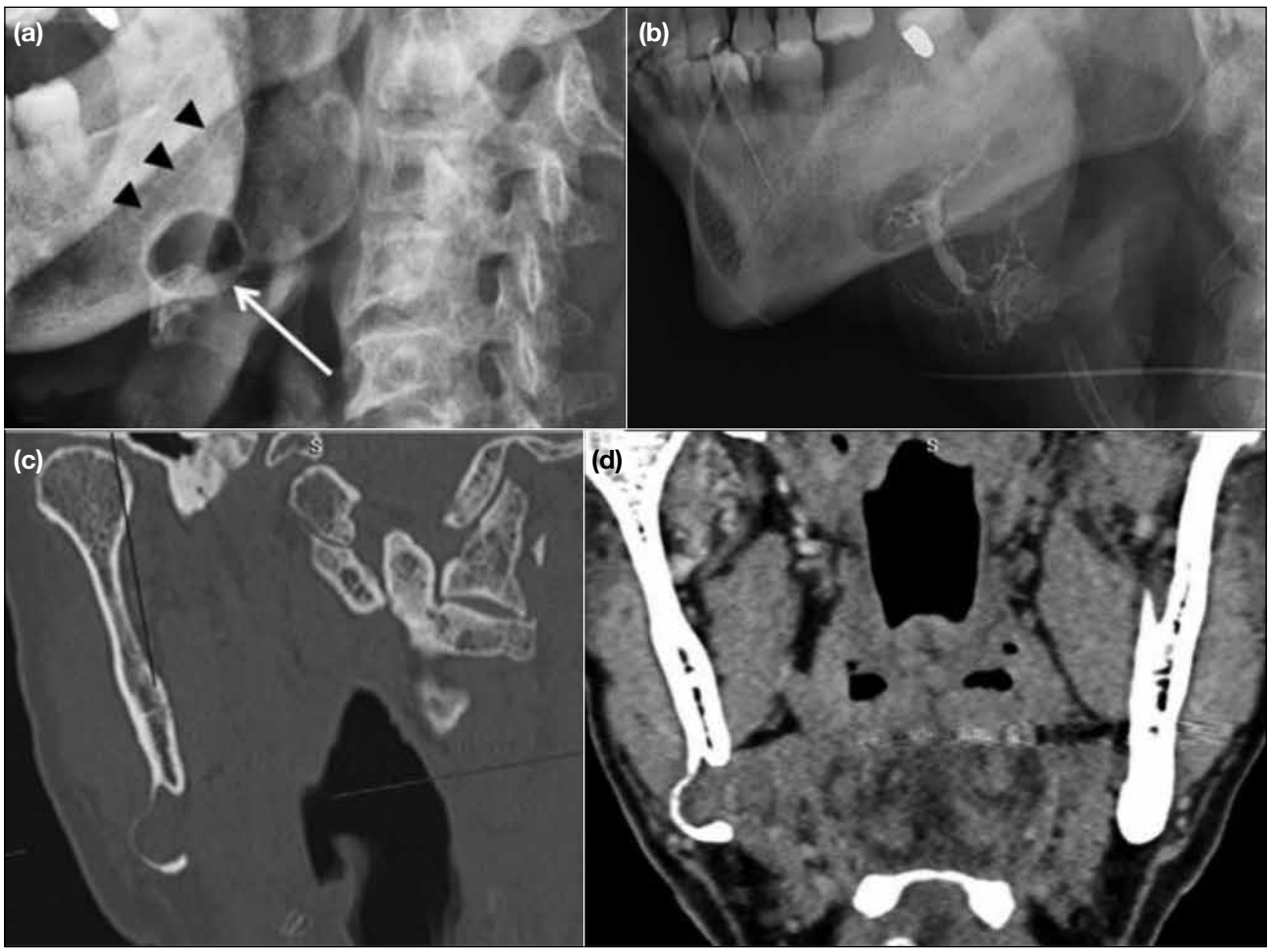

Figure 13. Stafne cyst. (a) Radiograph of the right mandible showing an oval lucent lesion (arrow) with sclerotic rim located over the right posterior mandibular body below the inferior alveolar canal (arrowheads). (b) Sialography showing opacification of the right Wharton's and accessory ducts, which extend into the mandibular body lesion. Contrast computed tomographic images of (c) bone and (d) soft tissue windows showing the cortical defect over lingual side of the right mandibular body, extending to the buccal side with cortical thinning and bony scalloping. Herniation of the adjacent right submandibular gland into the defect is observed.

keratocystic odontogenic tumour is now re-classified as an odontogenic tumour rather than a cyst. It is found at all ages but typically in the second to fourth decade of life.[6]

It is lined by a thin layer of stratified keratinising squamous epithelium, usually six to eight cell layers thick, with parakeratin-type keratinisation. They arise from the dental lamina and overlay the alveolar mucosa.[7]

OKC is a benign but locally aggressive lesion with a high recurrence rate reported to be between 20% and 60%. They are commonly located at the body or ramus of the mandible.

Radiologically, OKC can be unilocular or multilocular in appearance, with daughter cysts commonly seen. It typically shows smooth and thin borders with bony expansion. Pressure effect causing adjacent teeth or mandibular canal displacement, root resorption, and cortical erosion may be observed. It contains heterogeneous contents but on contrast scan, there should be no enhancement demonstrated, distinguishing it from the more aggressive ameloblastoma (Figures 14 and 15).

Ameloblastoma

Ameloblastoma is the second most common odontogenic tumour, with a benign but locally aggressive nature. It frequently arises from ameloblasts, the enamel-forming cells of the odontogenic epithelium which failed to regress during embryonic development. Nonetheless it may also arise from the pluripotential epithelial cells lining the odontogenic cysts, in which associated dentigerous cyst is found.[5]

Figure 14. A patient with known Gorlin-Goltz syndrome presented with two expansile radiolucent lesions with cortical thinning over the bilateral maxillary alveolar processes (arrows) that were histologically proven to be keratocyst odontogenic tumours.

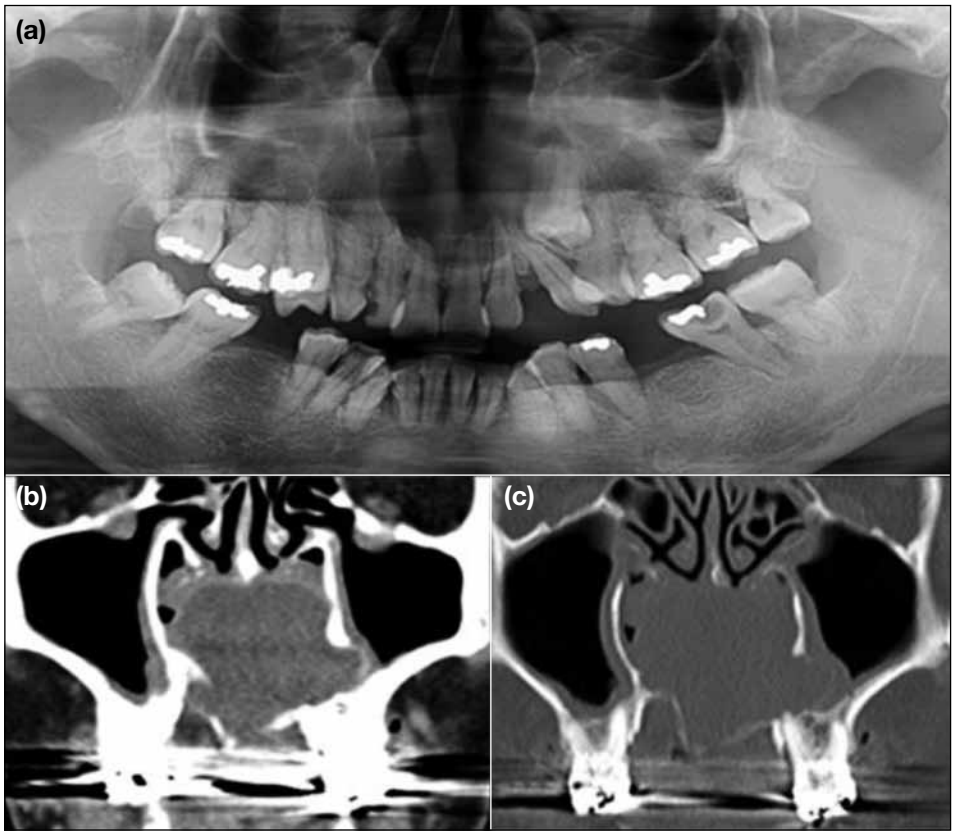

Figure 15. (a) Orthopantogram showing a large multiloculated radiolucent expansile lesion with smooth sclerotic borders over the midline maxillary alveolus. (b and c) Contrast computed tomography in soft tissue and bone windows. The lesion demonstrates the adjacent bone remodelling and internal cystic non-enhancement contents. Features are consistent with keratocystic odontogenic tumour.

Ameloblastomas usually present in adults in the third to fifth decade of life as slow-growing painless masses or local swelling.[9] They are more frequently found in the mandible than in the maxilla, with a ratio of approximately 4:1. The most commonly affected site is at the mandibular angle in the region of the third molar, while in the maxilla, the majority of tumours (90%) involve the premolar-molar area.[1]

On CT, ameloblastomas are expansile and cystic in appearance, with internal scattered soft tissue components. Erosion of the cortex or roots of adjacent teeth may be present. More aggressive features including large solid enhancing components, papillary projections and extraosseous extension are seen in cases with malignant transformation. Nonetheless only histopathological findings can help determine benignity and the absence of carcinomatous change.[5]

Four main types of ameloblastomas are classified based on their clinical behaviour, location, radiological appearance and histopathological characteristics: unicystic, solid (multicystic), desmoplastic, and peripheral (extraosseous).[1]

The solid or multicystic type is the most frequently encountered subtype (85%), and is also the most aggressive variant with a high recurrence rate. They are classically multiloculated with well-circumscribed borders and internal septations, giving a 'soap-bubble' appearance. Internal calcification is usually not seen (Figure 16).[10]

Odontogenic Myxoma

Odontogenic myxoma is a rare true odontogenic tumour, indistinguishable from ameloblastoma, both clinically and radiographically. This tumour is benign but locally very aggressive and rapidly growing. It appears as a multiloculated radiolucent lesion with internal bony trabeculae. The borders can be well- or ill-defined, and extension through the cortex to adjacent soft tissues may be present. Due to the locally aggressive nature, wide en bloc resection is the treatment of choice.[1,7]

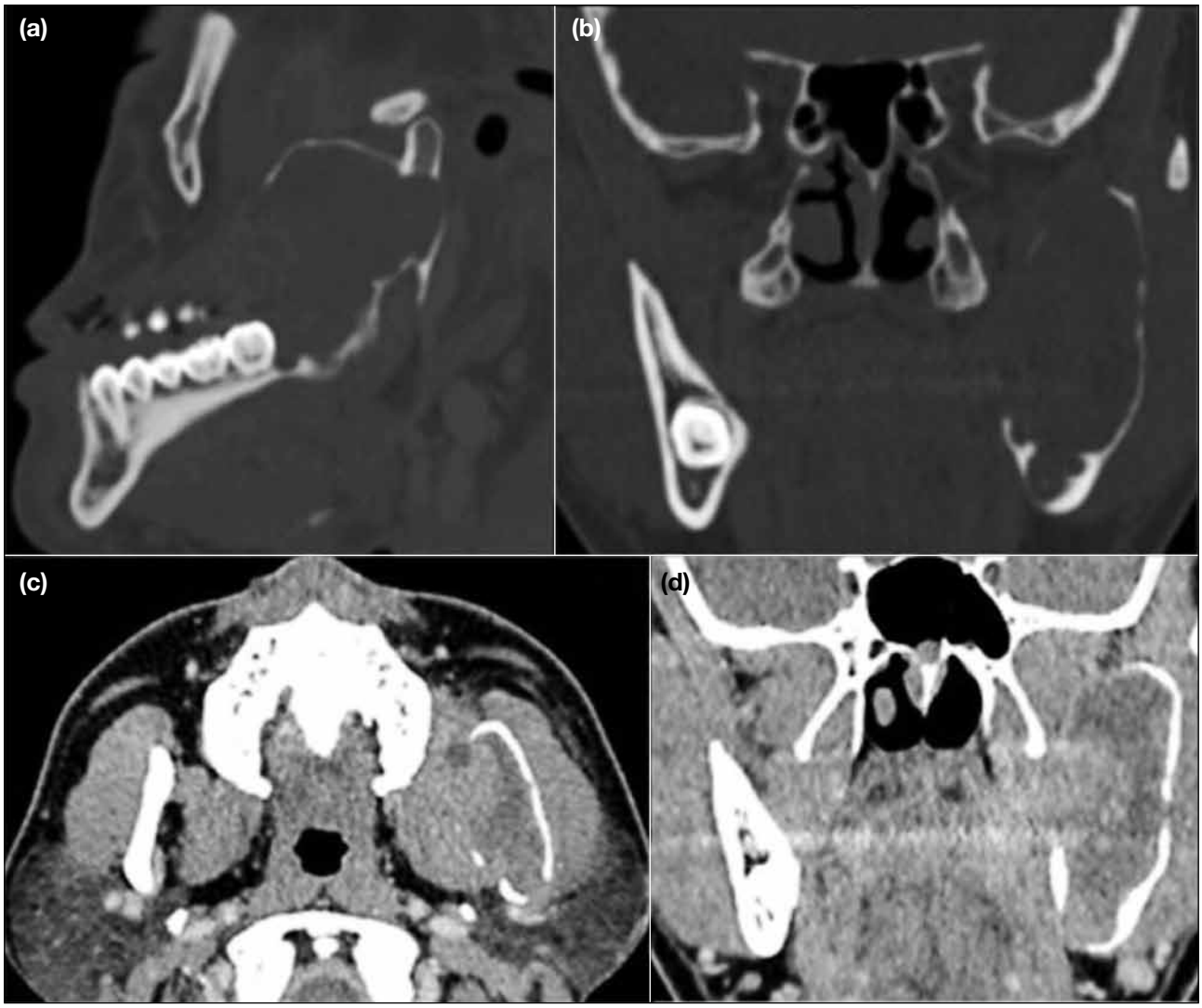

Figure 16. Computed tomographic images in (a and b) bone window and (c and d) soft tissue window showing a multiloculated expansile radiolucent lesion over the left mandibular ramus with cortical thinning with internal solid enhancing component, consistent with multicystic-type ameloblastoma.

Odontoma

Odontoma is the most common odontogenic tumour of the mandible. It is a benign tumour composed of different elements of teeth (eg, enamel, dentin, cementum, pulp), forming a hamartomatous lesion. It is initially radiolucent with progressive calcification, and eventually forms a radiopaque mass with lucent rim. It is usually located between the roots of teeth and an associated impacted tooth is seen in about half of cases.

It is further divided into two subtypes based on its composition compared with normal teeth: compound and complex. A compound odontoma contains identifiable tooth components, whereas a complex odontoma contains dental tissue with amorphous calcifications (Figure 17).[1,7]

Ameloblastic Fibro-odontoma

An ameloblastic fibro-odontoma (AFO) is a rare slow-growing benign lesion with the combined characteristics of ameloblastoma and composite odontoma (ie, enamel and dentine-containing). It is more prevalent in children and often occurs in the molar-premolar area with associated developing teeth. On imaging, it typically appears as a solitary lucent lesion with well-defined margins containing various amounts of radiopaque

densities that resemble miniature teeth. Associated unerupted tooth is often seen. AFO is usually treated by surgical enucleation (Figure 18).[1]

DEVELOPMENTAL ABNORMALITIES

There are various abnormalities of tooth development, including abnormal number (supernumerary, hypodontia, anodontia), abnormal shape or size (fused teeth, macrodontia, microdontia), and faulty development of dentin and enamel, resulting in teeth malalignment, malocclusion, or ectopic eruption of normal teeth.

Supernumerary Teeth

Supernumerary teeth refers to additional number of teeth in a dentition and occurs in 1% to 4% of the population. A supernumerary tooth can be seen in isolation, or as part of the manifestation of a syndrome such as Gardner's syndrome or cleidocranial dysostosis (Figure 19). It is more commonly seen in the permanent dentition, and the additional tooth is usually smaller than the remaining normal teeth with abnormal orientation. Nomenclature of the supernumerary tooth is according to its location: 'mesiodens' in the anterior maxilla, and 'distomolar' or 'distodent' in the retromolar area. Description of the supernumerary tooth also includes its orientation: 'palatal' and 'buccal' orientations refer to the tooth facing the hard palate or the buccal mucosa, respectively. Accurate reporting is important in preoperative imaging for planning of treatment.[11,12]

Hypodontia

Fewer than the normal number of teeth is termed 'hypodontia' and is present in the permanent dentition of 5% to 10% of the population. The commonly affected teeth are the third molars, mandibular second premolars, and maxillary lateral incisors. Similar to supernumerary teeth, it can occur in isolation or as part

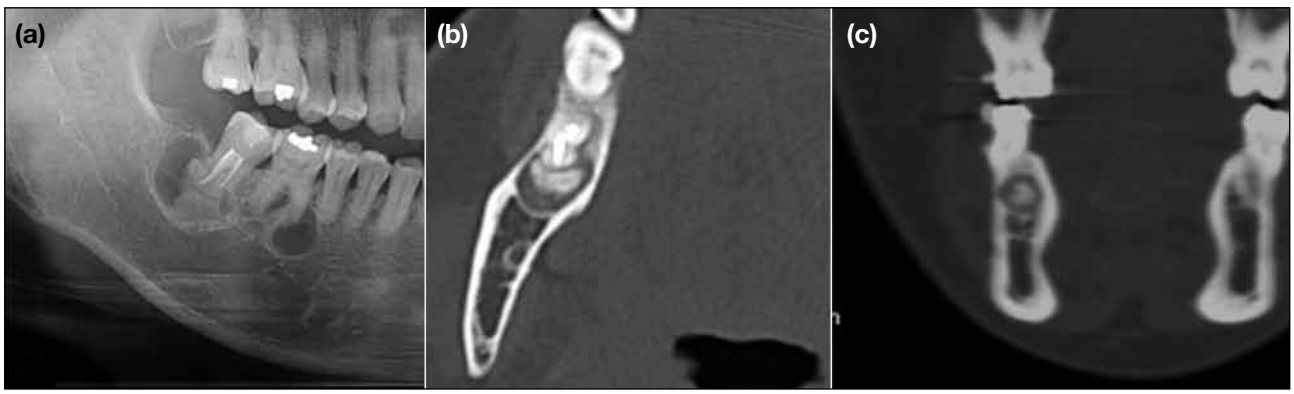

Figure 17. Odontoma. (a) Orthopantogram showing two well-defined lucent lesions in the right mandible adjacent to roots of molars. (b) Axial computed tomography (CT) of the posterior lesion and (c) coronal CT of the anterior lesion demonstrate the internal radiopaque densities, with possible tooth-like appearances.

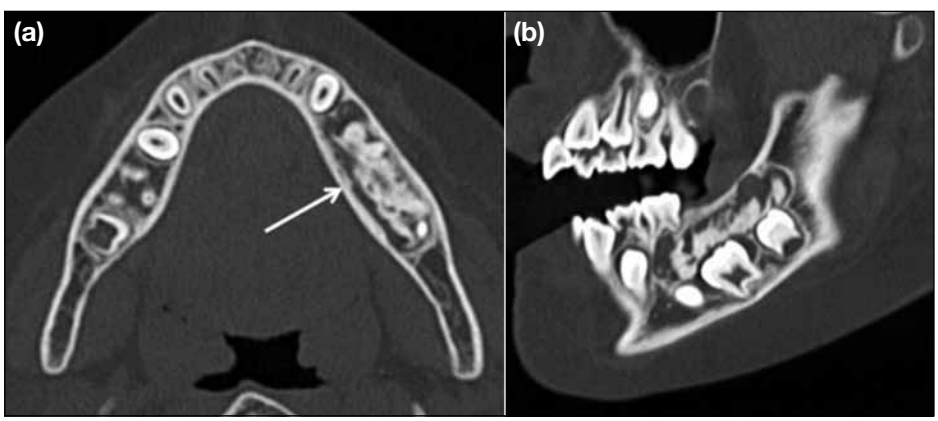

Figure 18. Ameloblastic fibro-odontoma. (a) Axial and (b) oblique-sagittal computed tomographic images of bone window showing a solitary well-defined lucent lesion over the left mandibular body in the premolar-molar region, containing radiopaque densities. Associated unerupted molars are noted.

of an associated disorder, including ectodermal dysplasia and epidermolysis bullosa, or related to prior irradiation treatment.[13]

Ectopic Tooth

Ectopic tooth eruption in the maxillofacial region, aside from the dental region of the jaw, is rare. There have been some reports of non-dentate region ectopic eruption. Ectopic sites include the nasal septum, mandibular condyle, coronoid process, palate, maxillary sinus, and orbit (Figure 20). Most patients are asymptomatic, but occasionally the ectopic tooth may cause symptoms such as chronic or recurrent sinusitis, nasolacrimal duct obstruction, facial swelling, and ophthalmic symptoms.

Owing to their rare occurrence, there is a lack of consensus about appropriate management. Surgical treatment is recommended for symptomatic patients.[14,15]

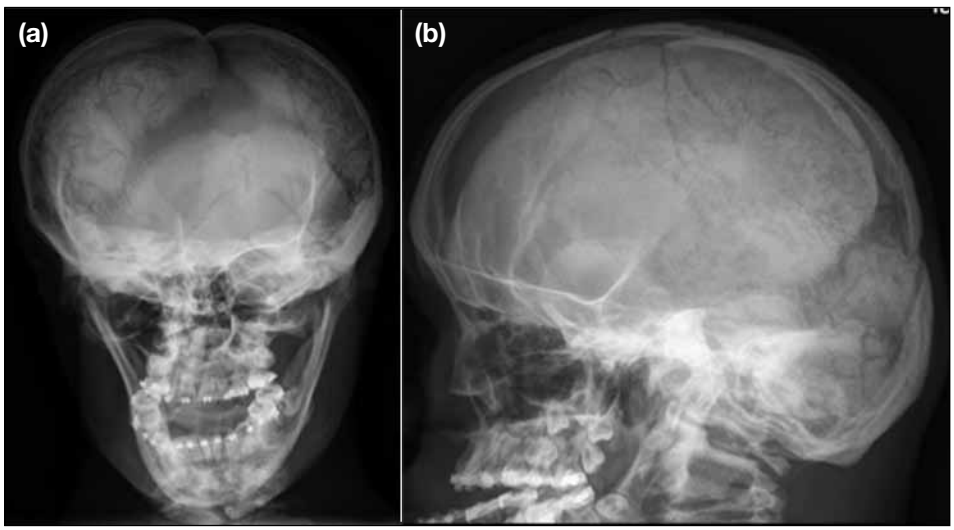

Figure 19. (a) Frontal and (b) lateral skull radiographs of a 24-year-old patient with known cleidocranial dysostosis showing presence of supernumerary teeth. There is also an enlarged cranium with unfused sagittal and lambdoidal sutures, widened fontanelles, wormian bones, and midface hypoplasia.

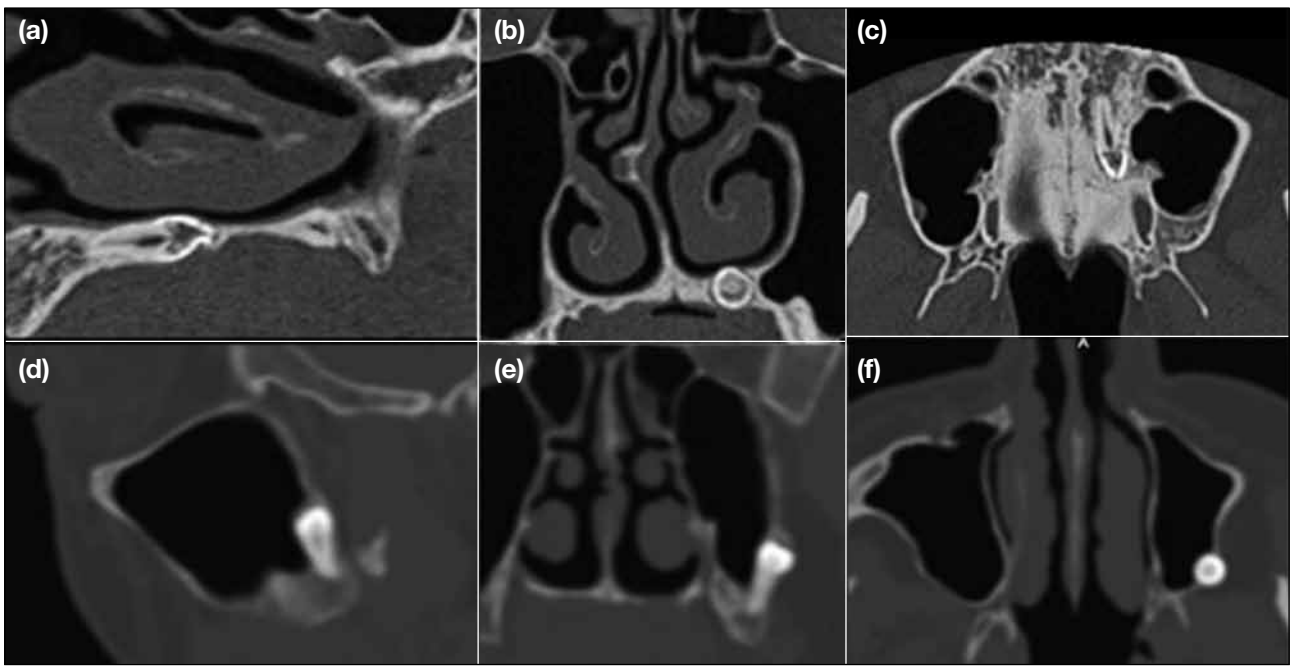

Figure 20. (a) Sagittal, (b) coronal, and (c) axial computed tomographic (CT) images showing an ectopic palatal tooth. The ectopic left canine is embedded within the hard palate with the cusps pointing posteriorly. (d) Sagittal, (e) coronal, and (f) axial CT images showing an ectopic tooth located at the left maxillary sinus, lying along its posterolateral wall.

TRAUMA

Although dental trauma is commonly diagnosed by clinical examination and may not necessitate imaging, it is frequently overlooked by radiologists in the setting of facial or multiregional trauma where imaging has been performed (Figure 21).

Dental trauma can be broadly classified into injury of tooth, and injury of the supporting soft tissues or bony structures. Further descriptions of the subtypes of injuries are listed in Tables 1 and 2.[16]

The major role of radiologists in dental trauma is to

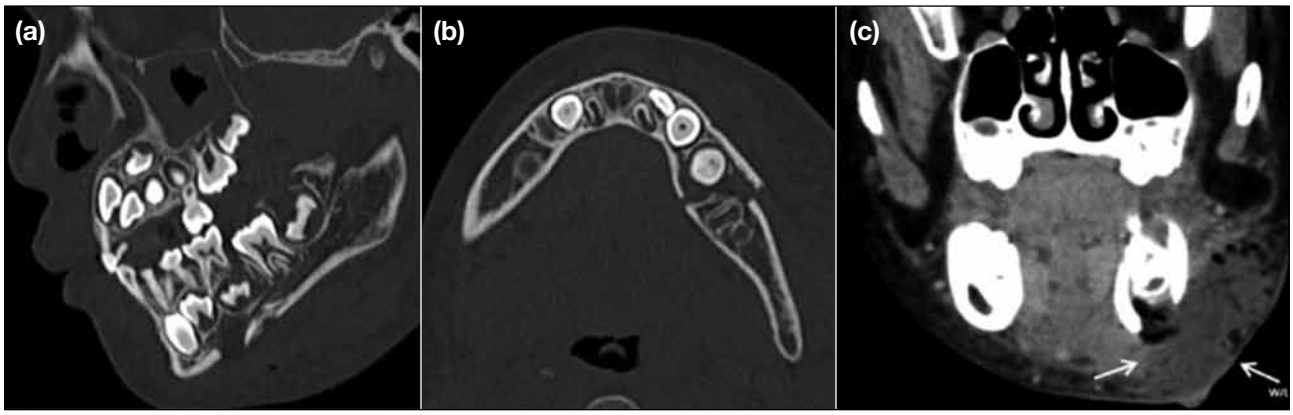

Figure 21. (a) Sagittal and (b) axial computed tomographic (CT) images in bone window showing an open fracture across the left mandibular body in a paediatric patient, involving the tooth socket of the primary first molar and the underlying developing tooth bud of the permanent molar. (c) Coronal contrast CT image in soft tissue window of the same patient 2 weeks later showing complication with abscess formation (arrows). Eruption of the affected molar in this patient could be affected (eg, delayed, non-eruption).

Table 1. Traumatic injuries to tooth.[16]

Type of injury	Feature
Enamel infraction	An incomplete fracture (crack) of the enamel without loss of tooth substance.
Enamel fracture	(Uncomplicated crown fracture) A fracture with loss of enamel only.
Enamel-dentine fracture	(Uncomplicated crown fracture) A fracture with loss of enamel and dentin, but not involving the pulp.
Complicated crown fracture	A fracture involving enamel and dentin with exposure of the pulp.
Crown-root fracture	A fracture involving enamel, coronal and radicular dentin, and cementum.
Root fracture	A fracture involving radicular dentin, cementum, and the pulp. Root fractures can be further classified according to displacement of the coronal fragment.
Luxation injuries	Concussion: An injury to the tooth-supporting structures without abnormal loosening or displacement of the tooth, but with increased reaction to percussion. Subluxation (loosening): An injury to the tooth supporting structures with abnormal loosening, but without displacement of the tooth. Extrusive luxation (peripheral dislocation, partial avulsion): Partial displacement of the tooth out of its socket. Lateral luxation: Displacement of the tooth in a direction other than axially. This is accompanied by comminution or fracture of the alveolar socket. Intrusive luxation (central dislocation): Displacement of the tooth into the alveolar bone. This injury is accompanied by comminution or fracture of the alveolar socket. Avulsion (exarticulation): Complete displacement of the tooth out of its socket.

Table 2. Soft tissue and bony injuries.[16]

Type of injury	Feature
Gingiva or oral mucosa	Laceration: Shallow or deep wound in the mucosa resulting in a tear, usually produced by a sharp object. Contusion: Bruise usually produced by impact with a blunt object causing submucosal haemorrhage, not accompanied by mucosal break. Abrasion: A superficial wound produced by rubbing or scraping of the mucosa, leaving a bleeding surface.
Fracture of the mandibular or maxillary alveolar socket wall	A fracture of the alveolar process which involves the alveolar socket.
Fracture of the mandibular or maxillary alveolar process	A fracture of the alveolar process that may or may not involve the alveolar socket.

provide timely diagnosis, and accurate localisation and description of the injuries to facilitate early tooth re-implantation while periodontal ligamental cells are still viable. In addition, it is also important to recognise associated complications such as tooth aspiration and infection with abscess formation.[2,14]

CONCLUSION

The diversity of dental pathologies presents a diagnostic challenge for radiologists. Heightened awareness and familiarity with the radiological appearances of common dental conditions can aid in reaching a timely and accurate diagnosis of the dental abnormality even when the findings are unanticipated.

REFERENCES

1. Som PM, Curtin HD. Head and Neck Imaging. 4th ed. St. Louis, MO: Mosby; 2003.
2. Scheinfeld MH, Shifteh K, Avery LL, Dym H, Dym RJ. Teeth: what radiologists should know. Radiographics. 2012;32:1927-44. Crossref
3. Kannan D, Gurunathan D. Comparison of two systems of tooth numbering among undergraduate dental students. Indian J Dent Res. 2016;27:378-82. Crossref
4. Chapman MN, Nadgir RN, Akman AS, Saito N, Sekiya K, Kaneda T, et al. Periapical lucency around the tooth: radiologic evaluation and differential diagnosis. Radiographics. 2013;33:E15-32. Crossref
5. Abrahams JJ. Dental CT imaging: a look at the jaw. Radiology. 2001;219:334-45. Crossref
6. White SC, Pharoah MJ. Oral Radiology: Principles and Interpretation. 7th ed. St. Louis, MO: Elsevier; 2014.
7. Dunfee BL, Sakai O, Pistey R, Gohel A. Radiologic and pathologic characteristics of benign and malignant lesions of the mandible. Radiographics. 2006;26:1751-68. Crossref
8. Theodorou SJ, Theodorou DJ, Sartoris DJ. Imaging characteristics of neoplasms and other lesions of the jawbones: part 1. Odontogenic tumors and tumorlike lesions. Clin Imaging. 2007;31:114-9. Crossref
9. Sham E, Leong J, Maher R, Schenberg M, Leung M, Mansour AK. Mandibular ameloblastoma: clinical experience and literature review. ANZ J Surg. 2009;79:739-44. Crossref
10. Barnes L. Surgical Pathology of the Head and Neck. 2nd ed. New York: M. Dekker; 2001.
11. Yusof WZ. Non-syndrome multiple supernumerary teeth: literature review. J Can Dent Assoc. 1990;56:147-9.
12. al-Emran S. Prevalence of hypodontia and developmental malformation of permanent teeth in Saudi Arabian schoolchildren. Br J Orthod. 1990;17:115-8. Crossref
13. Thorburn DN, Ferguson MM. Familial ogee roots, tooth mobility, oligodontia, and microdontia. Oral Surg Oral Med Oral Pathol. 1992;74:576-81. Crossref
14. Ramanojam S, Halli R, Hebbale M, Bhardwaj S. Ectopic tooth in maxillary sinus: Case series. Ann Maxillofac Surg. 2013;3:89-92. Crossref
15. Hasbini AS, Hadi U, Ghafari J. Endoscopic removal of an ectopic third molar obstructing the osteomeatal complex. Ear Nose Throat J. 2001;80:667-70.
16. Bakland LK, Andreasen JO. Dental traumatology: essential diagnosis and treatment planning. Endodontic Topics. 2004;7:14-34. Crossref