

---

---

## CASE REPORT

---

---

# Repeated Percutaneous Thrombin Injections as Treatment of a Large Iatrogenic Pseudoaneurysm in the Artery Supplying a Haemodialysis Arteriovenous Fistula

NR Mahboobani, LF Cheng, JKF Ma

*Department of Radiology, Princess Margaret Hospital, Laichikok, Hong Kong*

### ABSTRACT

*We report a case of obliteration of a large radial artery pseudoaneurysm complicating venous angioplasty in a patient with a left forearm Brescia-Cimino fistula. Obliteration was by combined balloon-assisted and ultrasound-guided direct percutaneous thrombin injections. The procedure was performed twice. There was subsequent salvage of the fistula with restoration of function and minimal cosmetic disfigurement following subsequent pseudoaneurysm shrinkage. This procedure provides a safe treatment of such complications and can be repeated. We describe the procedure and its advantages and discuss other treatment options.*

*Key Words: Arteriovenous fistula; Thrombin*

## 中文摘要

### 重複經皮凝血酶注射治療動脈供應血液透析動靜脈瘻的大型醫源性假性動脈瘤

馬承志、鄭力暉、馬嘉輝

本文報告1例左前臂Brescia-Cimino瘻患者靜脈血管成形術併發大橈動脈假性動脈瘤的閉塞治療。通過氣囊輔助和超聲引導的直接經皮凝血酶注射聯合進行閉塞。該過程進行了兩次。在隨後的假性動脈瘤收縮後，隨後恢復功能和最小外觀上的變形，瘻管隨後收縮。該方法提供對這些併發症的安全治療，並且可以重複進行。我們描述其過程和優點，並討論其他治療方案。

### INTRODUCTION

According to the National Kidney Foundation guidelines, a surgically created arteriovenous fistula (AVF) is the preferred means of vascular access for catheter-free haemodialysis.<sup>1</sup>

Pseudoaneurysms can complicate dialysis AVFs and limit their effectiveness. Treatment options include surgery, ultrasound-guided compression of the pseudoaneurysm neck, and endovascular and direct percutaneous techniques. We report a patient with a left forearm

---

---

*Correspondence: Dr NR Mahboobani, Department of Radiology, Princess Margaret Hospital, Laichikok, Kowloon, Hong Kong.  
Email: neeraj.mahboobani@gmail.com*

Submitted: 31 May 2016; Accepted: 6 Sep 2016.

Disclosure of Conflicts of Interest: The authors have no conflicts of interest to disclose.

Ethical approval: The study was approved by the research ethics committee at the participating institution [reference number KW/EX-16-047(97-06)]. Requirement for patient consent was waived by the ethics board.

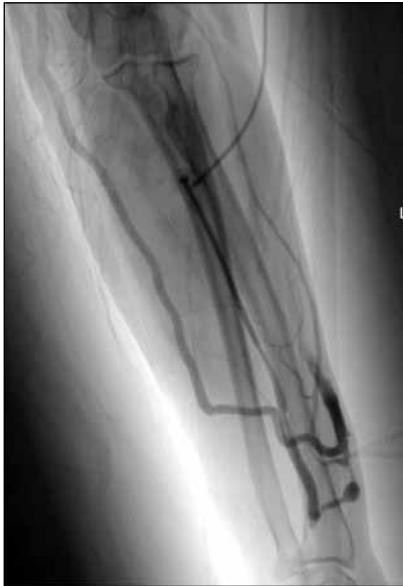Brescia-Cimino fistula in whom successful obliteration of an iatrogenic arterial pseudoaneurysm was achieved following combined and repeated use of balloon-assisted and ultrasound-guided direct percutaneous thrombin injections with subsequent salvage and restoration of AVF function.

## CASE PRESENTATION

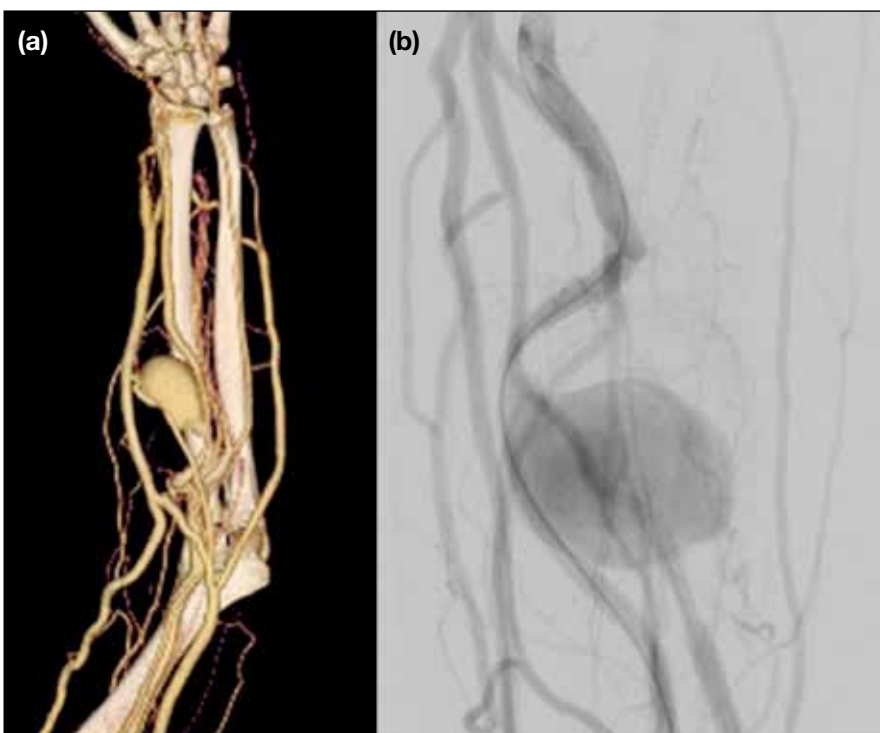A 65-year-old woman on haemodialysis via a left forearm Brescia-Cimino fistula presented with a history of ineffective dialysis for 14 months following creation of the AVF due to short segment 70% stenosis in the venous limb. Venous angioplasty was performed via the left radial artery at the mid-forearm level (Figure 1) to alleviate the stenosis with good angiographic results.

Two months after venous angioplasty the patient presented with a pulsatile mass in her left forearm. Computed tomography angiogram revealed a 6.2-cm pseudoaneurysm, with transverse diameter of 3.3 cm and a 5-mm neck in the proximal left radial artery at the access site of the previous venous angioplasty (Figure 2). The AVF was also noted to be ineffective for haemodialysis and the patient was commenced on temporary catheter haemodialysis.

After obtaining informed consent, ultrasound-guided direct percutaneous thrombin injection was performed via a 5- × 80-mm angioplasty balloon catheter (POWERFLEX Pro; Cordis, Fremont [CA], United States) positioned and inflated across the neck of the pseudoaneurysm. Three 22G spinal needles were inserted under ultrasound guidance into the pseudoaneurysm sac



**Figure 1.** Arterial access site in mid-forearm. Fistulogram prior to venous angioplasty showing site of vascular access in left mid-forearm.



**Figure 2.** Radial artery pseudoaneurysm. (a) Three-dimensional volume-rendered computed tomography angiogram image and (b) fistulogram showing left radial artery pseudoaneurysm in proximal forearm.

(Figure 3). A total of 11,000 IU bovine thrombin (1000 IU/mL) was slowly injected simultaneously via the spinal needles to fill the pseudoaneurysm sac. The needles were withdrawn and the balloon catheter subsequently deflated. A small residual 2- × 2-cm pseudoaneurysm was noted at the end of the procedure. The radial artery, AVF, and draining veins were patent.

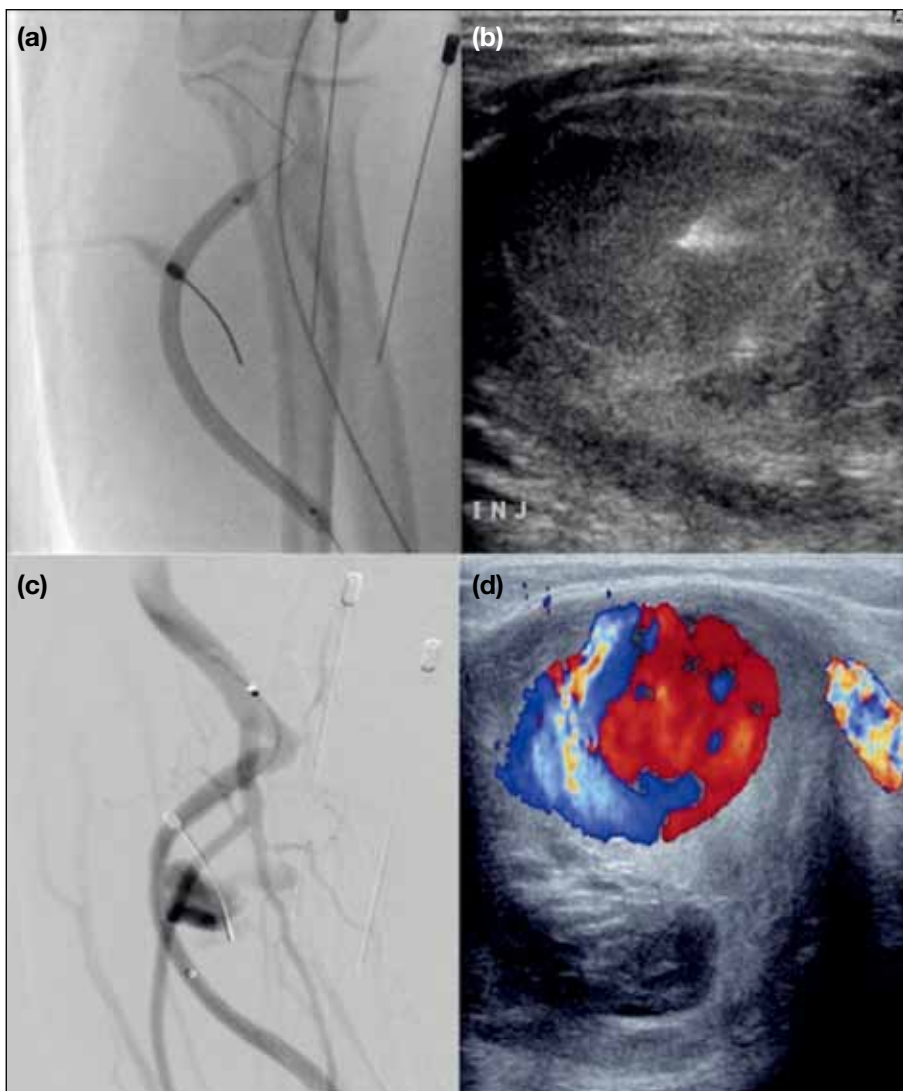
The residual pseudoaneurysm persisted and enlarged so the procedure was repeated after 2 months. A total of 11,000 IU bovine thrombin was injected again via two 22G spinal needles to fill the pseudoaneurysm sac. A tiny 0.3-cm residual pseudoaneurysm neck was noted at the end (Figure 4). The radial artery, AVF, and draining veins remained patent.

Serial duplex ultrasound 4 months after the second procedure showed spontaneous complete obliteration of the residual pseudoaneurysm (Figure 5).

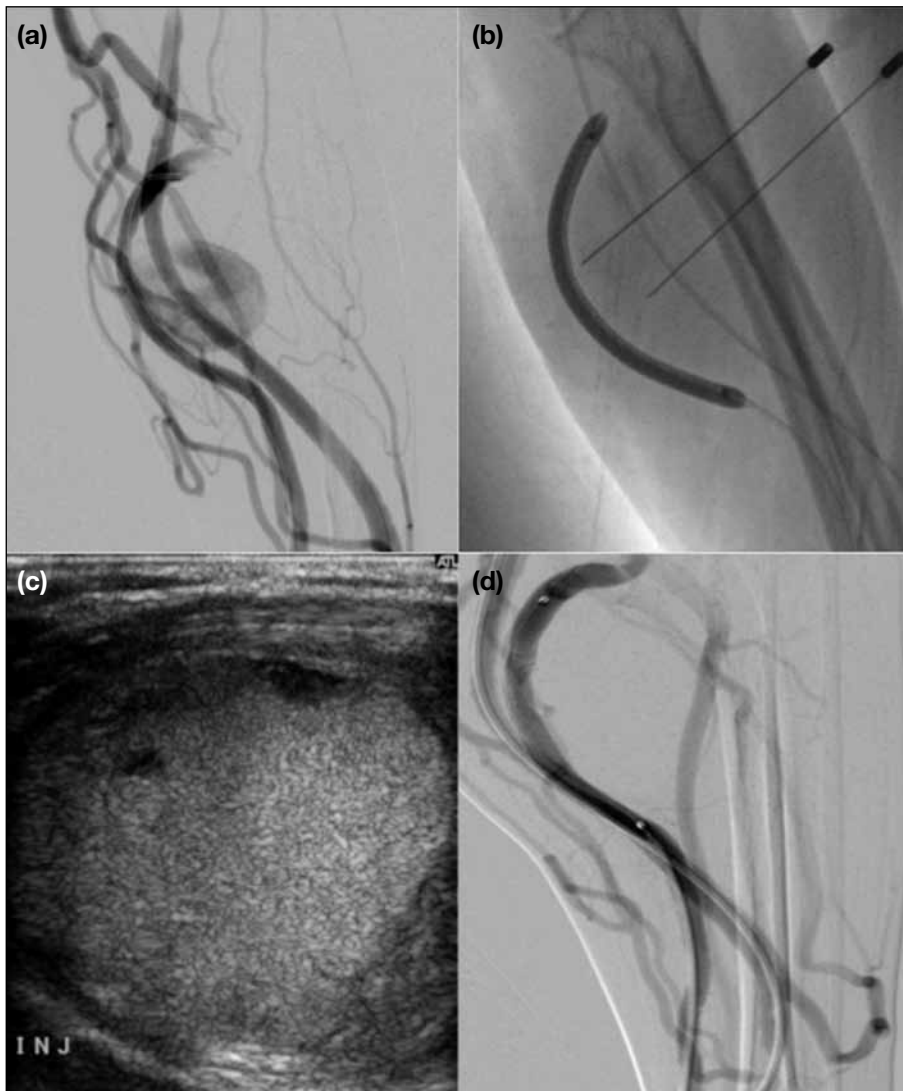The patient subsequently resumed catheter-free dialysis via the left forearm Brescia-Cimino fistula.

## DISCUSSION

Most pseudoaneurysms that complicate dialysis AVFs are a result of thinning of the vascular wall consequent to repetitive needle puncture during chronic haemodialysis. Pseudoaneurysms can also develop along the native artery due to improper positioning of the arterial dialysis cannula. In our patient, the pseudoaneurysm developed following arterial access for venous limb angioplasty.



**Figure 3.** First procedure. (a and b) Balloon-assisted direct percutaneous thrombin injection under ultrasound guidance. (c and d) Residual pseudoaneurysm at the end of the procedure.



**Figure 4.** Second procedure. (a) Fistulogram showing residual pseudoaneurysm prior to second thrombin injection. (b) Fluoroscopic image of balloon-assisted direct percutaneous thrombin injection. (c) Ultrasound image showing complete filling of pseudoaneurysm with thrombin. (d) Post-procedure fistulogram showing minimal residual neck.

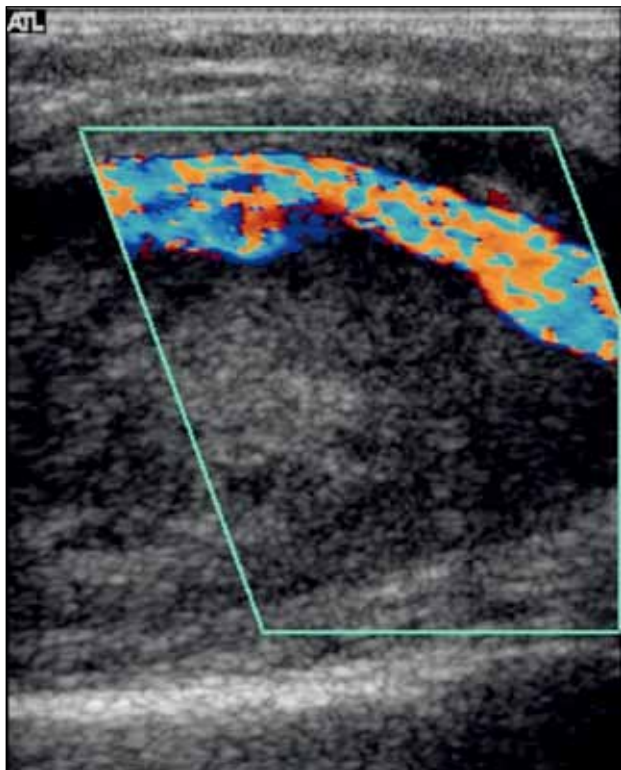
Should arterial access be used for venous angioplasty in cases of AVF-associated venous limb stenosis, it is essential to select access sites in proximity to anatomical bone landmarks since compression of an arterial access site against underlying bone is more likely to result in successful haemostasis than compression against underlying soft tissue.

Pseudoaneurysms have been traditionally treated with surgical repair but this is invasive and often associated with higher morbidity.<sup>2</sup> Minimally invasive techniques have evolved over time. These include compression of the pseudoaneurysm neck under ultrasound guidance using endovascular and direct percutaneous techniques. Endovascular options include transcatheter obliteration of the pseudoaneurysm with coils, trapping of the pseudoaneurysm with coil embolisation proximal

and distal to the neck of the pseudoaneurysm, and exclusion of the pseudoaneurysm from circulation by use of a covered stent. Direct percutaneous treatment options include coil embolisation, glue and thrombin injection.<sup>2</sup>

In our case, the large size of the pseudoaneurysm meant ultrasound-guided compression of the neck was unlikely to be successful.

Endovascular trapping of the pseudoaneurysm with coil embolisation proximal and distal to the neck of the pseudoaneurysm was a feasible treatment option provided an adequate distal supply to the forearm and hand via the ulnar artery. However, this would render the AVF ineffective and necessitate creation of a new AVF for haemodialysis.



**Figure 5.** Duplex ultrasound 4 months after the second procedure showing thrombosed pseudoaneurysm with no residual neck and patent radial artery.

Exclusion of the pseudoaneurysm from circulation by use of a covered stent carried the inherent risk of in-stent thrombosis especially in this case where the parent radial artery was of small calibre.

Endovascular transcatheter coil embolisation, direct percutaneous coil embolisation, and direct percutaneous glue injection would have successfully obliterated the pseudoaneurysm in our patient but would have also resulted in cosmetic disfiguration with a conspicuous hard mass in the patient's forearm. The thrombosed pseudoaneurysm in our patient gradually shrank and largely resolved, thereby minimising the cosmetic disfiguration.

Percutaneous direct thrombin injection has been gaining popularity in the management of pseudoaneurysms.<sup>3-9</sup> In most cases a small volume of thrombin (<5 mL) is used. The size of the neck of the pseudoaneurysm relative to the calibre of the parent artery is an important factor to evaluate.<sup>2</sup> Placement of an endovascular balloon across the neck of the pseudoaneurysm during thrombin injection has been advocated in wide-neck pseudoaneurysms to ensure no active thrombin or thrombus escapes into

the native vessel.<sup>9</sup> We incorporated this precautionary measure in our treatment procedures as the neck of the pseudoaneurysm was the same size as the calibre of the parent radial artery. Since balloon occlusion carries a potential risk of distal stasis and thrombosis, intermittent flushing with heparinised saline through the balloon catheter tip is recommended.

A previous case report has described anaphylaxis in a patient after thrombin injection into a pseudoaneurysm.<sup>10</sup> The patient had previous repeated exposure to topical bovine thrombin, used for haemostasis at dialysis puncture sites. The authors proposed that patients with previous exposure to thrombin should undergo skin prick testing prior to subsequent thrombin exposure. If the test is positive, alternative treatment options need to be considered.

Recombinant human thrombin and human plasma-derived thrombin have been reported to be effective in the treatment of pseudoaneurysms without the associated risk of adverse immunological reactions.<sup>4,11</sup> Recombinant human thrombin is not available in our institution but human plasma-derived thrombin at a concentration of 500 IU/mL is available as a component in fibrin sealant kits or combination haemostatic products. There remains a theoretical risk of transmission of blood-borne pathogens when using human plasma-derived thrombin.<sup>12</sup>

Thrombin concentration has been shown to profoundly influence fibrin clot structure. Clots formed with lower thrombin concentrations are more susceptible to fibrinolysis compared with those formed with higher thrombin concentrations.<sup>13</sup> We used bovine thrombin as this was available at a higher concentration of 1000 IU/mL. Despite the higher concentration, large volumes still needed to be injected during each procedure to achieve complete obliteration of the pseudoaneurysm.

## CONCLUSION

We report a case of successful obliteration with subsequent shrinkage of a large iatrogenic pseudoaneurysm in the artery supplying an AVF. We used repeated percutaneous injections of a large volume of bovine thrombin with balloon insufflation across the pseudoaneurysm neck. The AVF was salvaged with subsequent resumption of effective haemodialysis and minimal cosmetic disfiguration. Our case illustrates that this is a viable treatment option that can be repeated to preserve the AVF in small calibre vessels when there

is an inherent risk of thrombosis associated with use of a covered stent. Glue injection or coil embolisation of the pseudoaneurysm sac would have also obliterated the pseudoaneurysm but would have resulted in a permanent conspicuous mass.

## REFERENCES

1. NKF-DOQI clinical practice guidelines for hemodialysis adequacy. National Kidney Foundation. *Am J Kidney Dis.* 1997;30(3 Suppl 2):S15-66. [Crossref](#)
2. Saad NE, Saad WE, Davies MG, Waldman DL, Fultz PF, Rubens DJ. Pseudoaneurysms and the role of minimally invasive techniques in their management. *Radiographics.* 2005;25 Suppl 1:S173-89. [Crossref](#)
3. La Perna L, Olin JW, Goines D, Childs MB, Ouriel K. Ultrasound-guided thrombin injection for the treatment of postcatheterization pseudoaneurysms. *Circulation.* 2000;102:2391-5. [Crossref](#)
4. Elford J, Burrell C, Freeman S, Roobottom C. Human thrombin injection for the percutaneous treatment of iatrogenic pseudoaneurysms. *Cardiovasc Intervent Radiol.* 2002;25:115-8. [Crossref](#)
5. Ghersin E, Karram T, Gaitini D, Ofer A, Nitecki S, Schwarz H, et al. Percutaneous ultrasonographically guided thrombin injection of iatrogenic pseudoaneurysms in unusual sites. *J Ultrasound Med.* 2003;22:809-16. [Crossref](#)
6. Clark TW, Abraham RJ. Thrombin injection for treatment of brachial artery pseudoaneurysm at the site of a hemodialysis fistula: report of two patients. *Cardiovasc Intervent Radiol.* 2000;23:396-400. [Crossref](#)
7. Keeling AN, Naughton PA, McGrath FP, Conlon PJ, Lee MJ. Successful endovascular treatment of a hemodialysis graft pseudoaneurysm by covered stent and direct percutaneous thrombin injection. *Semin Dial.* 2008;21:553-6. [Crossref](#)
8. Corso R, Rampoldi A, Vercelli R, Leni D, Vanzulli A. Percutaneous repair of radial artery pseudoaneurysm in a hemodialysis patient using sonographically guided thrombin injection. *Cardiovasc Intervent Radiol.* 2006;29:130-2. [Crossref](#)
9. van Helden EJ, Eefting D, Florie J, Verhagen HJ, Moelker A. Endovascular salvage of a false aneurysm of the posterior tibial artery caused by a stab from a stingray. *Cardiovasc Intervent Radiol.* 2015;38:498-500. [Crossref](#)
10. Pope M, Johnston KW. Anaphylaxis after thrombin injection of a femoral pseudoaneurysm: recommendations for prevention. *J Vasc Surg.* 2000;32:190-1. [Crossref](#)
11. Malgor RD, Labropoulos N, Gasparis AP, Landau DS, Tassiopoulos AK. Results of a new human recombinant thrombin for the treatment of arterial pseudoaneurysm. *Vasc Endovascular Surg.* 2012;46:145-9. [Crossref](#)
12. Lew WK, Weaver FA. Clinical use of topical thrombin as a surgical hemostat. *Biologics.* 2008;2:593-9.
13. Wolberg AS. Thrombin generation and fibrin clot structure. *Blood Rev.* 2007;21:131-42. [Crossref](#)