
CASE REPORT

Delayed Cerebral Hyperperfusion with Subarachnoid Haemorrhage after Carotid Artery Stenting

DML Tse¹, G Ho¹, CP Tsang², KH Chan³, R Lee¹

¹Department of Radiology, Queen Mary Hospital, Pokfulam, Hong Kong

²Department of Neurosurgery, Queen Mary Hospital, Pokfulam, Hong Kong

³Department of Medicine, The University of Hong Kong, Pokfulam, Hong Kong

ABSTRACT

Cerebral hyperperfusion syndrome is a rare but serious complication after carotid revascularisation procedures that manifests as ipsilateral migraine-like headache, seizure, and transient focal neurological deficits in the absence of cerebral ischaemia. Cerebral hyperperfusion syndrome may lead to cerebral oedema and haemorrhage, and imaging findings of hyperperfusion may be seen. Cerebral hyperperfusion syndrome and haemorrhage after carotid artery stenting occurs most often in the first postoperative day and rarely after the first week. We report a case of a patient with delayed subarachnoid haemorrhage 16 days after carotid artery stenting, presenting with headache and focal neurological deficit, with associated imaging findings of hyperperfusion. Given the short hospital stays associated with carotid artery stenting, the present case highlights the need for vigilance by patients, carers, and clinicians for this serious complication.

Key Words: Computed tomography angiography; Endarterectomy, carotid

中文摘要

頸動脈支架術後蛛網膜下腔出血和遲發性腦高灌注綜合徵

謝民立、何潔明、曾振邦、陳灌豪、李雷釗

腦高灌注綜合徵是頸動脈血運重建術後罕見但嚴重的併發症，症狀表現為在沒有腦缺血的情況下出現同側偏頭痛類頭痛、癲癇發作和短暫局灶性神經功能缺損。腦高灌注綜合徵可導致腦水腫和出血，並可能有高灌注影像學表現。頸動脈支架術後腦高灌注綜合徵和出血大多在術後第一天發生，術後一周發生的機會很少。本文報告一名患者在頸動脈支架術後16天出現遲發性蛛網膜下腔出血、頭痛和局灶性神經功能缺損，並伴有高灌注影像學表現。鑑於與頸動脈支架術相關的住院時間短，本病例強調患者、護理人員和醫生須對這種嚴重併發症提高警覺。

INTRODUCTION

Cerebral hyperperfusion syndrome (CHS) is a relatively rare but serious complication after carotid endarterectomy (CEA) or carotid artery stenting (CAS).

Clinical findings of CHS typically include the triad of ipsilateral migraine-like headache, seizure, and transient focal neurological deficits in the absence of cerebral ischaemia. The incidence of CHS has been

Correspondence: Dr DML Tse, Department of Radiology, Queen Mary Hospital, Pokfulam, Hong Kong.
Email: donald.tse@gmail.com

Submitted: 14 Dec 2016; Accepted: 14 Feb 2017.

Disclosure of Conflicts of Interest: All authors have disclosed no conflicts of interest.

reported as from 0.2% to 18.9%.^{1,2} Hyperperfusion, as defined by imaging findings of increased cerebral blood flow compared with preoperative or baseline values, is reported in between 10% and 15% of patients undergoing carotid revascularisation.^{3,4} CHS may result in cerebral oedema and intracranial haemorrhage with high mortality.^{3,5} Risk factors for CHS or hyperperfusion include old age, diabetes, long-standing hypertension, recent contralateral CEA, high-grade ipsilateral stenosis, contralateral carotid stenosis, poor collateralisation, intra-operative ischaemia, and postoperative hypertension.^{3,6}

Previous studies show that CHS, with or without haemorrhage, occurs mostly within a few days after CEA or CAS.⁵ However, CHS occurs significantly earlier after CAS than after CEA, peaking in the first postoperative day.⁵ However, there are rare reports of CHS presenting 3 to 4 weeks after CEA or CAS.^{7,8} We report a case of a patient with delayed cerebral hyperperfusion, presenting with subarachnoid haemorrhage (SAH) 16 days after CAS.

CASE REPORT

A 61-year-old man presented on follow-up with episodes of pre-syncopal attacks, often accompanied by left lower limb weakness. His co-morbidities also included hypercholesterolaemia. The patient had a history of nasopharyngeal carcinoma treated with radiotherapy 18 years previously, and symptomatic 70% left common carotid artery (CCA) stenosis presenting with amaurosis fugax treated with carotid stenting 13 years previously.

The patient underwent duplex Doppler ultrasound scanning and computed tomography (CT) angiography, and results revealed >70% stenosis at the proximal right CCA, >70% in-stent restenosis of the left CCA, and no other significant stenosis. Bilateral symptomatic high-grade carotid stenosis was diagnosed and, because CEA was contraindicated owing to the previous neck radiotherapy, early bilateral CAS was arranged.

Bilateral CAS was performed under conscious sedation, with dual antiplatelet therapy and intravenous heparin cover. Placement of Wallstent (Boston Scientific, Marlborough [MA], US) at the left and right CCA was achieved with the use of a distal embolic protection device (FilterWire EZ, Boston Scientific). Post-stenting angiograms showed 90% luminal regain on the left and >90% on the right, with patent outflows (Figure 1). The patient was continued on dual antiplatelet therapy and was discharged home 2 days after CAS.

At 16 days after CAS the patient was noted to have a few episodes of transient left lower limb weakness, associated with mild headache over the right side of the head and vertex. Physical examination revealed mild (grade 5-/5) left lower limb weakness. No seizure was witnessed. CT images of the brain showed mild SAH over the right frontal, parietal, and temporal regions (Figure 2). No associated cerebral oedema or parenchymal haemorrhage was seen. CT angiography showed patent bilateral CCA stents, with no evidence of thrombosis or saccular cerebral aneurysm. CT perfusion performed on day 22 after CAS showed elevation of cerebral blood flow with elevation of cerebral blood volume over the right frontal region, with corresponding reduction of mean transit time (Figure 3a).

The patient was treated non-operatively with blood pressure optimisation to 100 to 110 mm Hg systolic and 60 to 80 mm Hg diastolic, and he remained neurologically stable with no seizure. Subsequent repeat CT perfusion at day 33 (17 days after haemorrhage) showed resolved SAH and resolved right frontal hyperperfusion (Figure 3b). The patient remained stable and was discharged from the hospital. The patient was continued on dual antiplatelet therapy and has remained asymptomatic since. Duplex Doppler ultrasound scanning at 2 years after CAS showed patent bilateral CCA stents with no in-stent restenosis.

DISCUSSION

Pathophysiology of CHS is thought to be caused by loss of cerebral autoregulation in areas of chronic ischaemia, with subsequent reperfusion leading to unregulated increase in blood flow.^{3,6} Cerebral ischaemia during internal carotid artery occlusion is also thought to contribute to CHS, through the production of reactive oxygen species, which leads to widespread endothelial damage.^{5,6} Delayed hyperperfusion is considered rare after CAS; CHS occurs mostly within the first few days after CEA but peaks on the first day with CAS.^{5,7,8} Earlier occurrence of CHS after CAS compared with after CEA may be explained by more frequent and prolonged hypotension over the first 24 hours after CAS. This hypotension is thought to be related to carotid artery baroreceptor damage caused during the CAS procedure or to the larger ischaemic burden from distal emboli from CAS.^{5,6} The cause of delayed onset of hyperperfusion in the present case is uncertain. A potential cause to consider could be more variable blood pressure, because the patient engaged in physical activity after discharge from the neurosurgical ward.

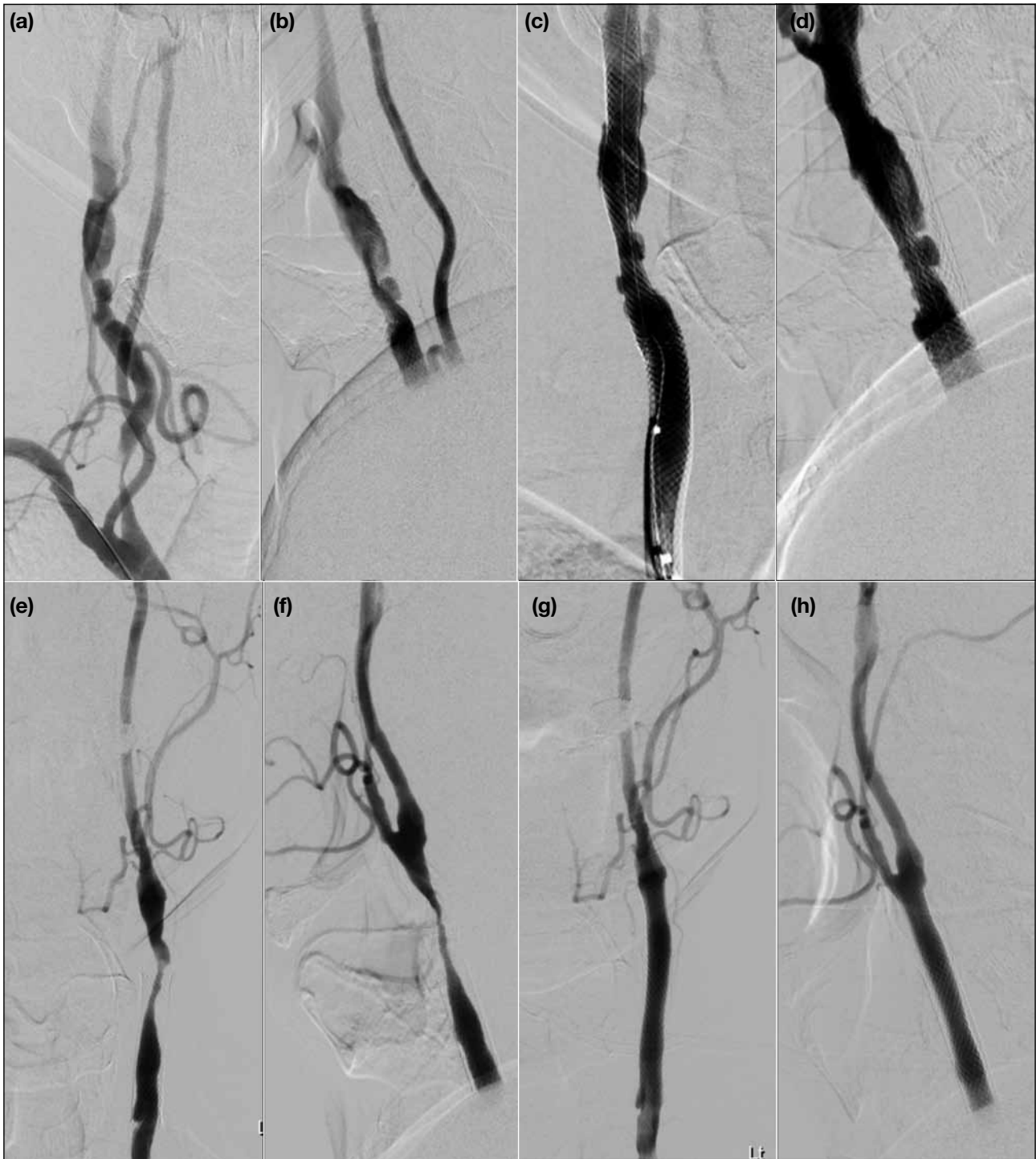


Figure 1. Digital subtraction angiograms in anteroposterior and lateral projections of right CCA/ICA (a, b) immediately pre-stenting and (c, d) post-stenting, and of left CCA/ICA (e, f) pre-CAS and (g, h) post-CAS, showing $\geq 90\%$ luminal regain bilaterally post-CAS. Abbreviations: CAS = carotid artery stenting; CCA = common carotid artery; ICA = internal carotid artery.

Intracranial haemorrhage in hyperperfusion is thought to occur when areas with endothelial damage are exposed to uncontrolled high arterial pressure. The SAH seen in the present case may be caused by the rupture of small cortical vessels exposed to elevated

blood flow and arterial pressure. The routine use of dual antiplatelet therapy in CAS is thought to explain the slightly increased risk of haemorrhage compared with CEA.⁶ Intracerebral haemorrhage may be seen in hyperperfusion after both CEA and CAS. However,

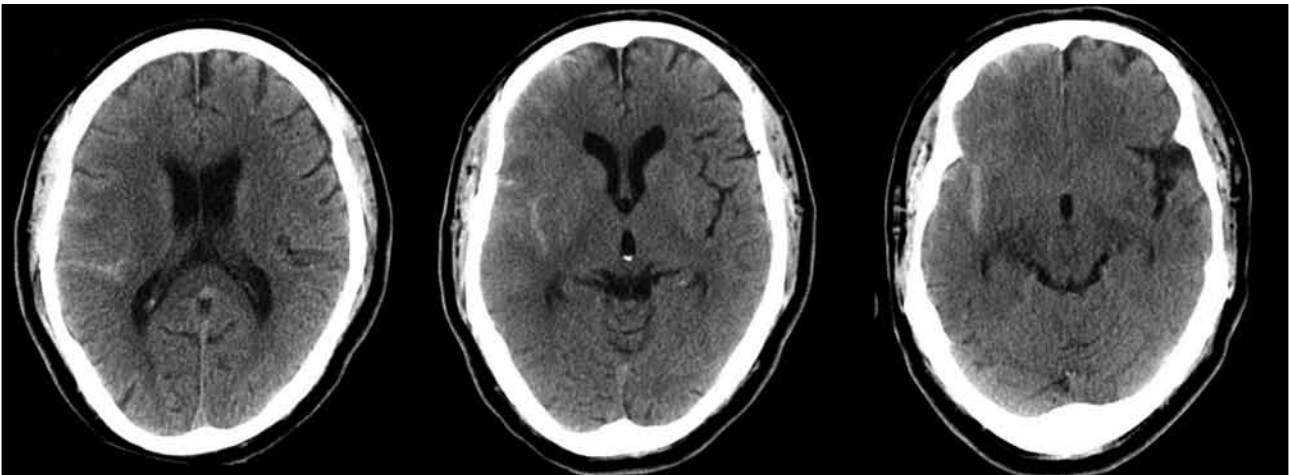


Figure 2. Axial slices from computed tomography brain at re-admission on day 16 after carotid artery stenting showing right-sided acute subarachnoid haemorrhage.

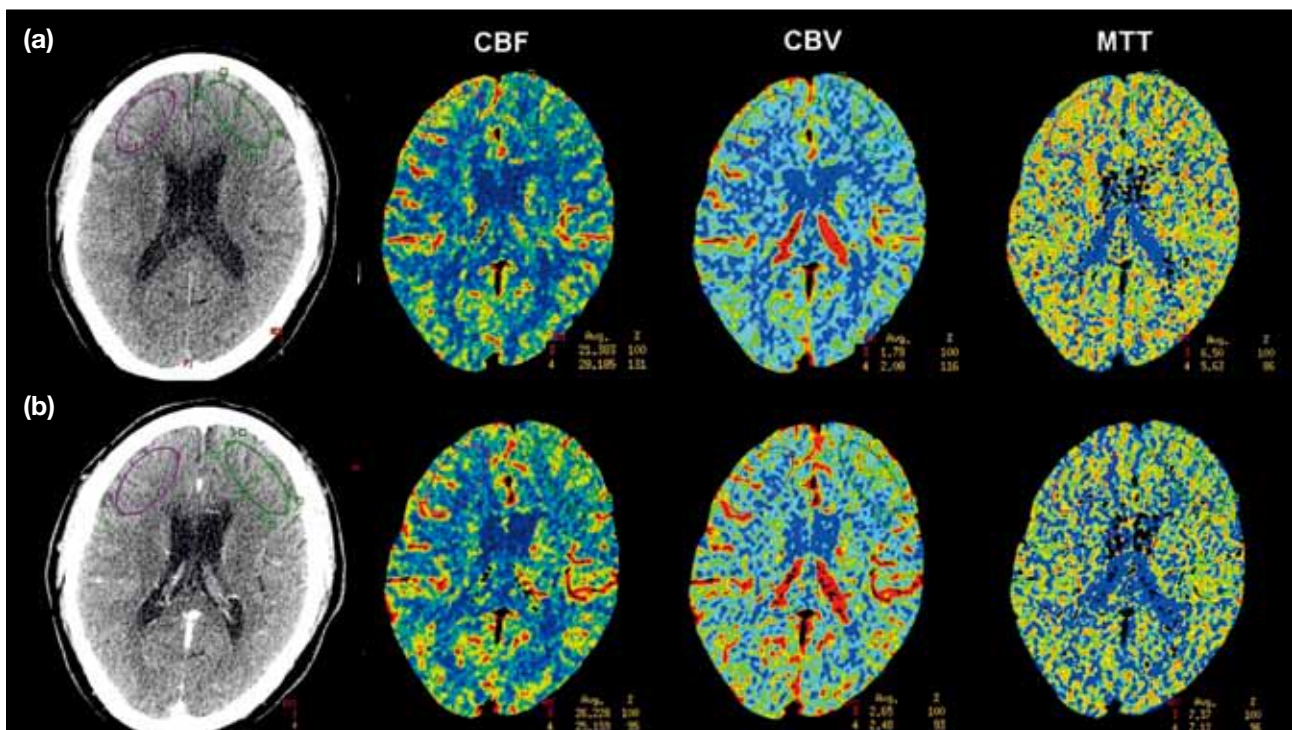


Figure 3. Cerebral perfusion study performed on (a) day 22 and (b) day 33 after CAS. (a) CBF and CBV are increased in the right frontal region, while MTT is mildly decreased, consistent with hyperperfusion; (b) CBF, CBV, and MTT are similar between right and left frontal regions.

Abbreviations: CAS = carotid artery stenting; CBF = cerebral blood flow; CBV = cerebral blood volume; MTT = mean transit time.

SAH has only been reported following CAS but not in CEA, and most cases of haemorrhage after CAS are still intracerebral.⁵ Nevertheless, mortality is significantly higher in CHS with intracranial haemorrhage (26%) than without (3%).⁵

In the present case, cerebral hyperperfusion was confirmed on perfusion CT; however, the patient only

presented with two of the three defining clinical features of CHS, with no seizure documented. Indeed, in previous studies only a proportion of patients with imaging-proven hyperperfusion have CHS.^{3,9,10} One recent study of 31 patients undergoing CAS showed four patients with CHS, six patients with hyperperfusion on imaging, but only one patient overlap between the two groups, suggesting CHS and hyperperfusion do not always

coincide.⁴ In the present case the patient was treated as per CHS with aggressive blood pressure control and did not develop seizure.

Although the patient underwent bilateral CAS, SAH and features of hyperperfusion occurred only on the right side. One possible reason for this is the greater degree of luminal regain on the right compared with the left, although the difference is likely to be small. Previous stenting to the left CCA is also likely to be a factor; the duration of chronic ischaemia suffered on the left side would be shorter, with a period of improvement after previous CAS. Our patient had a patent anterior communicating artery but no posterior communicating arteries. Therefore, treatment of bilateral significant stenosis at a single session may have limited the “escape route” collaterals available for the increased blood flow in the right internal carotid artery, because the blood flow in the left internal carotid artery was also increased after stenting. This is supported by Katano et al,¹¹ who found that high postoperative increase in cerebral blood flow after CAS or CEA are most frequently found in patients without a patent anterior communicating artery and with poor collateral flow.

The current management of CHS is predominantly symptomatic. Therefore, prevention and prediction of CHS or hyperperfusion are key to avoiding complications such as haemorrhage. Some risk factors, including severe ipsilateral stenosis, contralateral stenosis, and poor collateralisation, are indicative of poor cerebrovascular reserve. Studies using perfusion CT before CAS may be able to identify those with impaired cerebrovascular reserve and who are therefore at risk of developing CHS. Tseng et al¹² found that an absolute difference in mean transit time of >3 s between ipsilateral and contralateral sides is associated with occurrence of CHS. Moreover, Yoshie et al¹³ found significant differences in resting and post-acetazolamide cerebral blood flow and mean transit time between CHS and non-CHS patients. The authors found that the absolute value of post-acetazolamide mean transit time correlated most closely with CHS, but they concluded that the resting mean transit time value was sufficiently accurate. These studies echo other earlier studies that suggested mean transit time to be more sensitive than cerebral blood flow and cerebral blood volume for identifying haemodynamic compromise.¹³ Prevention strategies for CHS include stringent blood pressure control in the early postoperative period, and performing staged angioplasty and stenting procedures in those at higher risk of developing CHS.^{6,14}

CONCLUSION

We have described a case of a patient with delayed SAH with imaging features of cerebral hyperperfusion, 16 days after bilateral CAS to symptomatic high-grade stenosis. Because CAS is often associated with short hospital stays, the present case highlights the need for education of patients and carers to be aware of the symptoms of CHS or SAH, and to seek prompt medical help when necessary. There is also a need for vigilance by clinicians for this potentially serious complication even after the immediate postoperative period.

REFERENCES

1. Sundt TM Jr, Sharbrough FW, Piepgras DG, Kearns TP, Messick JM Jr, O’Fallon WM. Correlation of cerebral blood flow and electroencephalographic changes during carotid endarterectomy, with results of surgery and hemodynamics of cerebral ischaemia. *Mayo Clin Proc.* 1981;56:533-43.
2. van Mook WN, Rennenberg RJ, Schurink GW, van Oostenbrugge RJ, Mess WH, Hofman PA, et al. Cerebral hyperperfusion syndrome. *Lancet Neurol.* 2005;4:877-88. [Crossref](#)
3. Moulakakis KG, Mylonas SN, Sfyroeras GS, Andrikopoulos V. Hyperperfusion syndrome after carotid revascularization. *J Vasc Surg.* 2009;49:1060-8. [Crossref](#)
4. Aralasmak A, Atay M, Toprak H, Ozdemir T, Asil T, Goktekin O, et al. Hyperperfusion in carotid stenting patients. *J Comput Assist Tomogr.* 2015;39:313-6.
5. Ogasawara K, Sakai N, Kuroiwa T, Hosoda K, Iihara K, Toyoda K, et al. Intracranial haemorrhage associated with cerebral hyperperfusion syndrome following carotid endarterectomy and carotid artery stenting: retrospective review of 4494 patients. *J Neurosurg.* 2007;107:1130-6. [Crossref](#)
6. Medel R, Crowley RW, Dumont AS. Hyperperfusion syndrome following endovascular cerebral revascularization. *Neurosurg Focus.* 2009;26:E4. [Crossref](#)
7. Oh SI, Lee SJ, Lee YJ, Kim HJ. Delayed cerebral hyperperfusion syndrome three weeks after carotid artery stenting presenting as status epilepticus. *J Korean Neurosurg Soc.* 2014;56:441-3. [Crossref](#)
8. Lieb M, Shah U, Hines GL. Cerebral hyperperfusion syndrome after carotid intervention: a review. *Cardiol Rev.* 2012;20:84-9.
9. Imai K, Mori T, Izumoto H, Watanabe M, Majima K. Emergency carotid artery stent placement in patients with acute ischaemic stroke. *AJNR Am J Neuroradiol.* 2005;26:1249-58.
10. Kaku Y, Yoshimura S, Kokuzawa J. Factors predictive of cerebral hyperperfusion after carotid angioplasty and stent placement. *AJNR Am J Neuroradiol.* 2004;25:1403-8.
11. Katano H, Mase M, Sakurai K, Miyachi S, Yamada K. Reevaluation of collateral pathways as escape routes from hyperemia/hyperperfusion following surgical treatment for carotid stenosis. *Acta Neurochir (Wien).* 2012;154:2139-48. [Crossref](#)
12. Tseng YC, Hsu HL, Lee TH, Hsieh IC, Chen CJ. Prediction of cerebral hyperperfusion syndrome after carotid stenting: a cerebral perfusion computed tomography study. *J Comput Assist Tomogr.* 2009;33:540-5. [Crossref](#)
13. Yoshie T, Ueda T, Takada T, Nogoshi S, Fukano T, Hasegawa Y. Prediction of cerebral hyperperfusion syndrome after carotid artery stenting by CT perfusion imaging with acetazolamide challenge. *Neuroradiology.* 2016;58:253-9. [Crossref](#)
14. Uchida K, Yoshimura S, Shirakawa M, Shindo S, Egashira Y, Iwama T, et al. Experience of staged angioplasty to avoid hyperperfusion syndrome for carotid artery stenosis. *Neurol Med Chir (Tokyo).* 2015;55:824-9. [Crossref](#)