

---

---

## ORIGINAL ARTICLE

---

---

# Imaging and Clinical Presentation of Caesarean Scar Pregnancy

KH Lee, G Ho, WM Wong, HL Lam, PW Lam

Department of Radiology, Queen Mary Hospital, Pokfulam, Hong Kong

### ABSTRACT

**Objective:** To evaluate transabdominal and transvaginal ultrasound for diagnosing Caesarean scar pregnancy.

**Methods:** This is a retrospective study of patients diagnosed with Caesarean scar pregnancy in a tertiary referral centre from March 2010 to February 2015. Patient demographics were retrieved from the hospital electronic patient record system. Transabdominal and transvaginal ultrasound scans at the first visit to our centre were reviewed by two radiologists by consensus for the presence of five sonographic signs including empty uterine cavity, empty endocervical canal, gestational sac embedded in low uterine segment/hysterotomy scar, thin/absent myometrium between the gestational sac and bladder, and angular appearance of gestational sac. The sensitivity of each sign was compared using McNemar's test.

**Results:** Fifteen patients (mean age 34.5 [28-40] years, mean gestational age 8 weeks 1 day [4 weeks 5 days to 15 weeks 0 days]) were included in the analysis. The majority of patients had only one previous Caesarean section (73%). The most common presenting complaint was vaginal bleeding (87%). The ratio between viable and non-viable scar pregnancy was 2:1. Transabdominal ultrasound was inferior to transvaginal ultrasound at detection of thin/absent myometrium (20% vs. 87%,  $p = 0.002$ ) as well as angular appearance of gestational sac (33.3% vs. 67%,  $p = 0.031$ ). Subgroup analysis showed that transabdominal ultrasound was reliable for prediction of thin/absent myometrium in the late first or early second trimester.

**Conclusions:** Caesarean scar pregnancy is a potentially life-threatening condition and accurate diagnosis requires a high index of suspicion. Transabdominal ultrasound is a useful adjunct to transvaginal ultrasound in the diagnosis of Caesarean scar pregnancy.

**Key Words:** Cesarean section; Pregnancy, ectopic; Ultrasonography

## 中文摘要

### 剖腹產疤痕妊娠的影像學和臨床表現

李錦浩、何潔明、黃慧美、林海琴、林培榮

**目的：**評估經腹和經陰道超聲波診斷剖腹產疤痕妊娠。

**方法：**對2010年3月至2015年2月在三級轉診中心診斷為剖腹產疤痕妊娠的患者進行回顧性研究。

---

**Correspondence:** Dr KH Lee, Department of Radiology, Queen Mary Hospital, Pokfulam, Hong Kong.  
Email: [vickb88@gmail.com](mailto:vickb88@gmail.com)

Submitted: 24 Feb 2017; Accepted: 20 Mar 2017.

Conflicts of Interest: All authors have disclosed no conflicts of interest.

Funding/Support: This research received no specific grant from any funding agency in the public, commercial, or not-for-profit sectors.

Ethics Approval: Ethics approval for this study was obtained from Institutional Review Board of the University of Hong Kong/Hospital Authority Hong Kong West Cluster (Ref UW 16-328). The need for informed consent was waived given the retrospective nature of the study.

從醫院電子病歷系統中檢索患者人口統計學數據。由兩名放射科醫師共同評估首次就診婦女的經腹和經陰道超聲波掃描是否存在以下五個超聲徵象，包括空子宮腔、空宮頸管、嵌於低位子宮切片 / 子宮切開術疤痕的妊娠囊、妊娠囊和膀胱間的薄弱 / 缺失子宮肌層，以及妊娠囊角度外觀。使用 McNemar 檢驗比較每個徵象的敏感度。

**結果：**共15名患者（平均年齡34.5歲〔介乎28-40歲〕，平均胎齡8週1天〔介乎4週5天至15週0天〕被納入分析。大部分患者（73%）只有一次剖腹產史。最常見徵狀是陰道出血（87%）。存活和非存活的疤痕妊娠比例為2：1。在檢測薄弱 / 缺失子宮肌層（20%比87%， $p = 0.002$ ）和妊娠囊角度外觀（33.3%比67%， $p = 0.031$ ）方面，經腹超聲波檢查不如經陰道超聲波檢查。亞組分析顯示經腹超聲波檢查能可靠預測早期或孕中期的子宮肌層薄弱或缺失。

**結論：**剖腹產疤痕妊娠可能危及生命，需要高度懷疑才可準確診斷。經腹超聲波檢查是經陰道超聲波診斷剖腹產疤痕妊娠的有用輔助手段。

## INTRODUCTION

Caesarean scar pregnancy is a potentially life-threatening condition. It occurs in cases of gestational sac implantation within a prior hysterotomy scar. Direct invasion of the myometrium by trophoblast is possible via a microscopic myometrial defect at the relatively avascular lower uterine segment, secondary to incomplete scar healing and fibrosis.<sup>1,2</sup> Owing to abnormal placental implantation, there is a high propensity to develop complications, including placenta accreta, massive haemorrhage, and uterine rupture<sup>3,4</sup> as Caesarean scar pregnancy advances, leading to substantial maternal mortality and morbidity. Early and accurate diagnosis of this condition is therefore important.

Caesarean scar pregnancy was once thought to be a rare condition, with an estimated prevalence between 1:1800 and 1:2226 pregnancies<sup>2,5,6</sup>; however, its incidence is rising, likely because of the increasing rate of Caesarean delivery and more liberal use of transvaginal ultrasound.<sup>5</sup> Various authors have put forward different sonographic criteria for the diagnosis of Caesarean scar pregnancy.<sup>7,8</sup> While there is no consensus on the best diagnostic criteria, it is generally believed that transvaginal ultrasound is the imaging modality of choice because of its superior resolution. The role of transabdominal ultrasound, which is generally readily available and often the first diagnostic tool, in the diagnosis of Caesarean scar pregnancy is seldom discussed. Few studies in the literature have evaluated the presence of each sonographic criterion in detail. This is a retrospective review study of cases of Caesarean scar pregnancy in a local tertiary institution whose goal is to clarify the imaging features and the diagnostic value of transabdominal and transvaginal ultrasound.

## METHODS

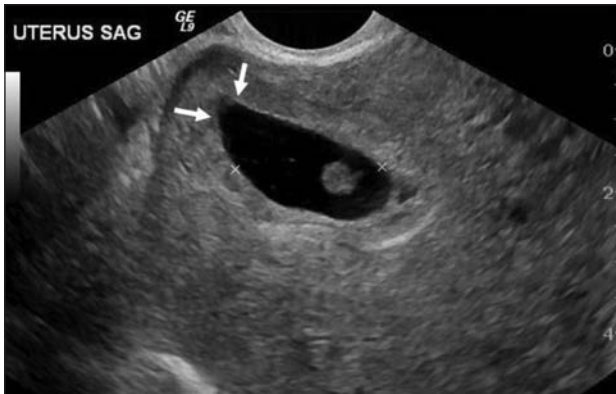### Patients and Diagnoses

We retrospectively identified 16 patients diagnosed with Caesarean scar pregnancy at Queen Mary Hospital, Hong Kong, between 1 March 2010 and 31 February 2015 via keyword search using the terms 'Caesarean scar pregnancy' or 'Caesarean pregnancy' in the Radiological Information System. One patient with heterotopic pregnancy (simultaneous Caesarean scar pregnancy and intrauterine pregnancy) was excluded. Fifteen patients were included in the final analysis.

### Image Acquisition and Analysis

Diagnosis of all cases of Caesarean scar pregnancy was initially made on transvaginal ultrasound, confirmed by clinical and radiological follow-up. At our institution, we begin assessment by transabdominal ultrasound with a full urinary bladder, followed by transvaginal ultrasound.

All transabdominal sonographic images followed by transvaginal scans were reviewed by two radiologists (KHL and GH) by consensus using the Picture Archiving and Communication System for the presence of five sonographic signs: (1) empty uterine cavity; (2) empty endocervical canal; (3) gestational sac embedded in low anterior uterine segment/hysterotomy scar; (4) thin (<3 mm)/absent myometrium between the gestational sac and uterine serosa; and (5) angular appearance of the gestational sac. 'Empty uterus' was defined as visualisation of an empty uterine cavity with a normal endometrial lining, while 'angular appearance of the gestational sac' was defined as formation of an angled anterior border of gestational sac conforming to the shape of niche of the scar (Figure 1). Myometrial thickness was defined as the shortest distance between



**Figure 1.** Transvaginal B-mode ultrasonographic images showing the angled anterior border of the gestational sac (white arrows) conforming to the shape of niche of the scar.

the gestational sac and uterine serosa, excluding any surrounding echogenic decidual reaction (if visible). The above criteria were either adopted from the literature or modified by our group. The viability of pregnancy at the time of presentation was recorded from the reports. If more than one ultrasound examination was performed before the diagnosis, the sonographic images of the first examination were used for analysis.

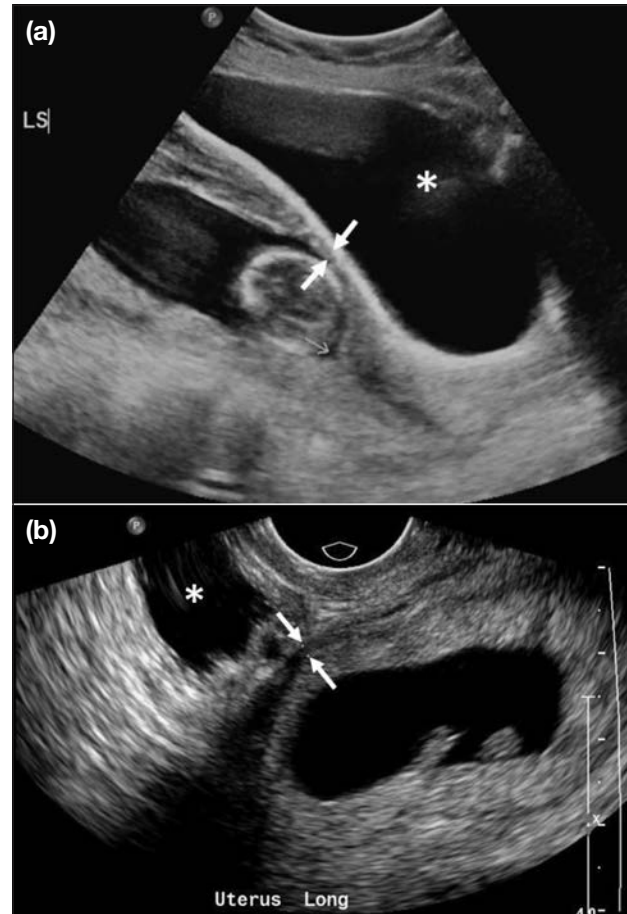
### Statistical Analyses

Statistical analyses were performed using SPSS (Windows version 21.0; IBM Corp., Armonk [NY], United States). The proportion of each sign detected on transabdominal and transvaginal ultrasound was calculated, and the differences were calculated by McNemar's test. A  $p$  value of  $<0.05$  was considered statistically significant.

## RESULTS

### Patient Demographics

Fifteen patients who were diagnosed and treated for Caesarean scar pregnancy had a mean age of 34.5 years (range, 28–40 years). The mean gestational age at presentation was 8 weeks 1 day (range, 4 weeks 5 days to 15 weeks 0 days). The most common presenting symptom was vaginal bleeding ( $n = 13$ , 87%), associated with abdominal pain in five patients. One patient was complicated by uterine rupture, presenting as acute abdomen. Another patient was asymptomatic and incidentally found to have Caesarean scar pregnancy during ultrasound workup before termination of pregnancy. The majority of the patients had had only one previous Caesarean section ( $n = 11$ , 73%), and rest of the patients had had two Caesarean sections. At presentation, 10 pregnancies (67%) had evidence of cardiac activity.



**Figure 2.** (a) Transabdominal and (b) transvaginal B-mode ultrasonographic images showing thin myometrium (white arrows) separating the gestational sac and urinary bladder (asterisks). Note that the layer of echogenic decidual reaction cannot be well depicted by transabdominal ultrasound.

### Ultrasound Features

Transabdominal ultrasound was less sensitive than transvaginal ultrasound at demonstrating thin/absent myometrium between the gestational sac and uterine serosa. Transabdominal ultrasound tends to overestimate the overlying myometrial thickness, demonstrating thin/absent myometrium in three cases (20%), compared with 13 cases (87%) by transvaginal ultrasound (Figure 2), with a statistically significant difference ( $p = 0.002$ ). Transabdominal ultrasound reliably demonstrated thin/absent overlying myometrium in all pregnancies diagnosed at  $>11$  weeks' gestation ( $n = 2$ ).

Angular appearance of gestational sac was seen in 10 cases (67%) by transvaginal ultrasound (Figure 1) but in only five cases (33%) by transabdominal ultrasound. The difference was statistically significant ( $p = 0.031$ ).

**Table.** Presence of sonographic signs in Caesarean scar pregnancy detected during transabdominal and transvaginal ultrasound scans.\*

	Transabdominal ultrasound (n=15)	Transvaginal ultrasound (n=15)	p Value
Empty uterus	8 (53%)	10 (67%)	0.500
Empty endocervical canal	12 (80%)	15 (100%)	0.250
Gestational sac embedded in low anterior uterine segment/hysterotomy scar	13 (87%)	15 (100%)	0.500
Thin/absent (<3 mm) myometrium	3 (20%)	13 (87%)	0.002
Angular appearance of gestational sac	5 (33%)	10 (67%)	0.031

\* Data are shown as No. (%), unless otherwise specified.

The sonographic sign of an empty uterine cavity was demonstrated by transabdominal ultrasound in 8 cases (53%), compared with 10 cases (67%) by transvaginal scan, with no statistically significant difference ( $p = 0.500$ ).

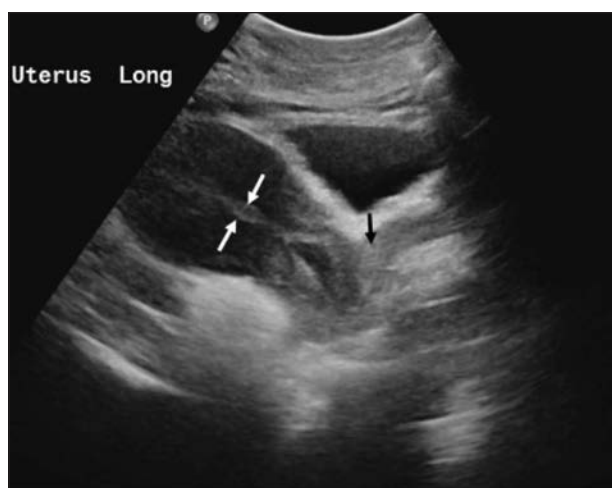
An empty endocervical canal and gestational sac embedded in a low uterine segment/hysterotomy scar were seen in 12 (80%) and 13 (87%) transabdominal cases, respectively, compared with 100% by transvaginal ultrasound. However, the difference was not statistically significant. The proportions of each sonographic sign of Caesarean scar pregnancy by transabdominal and transvaginal ultrasound are shown in the Table.

## DISCUSSION

The visualisation of an abnormally low-lying gestational sac in a previous hysterotomy scar is the most crucial sign in the diagnosis of Caesarean scar pregnancy. Such findings can be best seen by aligning the gestational sac with the mid-sagittal plane of the uterus. Our study has shown that transabdominal ultrasound is reasonably accurate in localisation of a low-lying gestational sac (Figure 3).

However, the location of Caesarean scar pregnancy on transabdominal ultrasound can be confusing, especially if the uterus assumes extreme flexion and/or version. In the case of an extremely anteverted/anteflexed uterus, a low-lying gestational sac can be obscured. This can be improved with sufficient distension of the urinary bladder, which elevates the uterus and reduces anteflexion. In the case of a retroverted uterus, visualisation of the entire endometrial canal may be suboptimal on transabdominal ultrasound,<sup>9,10</sup> resulting in poor localisation of the gestational sac.

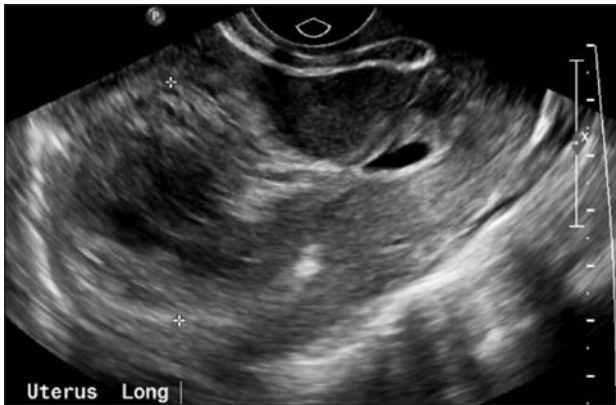
'Empty uterus' was proposed in previous literature as one of the essential diagnostic criteria for Caesarean scar pregnancy.<sup>3,5,11</sup> However, in our series, the uterine



**Figure 3.** Transabdominal B-mode ultrasonographic image showing a low-lying gestational sac embedded in previous hysterotomy scar, associated with an empty uterus (white arrows) and endocervical canal (black arrow).

cavity was filled with either hypoechoic or hyperechoic collections in four patients (Figure 4). Vaginal bleeding was the main presenting symptom in this patient subgroup. Moreover, the intrauterine contents resolved on follow-up scan after non-surgical treatment of Caesarean scar pregnancy. Cignini et al<sup>12</sup> reported a case of Caesarean scar pregnancy with intrauterine fluid collection in the absence of vaginal bleeding. These non-specific intrauterine fluid collections could represent either bleeding at the gestational sac implantation site with retrograde filling of uterine cavity or 'pseudogestational sac', which is a well-documented finding in up to 10% of ectopic pregnancies.<sup>13</sup> This is of particular importance in transabdominal ultrasound evaluation when the low-lying Caesarean scar pregnancy is not resolved well, for example in an extremely anteverted uterus. The intrauterine fluid content could potentially mimic an intrauterine pregnancy (Figure 5). Unlike a normal intrauterine gestational sac, these intrauterine collections should not exhibit any placental flow on Doppler



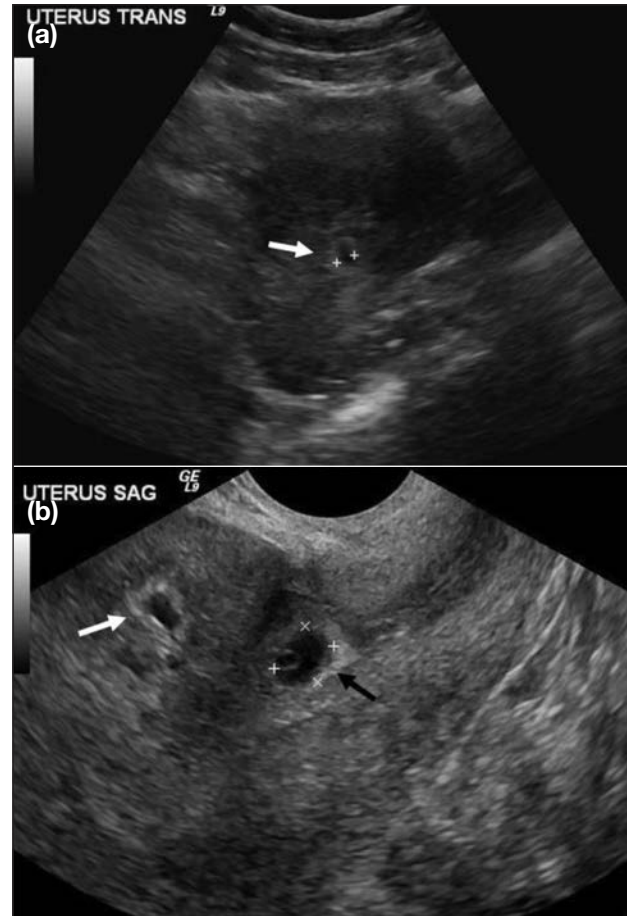


**Figure 4.** Transvaginal B-mode ultrasonographic images of a patient with Caesarean scar pregnancy showing heterogeneously echogenic intrauterine fluid.

imaging. In such circumstances, transvaginal ultrasound is very sensitive in depicting the true gestational sac and distinguishing it from the intrauterine collection. Therefore, the use of ‘empty uterus’ as a diagnostic criterion for Caesarean scar pregnancy should be avoided because it would result in confusing terminology.

Our study also confirms that transabdominal ultrasound is inferior to transvaginal ultrasound at demonstrating thin myometrium overlying the gestational sac. During implantation of blastocyst, there is myometrial invasion by trophoblasts and concomitant decidual reaction of the uterine mucosa in the region of the Caesarean scar, which appears as a layer of echogenicity around the gestational sac. Because of resolution limitations, the echogenic decidual reaction is often not seen well on transabdominal images; hence, the myometrial thickness overlying the gestational sac tends to be overestimated. Interestingly, transabdominal ultrasound was able to demonstrate a thin/absent myometrium overlying the gestational sac in all pregnancies ( $n = 2$ ) diagnosed at >11 weeks’ gestation. This is related to the progressive thinning of the myometrium at the lower uterine segment. On transvaginal ultrasound, 13 patients had an overlying myometrial thickness of <3 mm, with the remaining two had <5 mm. In the presence of a low-lying gestational sac, using a cut-off of 5 mm for the overlying myometrial thickness for diagnosis of Caesarean sac pregnancy seems to be reasonable.

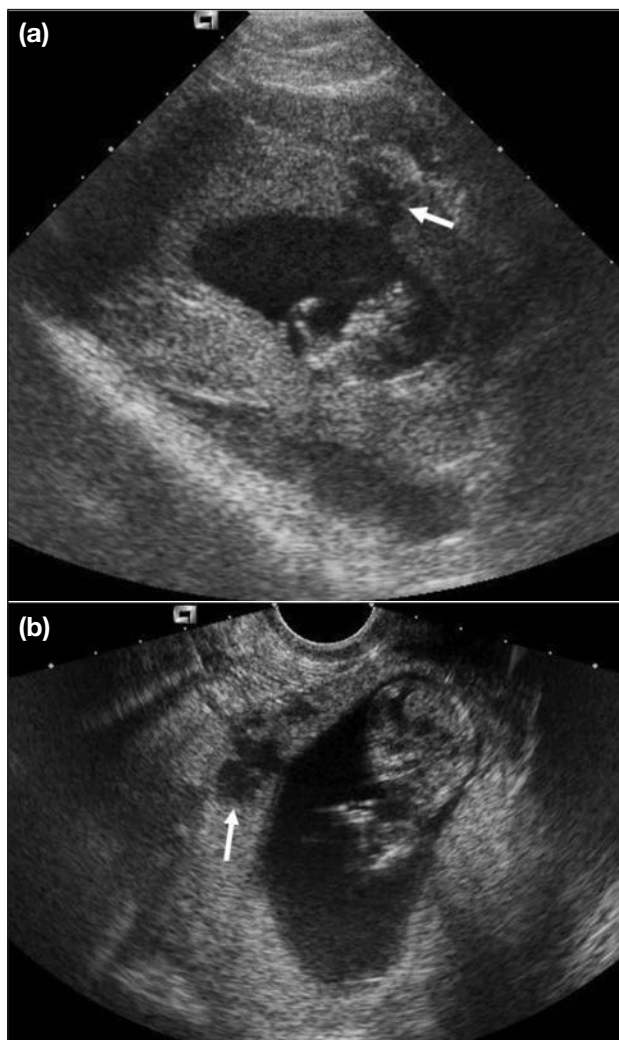
In the patient complicated by uterine rupture, the site of uterine rupture could be demonstrated by both transabdominal and transvaginal ultrasound, which presented as a linear hypoechoic defect at the lower



**Figure 5.** (a) Transabdominal and (b) transvaginal B-mode ultrasonographic images of Caesarean scar pregnancy in a very anteverted uterus. The gestational sac is only seen on transvaginal ultrasound (black arrow). Sac-like fluid collection is seen within the uterine cavity on transvaginal ultrasound, mimicking the gestational sac on transabdominal ultrasound (white arrows).

uterine wall at the site of implantation (Figure 6). Other findings included hemoperitoneum, with echogenic fluid seen in the Morrison’s pouch and the pouch of Douglas.

Doppler imaging has been reported to be useful in the diagnosis of Caesarean scar pregnancy. Abundant peritrophoblastic blood flow should be present around the gestational sac in colour Doppler imaging, with low impedance (pulsatility index >1), high velocity flow (>20 cm/s), a resistive index of <0.5, and a peak systolic to diastolic blood flow ratio of <3.<sup>14,15</sup> In our study, we have not performed comparative analysis including colour Doppler imaging because spectral analysis is not part of our imaging protocol. We did observe the presence of rich vascular flow around gestational sacs implanted at hysterotomy scars in the majority of our patients, best seen on transvaginal images. However, in our case series,



**Figure 6.** In a patient with Caesarean scar pregnancy complicated by uterine rupture, (a) transabdominal and (b) transvaginal B-mode ultrasonographic images demonstrate linear hypoechoic defects (white arrows) in the low anterior uterine wall overlying the gestational sac.

such findings did not provide additional information regarding the diagnosis of Caesarean pregnancy when other sonographic features were present. Other authors have concurred in the literature.<sup>16</sup>

Our study has several limitations. First, we did not address the specificity of transabdominal and transvaginal ultrasound diagnosis of pregnancy. Second, the power of the study is undermined by its small sample size. Third, in some of our patients, surgical or pathologic proof of Caesarean scar pregnancies was not available, as they were treated non-surgically. In addition, because of the retrospective nature of our study, the diagnostic value

of transabdominal ultrasound could be underestimated because some operators may have assumed the inferiority of transabdominal ultrasound and directly proceeded to transvaginal ultrasound before searching for every sonographic sign on transabdominal scans. Still, we have identified the strengths and diagnostic pitfalls of transabdominal ultrasound in evaluation of patients with suspected Caesarean scar pregnancy. We have also clarified its sonographic features on transvaginal ultrasound. In any patient with prior Caesarean section, a combination of low-lying gestational sac, thin overlying myometrium (<5 mm), and empty endocervical canal is highly indicative of Caesarean pregnancy.

## CONCLUSION

Caesarean scar pregnancy is not uncommon and is potentially life-threatening in any pregnant woman with a history of Caesarean section. A high index of suspicion is needed to make the correct diagnosis. With the potential diagnostic pitfalls and pearls in mind, transabdominal ultrasound remains a useful imaging tool and a helpful adjunct to transvaginal ultrasound in diagnosis of Caesarean scar pregnancy.

## REFERENCES

1. Fylstra DL. Ectopic pregnancy within a Cesarean scar: a review. *Obstet Gynecol Surv.* 2002;57:537-43. [Crossref](#)
2. Ash A, Smith A, Maxwell D. Cesarean scar pregnancy. *BJOG.* 2007;114:253-63. [Crossref](#)
3. Osborn DA, Williams TR, Craig BM. Cesarean scar pregnancy: sonographic and magnetic resonance imaging findings, complications, and treatment. *J Ultrasound Med.* 2012;31:1449-56. [Crossref](#)
4. Rosen T. Placenta accreta and Cesarean scar pregnancy: overlooked costs of the rising Cesarean section rate. *Clin Perinatol.* 2008;35:519-29, x. [Crossref](#)
5. Jurkovic D, Hillaby K, Woelfer B, Lawrence A, Salim R, Elson CJ. First-trimester diagnosis and management of pregnancies implanted into the lower uterine segment Cesarean section scar. *Ultrasound Obstet Gynecol.* 2003;21:220-7. [Crossref](#)
6. Rotas MA, Haberman S, Levгур M. Cesarean scar ectopic pregnancies: etiology, diagnosis, and management. *Obstet Gynecol.* 2006;107:1373-81. [Crossref](#)
7. Seow KM, Hwang JL, Tsai YL. Ultrasound diagnosis of a pregnancy in a Cesarean section scar. *Ultrasound Obstet Gynecol.* 2001;18:547-9. [Crossref](#)
8. Vial Y, Petignat P, Hohlfield P. Pregnancy in a Cesarean scar. *Ultrasound Obstet Gynecol.* 2000;16:592-3. [Crossref](#)
9. Coleman BG, Arger PH, Grumbach K, Menard MK, Mintz MC, Allen KS, et al. Transvaginal and transabdominal sonography: prospective comparison. *Radiology.* 1988;168:639-43. [Crossref](#)
10. Kaur A, Kaur A. Transvaginal ultrasonography in first trimester of pregnancy and its comparison with transabdominal ultrasonography. *J Pharm Bioallied Sci.* 2011;3:329-38. [Crossref](#)
11. Timor-Tritsch IE, Monteagudo A, Santos R, Tsybal T, Pineda G, Arslan AA. The diagnosis, treatment, and follow-up of Cesarean scar pregnancy. *Am J Obstet Gynecol.* 2012;207:44.e1-

13. [Crossref](#)
12. Cignini P, Giorlandino M, Caserta L, Dominici L, Giorlandino C. The importance of early diagnosis in Cesarean scar pregnancy. *J Prenat Med.* 2007;1:29-31.
13. Bhatt S, Ghazale H, Dogra VS. Sonographic evaluation of ectopic pregnancy. *Radiol Clin North Am.* 2007;45:549-60, ix. [Crossref](#)
14. Jurkovic D, Hillaby K, Woelfer B, Lawrence A, Salim R, Elson CJ. Cesarean scar pregnancy. *Ultrasound Obstet Gynecol.* 2003;21:310. [Crossref](#)
15. Weimin W, Wenqing L. Effect of early pregnancy on a previous lower segment Cesarean section scar. *Int J Gynaecol Obstet.* 2002;77:201-7. [Crossref](#)
16. McKenna DA, Poder L, Goldman M, Goldstein RB. Role of sonography in the recognition, assessment, and treatment of Cesarean scar ectopic pregnancies. *J Ultrasound Med.* 2008;27:779-83. [Crossref](#)