
ORIGINAL ARTICLE

Gastrointestinal Stromal Tumours — A Retrospective Study of the Clinical, Endoscopic, and Computed Tomographic Features

HKF Mak,¹ CMY Leung,¹ CW Chan,² JWC Ho,³ KKO Mak,¹ KCW Wong¹

¹Department of Diagnostic Radiology, ²Department of Medicine, ³Department of Pathology, Yan Chai Hospital, Hong Kong

ABSTRACT

Objective: To evaluate the clinical, endoscopic, and computed tomographic findings of gastrointestinal stromal tumours.

Patients and Methods: Twenty-five patients with the pathological diagnosis of gastrointestinal stromal tumours seen at Yan Chai Hospital over a period of 5 1/2 years were included in the study. A retrospective review of patient records, endoscopy and computed tomographic findings, and pathological reports was conducted.

Results: Gastrointestinal stromal tumours most commonly were seen in patients over 40 years (range 35 to 87 years). The most common sites of origin were the stomach and small bowel (64% and 24%, respectively) and the most common presenting symptom was gastrointestinal bleeding (80%). Gastrointestinal stromal tumours were seen on endoscopy as pedunculated or sessile intraluminal masses with smooth mucosa, or less often as bulging submucosal masses in the lumen and rarely as malignant ulcer. Tumours smaller than 5 cm had benign computed tomographic features such as spherical shape, smooth margin, and homogeneous attenuation and enhancement, whereas those larger than 5 cm showed aggressive features such as irregular shape, mucosal ulceration, and heterogeneous attenuation and enhancement.

Conclusions: The clinical and endoscopic features of gastrointestinal stromal tumours seen in this series were similar to previous reports, with the exception of gastrointestinal bleeding being the most common presentation. Gastrointestinal stromal tumours larger than 5 cm were associated with aggressive computed tomography features.

Key Words: Angiography, Computed tomography, Endoscopy, Leiomyoblastoma, Leiomyoma, Leiomyosarcoma

INTRODUCTION

Gastrointestinal stromal tumours (GISTs) are the subject of much debate and controversy regarding their histogenesis, criteria for diagnosis, prognostic features, and nomenclature.^{1,2} Formerly grouped with leiomyomas, leiomyoblastomas, or leiomyosarcomas, GISTs are mesenchymal (non-epithelial) tumours that are composed of spindle or epithelioid cells and are divided into five major categories according to their differentiation towards smooth muscle cells, neural elements, mixed smooth muscle and neural elements,

and Cajal cell-like and undifferentiated forms.^{1,3} Recent studies also suggest that GISTs have unique histological, immunophenotypic, and molecular genetic features that set them apart from typical smooth muscle tumours and schwannomas.⁴

The imaging features of GISTs have not been thoroughly described in the literature^{5,6,7,8} and are frequently confused with smooth muscle tumours (such as leiomyomas and leiomyosarcomas). The role of imaging extends beyond the realm of diagnosis, assisting in assessment of the biological behaviour of this tumour, since it is often difficult to distinguish malignancy purely by histopathology or immunohistochemistry.^{2,4} This study reviews the clinical, endoscopic, and computed tomographic features of this rare tumour as seen in patients treated at Yan Chai Hospital and compares this Hong Kong data with published studies.

Correspondence: Dr. HKF Mak, Department of Diagnostic Radiology, Yan Chai Hospital, 7-11 Yan Chai Street, Tsuen Wan, Hong Kong.

Tel: (852) 2417 8294; Fax: (852) 2416 7035;

E-mail: makkf@ha.org.hk

Submitted: 14 December 2001; Accepted: 8 March 2002.

METHODS

A total of twenty-five patients with a diagnosis of GIST seen at Yan Chai Hospital (700 beds) between September 1995 to February 2001 were identified using the Pathology Department database. A further GIST was identified in a patient who initially presented with a large gastric tumour and was found to have a concurrent small ileal GIST intraoperatively. Pathologic diagnosis of GIST was made using a combination of light microscopy, immunohistochemistry, and ultrastructural (electron microscopy) techniques. Prognostic indicators such as mitotic figures, cellular atypia, and tumour size were routinely documented.

Of the 26 GISTs, two showed predominant smooth muscle differentiation (both were located in the stomach), six showed predominant neural differentiation (two were in the stomach, three in the small bowel, and one in the omentum), a further six showed uncommitted differentiation (all were in the stomach), and twelve cases were mixed and inconclusive. Retrospective review of the clinical records, endoscopy results, and imaging studies was conducted. Preoperative evaluation of the patients included a combination of one or more of the following imaging modalities: endoscopy, CT, and digital subtraction angiography (DSA). Demographic data, clinical presentation, and patient outcomes were recorded. Imaging findings were reviewed by consensus of at least two radiologists and endoscopic findings were interpreted by a gastroenterologist.

RESULTS

Clinical Presentation

The median age of the patients was 66 years (range 35 to 87 years); 14 were men and 11 women. Tumours were most commonly located in the stomach (16 patients, 64%), followed by the small intestine (7 patients, 24%), and less commonly the oesophagus (1 patient, 4%), the colon (1 patient, 4%) and the omentum/mesentery (1 patient, 4%). Gastrointestinal bleeding was the most common presenting symptom (80%), followed by abdominal pain (36%), and the presence of an abdominal mass (14%).

Endoscopic Findings

For patients with gastroesophageal and colorectal tumours presenting with gastrointestinal bleeding, the primary mode of investigation was endoscopy. Of 16 patients with gastric stromal tumours, 15 underwent upper endoscopy (OGD), with the lesion successfully

identified in 14 (93.33%) patients. OGD failed to identify tumour features intraluminally in one (6.67%) patient, as a result of exophytic tumour growth. In this series, gastric GISTs were most commonly found in the gastric fundus (7 cases). Other locations included the gastric body (5 cases) and the antrum (2 cases). The most common endoscopic finding in the stomach was of a round tumour mass, either pedunculated or sessile, with smooth mucosa resembling a leiomyoma. When the tumour size was large, the appearance was of a submucosal mass bulging into the lumen. One tumour had an everted and irregular edge, resembling a malignant gastric ulcer. The sole esophageal GIST appeared on OGD as a malignant-looking ulcerative growth in the oesophagus extending 35 cm to 40 cm. Colonoscopy was the initial investigation in one patient who presented with bleeding per rectum. A 7 mm colonic polypoid GIST was identified in the sigmoid colon and removed with a snare. Table 1 provides a summary of the endoscopic findings and size of the tumours measured from the surgical specimens.

Computed Tomography

In total, 12 patients had preoperative CT performed and ten had positive CT findings — five with stomach tumours, three with small bowel tumours, one with an oesophageal tumour, and one with a tumour in the omentum. The CT abdomen findings are summarised in Table 2. The two negative findings (one in a patient with a colon tumour and one in a patient with a stomach tumour) were due to the small tumour size (<1 cm). A wide range in tumour size overall was detected, from 2 cm to 24 cm (average 9.7 cm). The CT imaging findings could be classified into two groups. The first group (3 cases) comprised smaller tumours, ranging from 2 cm to 5 cm in size. The tumours were found in the stomach, and were well-circumscribed and spherical or ovoid in shape. The intraluminal portions were

Table 1. Summary of endoscopic findings and tumour size measured from surgical specimens (n=26).

Location	Endoscopic finding	No. of patients	Tumour size (cm)
Stomach	Mass	8	1-7
	Bulge	1	22
	Ulcer	5	0.6-10
	Normal	1	24
	Not done	1	5.8
Oesophagus	Ulcer	1	*
Colon	Sigmoid polyp	1	1.2
Omentum	Normal	1	5.5
Small bowel	Normal	2	5.5-6
	Not done	4	4.5-9

* No surgery performed.

Table 2. Summary of CT abdomen findings.

Case	Age/Sex	Location	Size (cm)	Heterogeneity*	Mucosal ulceration	Metastasis
1	M/46	Jejunum	7	+	-	-
2	M/65	Omentum	10	+	-	Liver
3	M/70	Jejunum	5	+	-	-
4	F/62	Jejunum	20	+	+	-
5	F/65	Stomach	24	+	+	Body wall
6	F/72	Stomach	2	-	-	-
7	F/87	Stomach	5	-	-	-
8	M/80	Stomach	4	-	-	-
9	F/80	Oesophagus	13	+	+	-
10	M/80	Stomach	4	-	+	-

* Central necrosis, irregular outline, peripheral soft tissue enhancement.

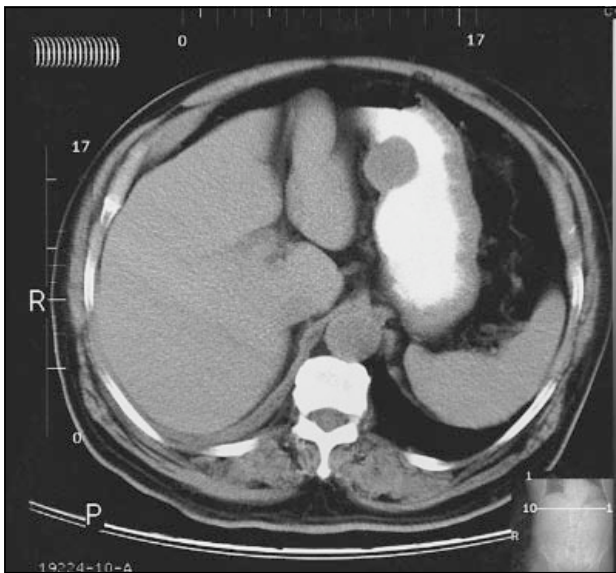


Figure 1. Intraluminal gastric stromal tumour. CT abdomen with oral contrast shows a small (2 cm) intraluminal, rounded tumour with a broad base and a smooth convex margin.

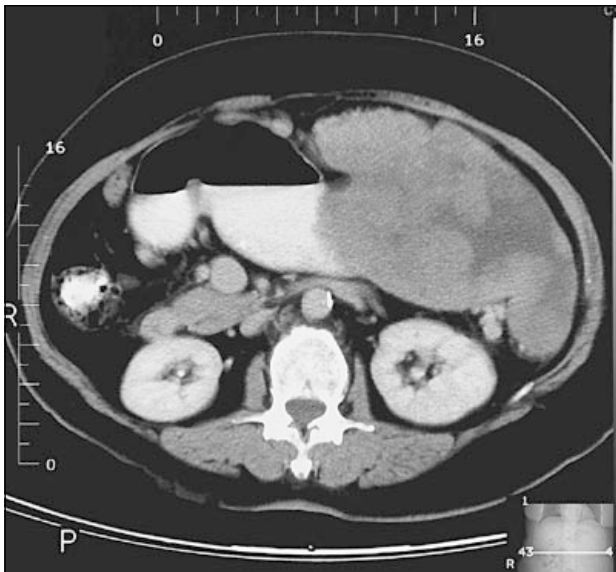


Figure 2. Exophytic gastric stromal tumour in a 65-year-old woman presenting with a palpable left abdominal mass and gastrointestinal bleeding. CT abdomen revealed a large exophytic mass along the greater curvature of the stomach.

seen as pedunculated nodules with smooth convex margins (Figure 1). They showed similar attenuation to that of muscle, with a small to moderate exophytic component. The lesions were homogeneous in density and moderately contrast-enhancing. No invasion of adjacent organs or distant metastases was seen. The second group (7 cases) comprised tumours larger than 5 cm (ranging from 5.5 cm to 24 cm) and were predominantly exophytic. They were heterogeneous lobulated masses of irregular shape, with central zones of low density (necrosis), surrounded by variable soft tissue thickness (Figure 2). Detection of air-fluid level or oral contrast within excavation (Figure 3) was an indication of gut origin (seen in 3 cases). The peripheral soft tissue components showed moderate enhancement. Signs of advanced disease included mucosal ulceration and invasion of adjacent structures

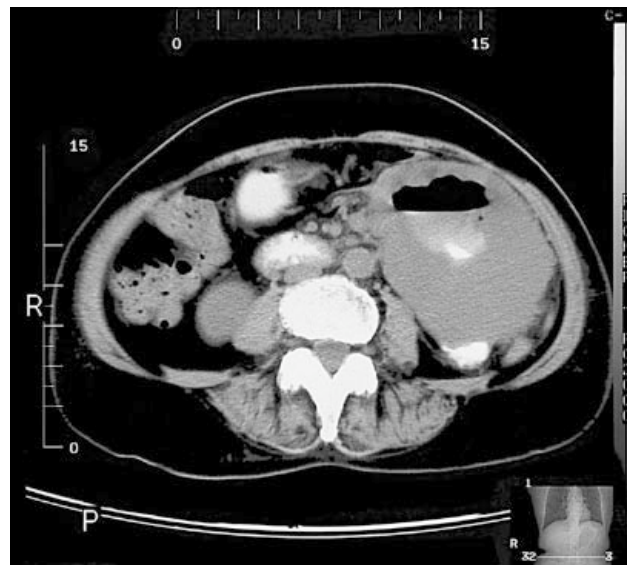


Figure 3. Contrast-enhanced CT abdomen of this 62-year-old woman was performed because of left flank pain and an abdominal mass. An air-fluid level and oral contrast within excavation of a large heterogeneous mass were seen in the left side of the abdomen, indicating communication of the mass with the gut lumen through deep ulceration. The CT diagnosis of small bowel stromal tumour was confirmed on surgery.

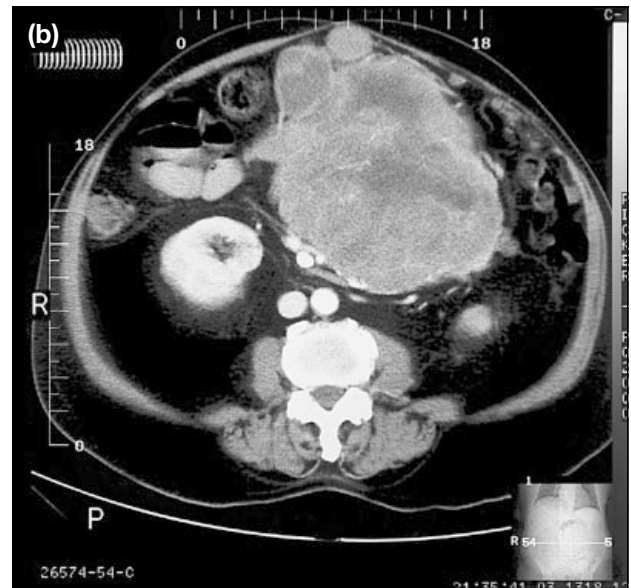
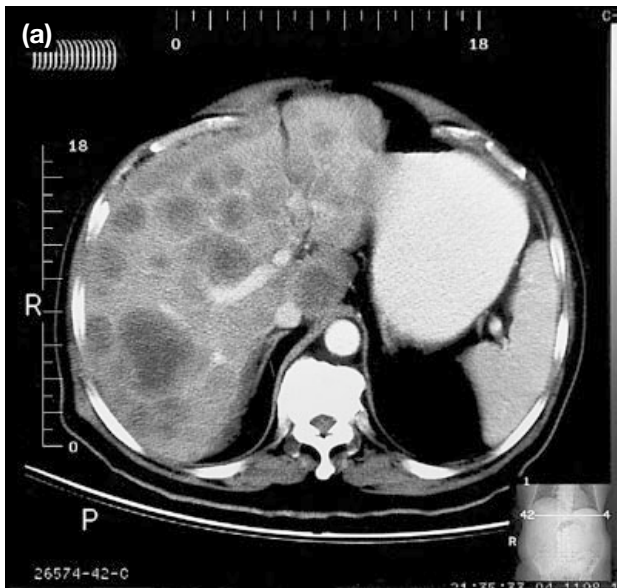


Figure 4. Omental stromal tumour with liver metastases. This 65-year-old man with peritonitis was found at laparotomy to have a ruptured omental stromal tumour. Rapid local recurrence with invasion of mesenteric vessels occurred postoperatively. Contrast-enhanced CT abdomen 18 months later shows (a) multiple rim-enhancing hypodense nodules in the liver and (b) a large primary tumour in the central abdomen.

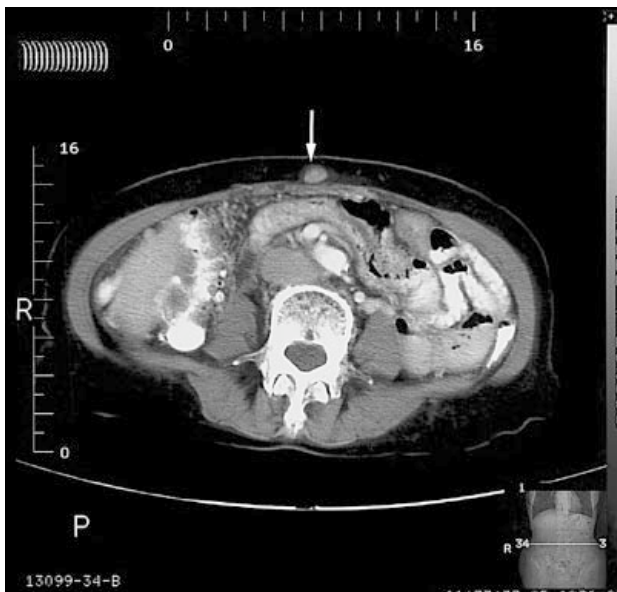


Figure 5. Abdominal wall metastasis secondary to a gastric stromal tumour. The patient (see Figure 2) had a gastric stromal tumour surgically excised two years before noticing a vague abdominal wall nodule just above the umbilicus. Contrast-enhanced CT abdomen confirmed a small (1 cm) subcutaneous soft tissue density nodule but no local recurrence (white arrow). The nodule was later excised and confirmed pathologically to be metastatic sarcoma.

such as the pancreas, spleen or superior mesenteric vessels, or the omentum/mesentery. Metastatic disease was found in two patients (Figures 4 and 5), either as multiple nodular deposits in the omentum; mesentery, rim-enhancing hypodense masses in the liver (Figure 4a); or small satellite nodules in the abdominal wall

(Figure 5). Of note, there was no calcification detected in these 10 cases.

CT was also seen to assist angio-graphic detection of a bleeding small bowel stromal tumour. A 70-year-old man presenting with recurrent gastrointestinal bleeding but negative OGD and colonoscopy was readmitted with shock. Urgent DSA with superior mesenteric artery injection (Figure 6a) showed a hypervascular tumour of moderate size (4 to 5 cm). In this case, added sensitivity to contrast extravasation was obtained by performing preangiography (Figure 6b) and postangiography (Figures 6c and 6d) plain CT of the abdomen.

DICUSSION

Most gastric and small intestinal mesenchymal tumours belong to the category of GISTs, whereas typical leiomyomas, leiomyosarcomas, and schwannomas are rare in these locations. Thus, data on gastrointestinal smooth muscle tumours largely reflects the features of GISTs.⁴ GISTs occur predominantly in persons over 40 years of age, with an equal sex incidence. They are most commonly found in the stomach (65% of cases), followed by the small bowel (30 to 35%), and are rare in the oesophagus, colon, and rectum.⁴ A similar pattern of distribution was observed in this study.

According to the literature, symptomatic presentation includes abdominal pain (40 to 50%), gastrointestinal bleeding (melena or less commonly haematemesis,

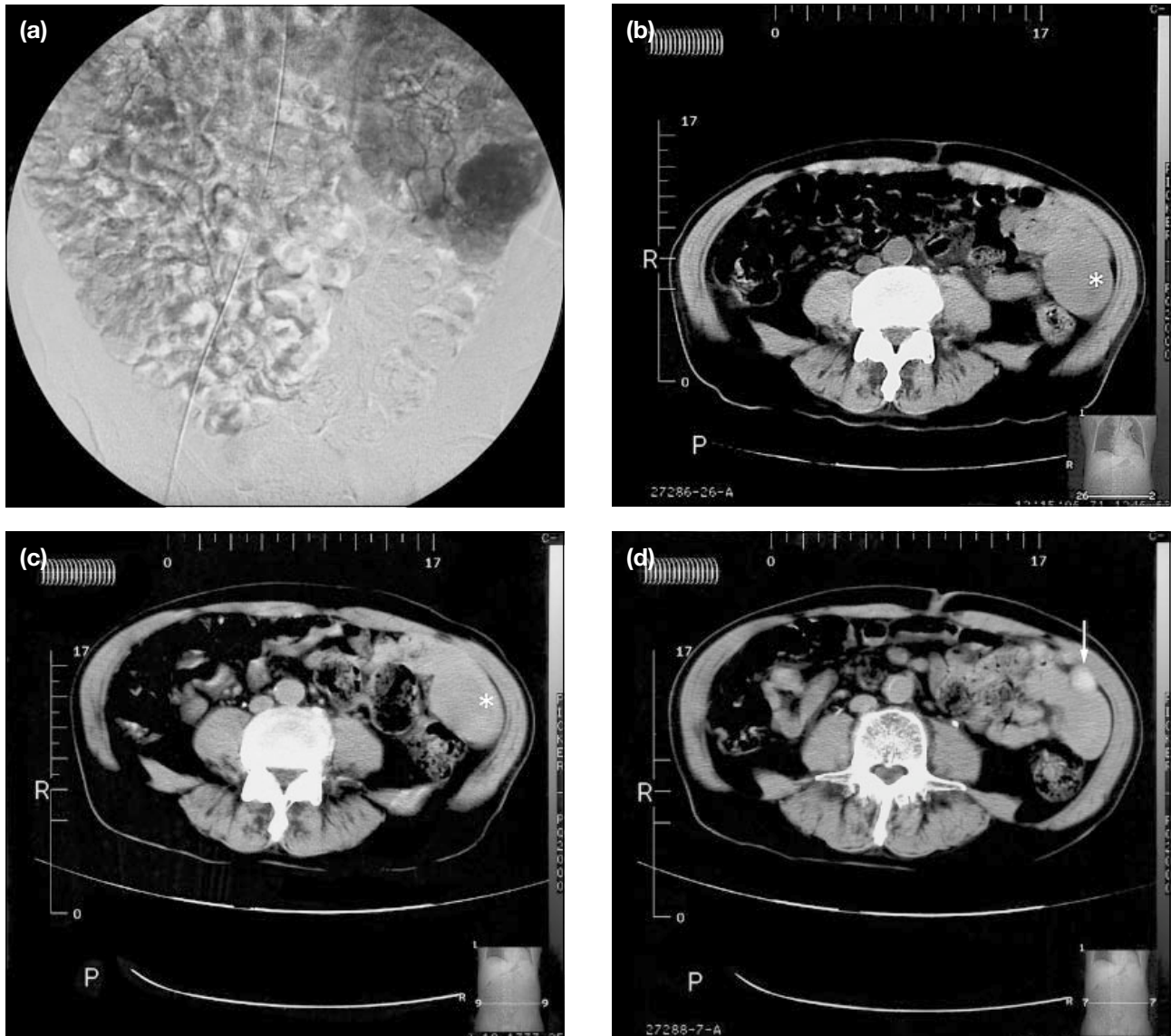


Figure 6. (a) Angiographic appearance of a small bowel stromal tumour; (b) plain CT abdomen scans prior to angiography shows a soft tissue mass in the left lower abdomen (white asterisk) suggestive of a small bowel tumour; (c) postangiography plain CT abdomen shows a heterogeneous soft tissue mass (white asterisk); and (d) contrast extravasation into the small bowel loop (white arrow). Surgery confirmed the presence of a small bowel stromal tumour protruding into gut lumen.

20 to 50%), or a palpable mass (25 to 40%).⁴ However, gastrointestinal bleeding was the predominant symptom (80% of cases) in this series. GISTs can grow into (endocentric) or away from (exocentric) the lumen, presenting as intraluminal, submucosal, or subserosal lesions. The tumours in this series developed in the submucosal layers. As a result, endoscopy had a tendency to underestimate their size, particularly in those large tumours with a sessile appearance. In such cases, computed tomography helps to delineate the extent of the tumours. Deep biopsy confirmed the nature of the tumour, reflecting the fact that these tumours were usually deep-seated beneath the mucosa.¹ CT patterns for GISTs have been previously described,^{5,7,8} though

terminology such as leiomyoma and leiomyosarcoma were used. This reflected the traditional classification of gastrointestinal mesenchymal tumours which did not distinguish GISTs. Therefore, overlap between GISTs and smooth muscle tumours occurred in the literature.

In this study, tumours larger than 5 cm were associated with central necrosis, an irregular shape, heterogeneous enhancement, and mucosal ulceration. These findings have been described as malignant features by most authors.^{5,7,8} Interestingly, this same tumour size is viewed as an uncertain pathologic diagnosis in terms of malignant potential.^{2,4} Calcification is an uncommon feature of GISTs and was not found in this series. If

calcification is seen, a smooth muscle tumour such as leiomyoma or leiomyosarcoma is a more likely diagnosis. Metastatic disease was only seen when tumours were greater than 10 cm in size in this series. However, the number of patients in this study was small. According to the literature, approximately 10% of all GISTs display malignant behaviour and a similar figure was seen in this study. Histological features, such as mitotic figures or cellular atypia, do not correlate well with the development of recurrence or metastasis. Some tumours may metastasise even with mitotic activity <1/10 high power field, especially those larger than 5 cm.⁴ CT can evaluate the biological behaviour of GISTs in advanced disease, since extra-gastrointestinal spread and uncontrolled local recurrence are definite proof of malignancy.

In the evaluation of GISTs in this study it was noted that:

- 1) OGD and colonoscopy are sensitive in detecting intraluminal GISTs and should be the first line investigation.
- 2) CT complemented endoscopy in specific aspects.
 - a. Exophytic (submucosal or subserosal) gastroesophageal tumours were commonly underestimated by endoscopy, with CT superior in determining their extent and relationship to adjacent organs, as well as the presence of distant metastases.
 - b. Patients with small bowel and omental stromal tumours presented with an abdominal mass or pain, but OGD and colonoscopy findings tended to be negative.
 - c. In patients with mild or intermittent gastrointestinal bleeding suggestive of small bowel tumour (after negative endoscopy findings), CT would appear the most appropriate next

investigation. Barium study, even small bowel enema, may miss exophytic masses and a Tc-99m red blood cell scan often cannot localise the site of bleeding or may be negative if bleeding is intermittent.

- d. Pre- and postangiography plain CT scans may have a role in detecting slow contrast extravasation in bleeding GISTs.

In summary, the majority of patients seen at Yan Chai Hospital with GISTs presented with gastrointestinal bleeding (80%). Clinical and endoscopic features of GISTs were otherwise similar to reported studies. It was also noted that GISTs larger than 5 cm were associated with aggressive features on CT. This has not been emphasised in the radiologic literature to date. The limitations of this study included the small number of patients who underwent CT prior to surgery. A larger prospective study is necessary to validate our findings.

REFERENCES

1. Boland CR, Savides TJ. Tumours of the stomach. In: Yamada T, ed. Textbook of gastroenterology. 3rd ed. Philadelphia: Lippincott-Raven; 1999:1522-1523.
2. Fenoglio-Preiser CM, Noffsinger AE, Stemmermann GN, et al. Gastrointestinal pathology — An atlas and text. 2nd ed. Philadelphia: Lippincott-Raven; 1999:1169-1213.
3. Wong LS, Rusby J, Bassi UA, Rowlands D, Ismail T. Stromal tumour of the small bowel. *J R Soc Med*, 2000;93:145-146.
4. Miettinen M, Sarlomo-Rikala M, Lasota J. Gastrointestinal tumours. *Ann Chir Gynaecol* 1998;87:278-281.
5. Buckley JA, Fishman EK. CT evaluation of small bowel neoplasms: spectrum of disease. *Radiographics* 1998;18:379-392.
6. Tervahartala P, Halavaara J. Radiology of GIST. *Ann Chir Gynaecol* 1998;87:291-292.
7. Koehler RE, Memel DS, Stanley RJ. Gastrointestinal tract. In: Lee JK, ed. Computed body tomography with MRI correlation. 3rd ed. Philadelphia: Lippincott-Raven; 1998:648-653.
8. Megibow AJ, Balthazar EJ, Hulnick DH, Naidich DP, Bosniak MA. CT evaluation of gastrointestinal leiomyomas and leiomyosarcomas. *AJR Am J Roentgenol* 1985; 144:727-731.