

---

## HOW I DO IT

---

# Superselective Arterial Angiography and Embolization for Post-traumatic Priapism

N Al-Nakshabandi,<sup>1</sup> S Lingawi,<sup>2</sup> L Marchinkow,<sup>1</sup> PL Munk,<sup>1</sup> C Morris,<sup>1</sup> G Legiehn,<sup>1</sup> S Ho<sup>1</sup>

<sup>1</sup>Department of Radiology, Vancouver General Hospital, University of British Columbia, Vancouver, Canada, and <sup>2</sup>Department of Radiology, King Abdulaziz University Hospital, Jeddah, Saudi Arabia

### ABSTRACT

*Superselective arterial angiography and embolization for post-traumatic priapism is an established procedure for the control of priapism refractory to conservative measures and medication. For the pre-procedure assessment, cavernosal aspiration of blood is used to measure oxygen. Doppler ultrasound could be performed but is not a prerequisite. The procedure is always performed using local anaesthesia together with intravenous sedation and analgesia. A pigtail catheter is used to perform a pelvic angiogram and a Cobra CI catheter used to perform a contralateral common iliac and selective internal iliac arteriography. A tracker catheter may be required for cannulation of the internal pudendal artery and gelatin sponge torpedoes are deployed at the site of the arteriovenous fistula. A follow up angiogram is performed to confirm a satisfactory result.*

*Key Words:* Interventional, Priapism, Radiography, Therapeutic embolization

### INTRODUCTION

Prolonged non-sexual penile erection (often with pain) is termed priapism.<sup>1</sup> Priapism is classified as either low-flow veno-occlusive (ischaemic) priapism commonly seen in patients with infiltrative disorders such as sickle cell anaemia or leukaemia, or as a high-flow non-ischaemic post-traumatic arterio-venous fistula type, which is far less common than the former.<sup>1,2</sup> This review is of the management of post-traumatic priapism.

### CONVENTIONAL TREATMENT

A trial of conservative management should initially be undertaken. Patients receive oxygen via prongs, and ice pads placed and wrapped around the penis increasing the arterial oxygen saturation. This is particularly useful for the ischaemic type of priapism.<sup>3</sup> Medications such as the  $\alpha$ -adrenergic agonist phenylephrine directly affect the  $\alpha$ -adrenergic receptors.<sup>4</sup> This constricts resistance and capacitance of blood vessels, increasing

the total peripheral resistance, resulting in increased systolic and diastolic blood pressure. A dose of 250 to 500 mcg intravenously (IV) or intracorporally every 5 minutes is administered until detumescence occurs — this may be repeated up to 3 times, but is only helpful in the first 12 hours after onset.

Intravenous methylene blue, when given IV or intracorporally, oxidises the iron of reduced haemoglobin to the ferric state, counteracting the release of nitric oxide, which promotes ischaemia in the cells.<sup>4</sup> This has been found to be helpful for the treatment of traumatic high-flow priapism.

Colour flow duplex-guided compression of the penis can be a useful diagnostic tool, as it allows confirmation of high-flow priapism secondary to an arteriovenous fistula, and is a therapeutic tool via compression of the pseudoaneurysm/arteriovenous fistula until thrombosis is achieved.<sup>5</sup> Ultrasound is operator dependent, and can be time consuming.

The surgical creation of a cavernosal pudendal shunt or ligation of the pudendal artery has been done<sup>6</sup> and involves effecting a decrease in arterial supply to the corpora. Surgery is rarely performed at present.

---

*Correspondence:* Dr PL Munk, Department of Radiology, Vancouver General Hospital, 899 W 12th Ave, Vancouver, BC, V5Z 1M9, Canada.

Tel: (604) 875 4533; Fax: (604) 875 4723;

E-mail: plmunk@interchange.ubc.ca

Submitted: 7 October 2002; Accepted: 6 May 2003.

Radiological intervention by means of embolization of the internal pudendal artery is now the mainstay of management of this condition when conservative therapy fails. The first attempt to approach the management of priapism using embolization was described by Wear et al in 1977.<sup>9</sup>

A variety of different agents have been used for embolization. The use of an autologous clot permits rapid restoration of blood supply after clot lysis, theoretically decreasing the chances for long term erectile dysfunction.<sup>7-10</sup> The use of gel foam for embolization of the internal pudendal artery and/or one of its branches is the preferred method. Gel foam is widely available, relatively cheap, and readily injected through 5 F catheters. Occlusion lasts for 4 weeks and recanalization of the occluded vessel is usual.<sup>3,7,10</sup>

The use of Microcoils (embolization coils 3 mm in diameter, 4 cm in length; Cook Inc, Bloomington, USA) has the advantage of being radiopaque, facilitating visualisation, and can be introduced through microcatheters. However, this method produces permanent occlusion and is relatively expensive.<sup>9,11,12</sup> The use of N Butyl-Cyanoacrylate (NBCA; Hisoacryl Blau, Braun, Melsungen, Germany) has the advantage of being liquid which allows it to be introduced through microcatheters. NBCA adheres firmly to the surrounding endothelium, resulting in a permanent arterial occlusion. This procedure is technically demanding.<sup>7,13</sup>

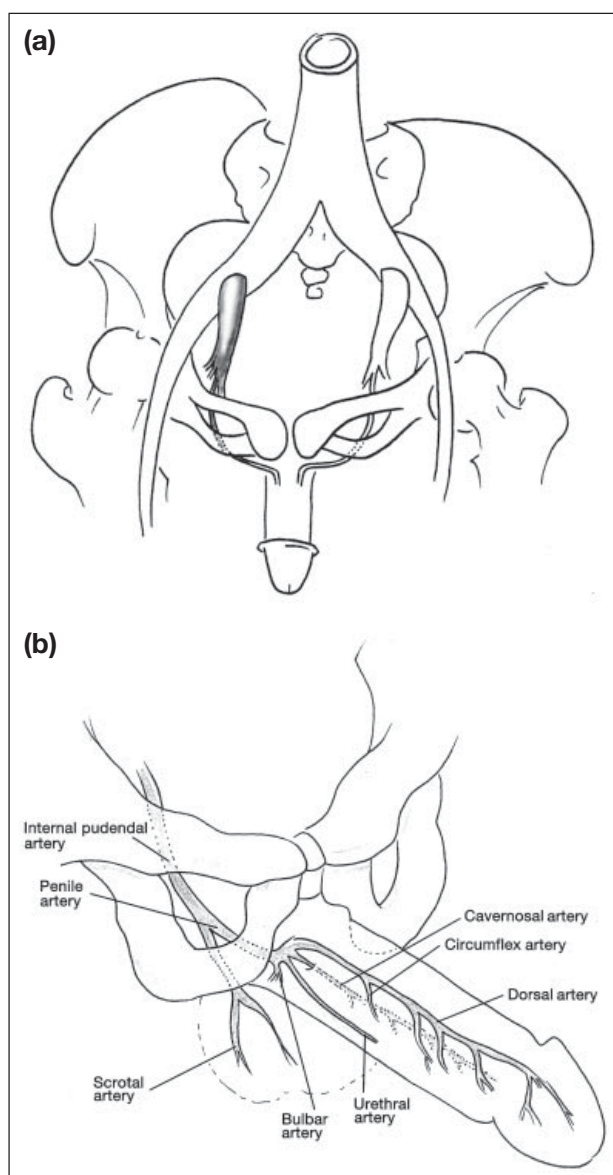
### ANATOMY OF THE PENILE CIRCULATION WITH POTENTIAL VARIANTS

The arterial supply to the penis usually comes from the common penile artery that arises from the internal pudendal artery. This, in turn, is a branch of the inferior epigastric artery originating from the internal iliac artery. The internal pudendal artery runs downwards and laterally to the lower part of the rim of the greater sciatic foramen, curves around the back of the ischial spine, and enters the perineum through the lesser sciatic foramen, approximately 4 cm above the lower limit of the tuberosity. As it approaches the ischial ramus, the artery proceeds deep to the urogenital diaphragm and ends behind the inferior pubic ligament by dividing into the following arteries:

- the bulbourethral artery, which is a short large-calibre artery that enters the bulbospongiosus
- the dorsal artery, that travels along the dorsum of the penis in a coiled configuration in the flaccid state that

straightens in the erectile state. Along its course it gives off 3 to 10 circumflex branches around the lateral surface of the corpora. The terminal branches supply the glans penis. Sometimes, a branch penetrates the tunica and, in some individuals, help supply the erectile tissue.

- the cavernosal artery, usually a single artery, arises on each side as the terminal branch of the penile artery. This artery enters the corpus cavernosum at the hilum, runs the length of the penile shaft, and gives off many helicine arteries that constitute the arterial portion of the erectile apparatus. Occasionally, a branch enters the opposite corpus and sometimes a single artery branches in the opposite corpus (Figures 1a and 1b).<sup>14-16</sup>



**Figure 1.** Schematic drawing demonstrating the normal anatomy of (a) internal pudendal artery (shaded) and (b) arterial anatomy of the penis.

This article will discuss transcatheter embolization with Gelfoam as this method is generally used at Vancouver General Hospital because of its safety, ease of use, and low cost. There are no specific contraindications to the procedure, apart from general guidelines such as coagulopathy or other life threatening injury, which should be corrected first.

## PRE-PROCEDURE ASSESSMENT

A careful history and physical examination are essential to determine the type of priapism. The coagulation profile and creatinine of the patient are obtained prior to any angiogram, and a review of previous imaging of the patient, if available, is performed to determine the presence or absence of other injuries. Cavernal aspiration of blood is used to measure oxygen tension and helps to confirm arterial (high) versus venous (low) oxygen, therefore confirming the high-flow state.

Colour duplex, if available, is useful for confirming the diagnosis and localising the fistula, by identifying the appearance of the fistula, or the presence of a pseudoaneurysm.

## PATIENT PREPARATION

Reliable IV access is established first. Conscious sedation is achieved with fentanyl citrate in increments of 50 mcg IV and midazolam in increments of 1 mg IV. Vital signs and oxygen saturation should be monitored.

## MATERIALS

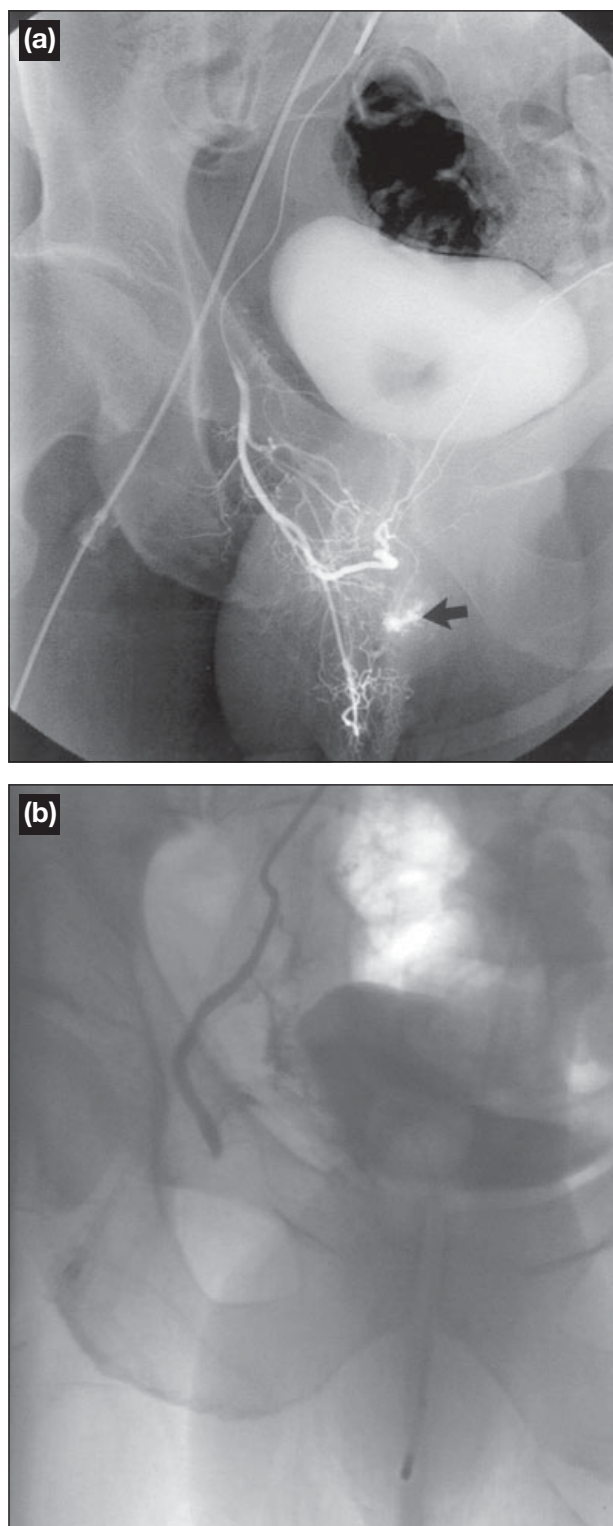
The following materials are required:

- a 5 F end-hole pigtail catheter (Cook Inc, Bloomington, USA) to perform a pelvic angiogram and a 5 F Cobra C1 catheter (Cook Inc, Bloomington, USA) to perform a contralateral common iliac and selective internal iliac arteriography
- a 3 F tracker catheter (Target Therapeutics, Fairmont, USA) should be available, as it may be required for cannulisation of the internal pudendal artery
- conventional hydrophilic-angled guide wires such as 0.035 movable core (Cook Inc, Bloomington, USA)
- gelatin sponge torpedoes (Gelfoam, Upjohn, Kalamazoo, USA)
- a 5 F sheath (Cook Inc, Bloomington, USA).

## PROCEDURE

### Preparation

The procedure should be performed in an interventional angiographic suite with high-resolution C-arm fluoroscopy and digital subtraction angiography, if possible.



**Figure 2.** Pelvic angiogram obtained via the right common femoral artery puncture. (a) This demonstrated an abnormal blush at the base of the penis, predominantly on the right (arrow). A left common femoral artery puncture was secured and a catheter advanced deep into the internal pudendal — single Gelfoam torpedo was delivered producing occlusion of the artery. (b) No persistence of the fistula was noted on completion angiography. At the conclusion of the procedure, the patient's priapism had almost completely resolved.

The groin is cleansed with proviodine and alcohol and covered with an adhesive dressing. The remainder of the body is covered with sterile drapes. All vital signs should be monitored, and an electrocardiogram and pulse oximetry placed in their usual anatomic positions. In the Department of Radiology, monitoring and drug administration is supervised by a highly trained full-time radiology/angiography nurse.

### Technique

Pelvic angiogram and selective internal iliac angiograms are obtained. A track catheter may be required to selectively cannulate the internal pudendal artery (Figure 2). The catheter should be advanced as far as possible to minimise the risk of impotence. A blush at the site of the traumatic fistula confirms the diagnosis.

A sheet of gel foam torpedo(es) several mm in size are rolled flat so that they are very thin. They are then cut into strips, approximately 1 to 2 mm wide and 2 to 3 mm long, and delivered to the region of the arteriovenous fistula or pseudoaneurysm using 3 ml syringes. Contrast medium is used to deliver the torpedo, producing occlusion of the artery and/or fistula. Bilateral embolizations are often required. Gelfoam torpedoes must be very small if a tracker is used for delivery so as not to choke the catheter — coils may be used instead.

A repeat angiogram upon deploying the Gelfoam is important to ascertain the persistence of the fistula. This usually results in detumescence almost immediately but may take up to 1 day.

### COMPLICATIONS

Minor haematoma at the puncture site occurs in less than 5% of patients. A major haematoma requiring surgery occurs in less than 0.5% of patients. An arteriovenous fistula at the puncture site occurs in approximately 0.05% of patients. Pseudoaneurysm formation or vessel thrombosis occurs in less than 0.01% of patients.<sup>17,18</sup> Non-target embolization into the common iliac artery is minimised when superselection of the internal pudendal artery is performed. Penile gangrene rarely occurs, even if bilateral occlusion of internal pudendal arteries is undertaken, and is largely dependent on the duration of priapism and aggressiveness of treatment with the overall rate of impotence and fibrosis reported to be 20%.<sup>4</sup> Clinical follow up post-embolization

generally reveals return of patients' erectile activity to normal by 2 months and resumption of sexual activity by the end of the 3rd month.<sup>3,9,13</sup>

### REFERENCES

1. Broderick GA. Iatrogenic priapism. *Urol Clin North Am* 1996; 23:111-126.
2. Paulter S. High flow priapism. *Urol Clin North Am* 2001;28: 391-403.
3. Kang BC, Lee DY, Byun JY, Baek SY, Lee SW, Kim KW. Post-traumatic arterial priapism: colour Doppler examination and superselective arterial embolization. *Clin Radiol* 1998;53: 830-834.
4. Lue TF, Broderick G. Evaluation and nonsurgical management of erectile dysfunction and priapism. In: Walsh P, Retik A, Vaughan ED, Wein A, editors. *Campbells text book of urology*. Vol II. 7th ed. Philadelphia: WB Saunders; 1988:1208-1209.
5. Mabjeesh NJ, Shemesh D, Abramowitz HB. Posttraumatic high flow priapism: successful management using duplex guided compression. *J Urol* 1999;161:215-216.
6. Lewis R. Surgery for erectile dysfunction. In: Walsh P, Retik A, Vaughan ED, Wein A, editors. *Campbells text book of urology*. Vol II. 7th ed. Philadelphia: WB Saunders; 1988:1232-1233.
7. Fratezi AC, Martins VM, Porto RM, et al. Endovascular therapy for priapism secondary to perineal trauma. *J Trauma* 2001;50: 581-584.
8. Millward SF, Aquino J Jr, Collins JP. High-flow priapism — recurrence after initially successful selective coil embolization: case report. *Can Assoc Radiol J* 1997;48:105-107.
9. Wear JB Jr, Crummy AB, Munson BO. A new approach to the treatment of priapism. *J Urol* 1977;117:252-254.
10. Crummy AB, Ishizuka J, and Madsen P. Posttraumatic priapism: successful treatment with autologous clot embolization. *AJR* 1979;133:329-30.
11. MacErlean DP, McDermott E, Kelly DG. Priapism: successful management by arterial embolisation. *Br J Radiol* 1982;55: 924-926.
12. Walker G, Grant P, Goldstein I, et al. High flow priapism: treatment with superselective transcatheter embolization. *Radiology* 1990;174:1053-1054.
13. Numan F, Cakirer S, Islak C, et al. Posttraumatic high-flow priapism treated by N-butyl-cyanoacrylate embolization. *Cardiovasc Intervent Radiol* 1996;19:278-280.
14. Rao DS, Donatucci CF. Erectile dysfunction vasculogenic impotence arterial and venous surgery. *Urol Clin North Am* 2001;28:309-319.
15. Anatomy of the internal pudendal artery. In: Warwick R, Williams P, editors. *Grays anatomy*. 35th ed. Boston: Longman; 1973:669.
16. Jordan G, Schlossberg S, Devine C. Surgery of the penis and urethra. In: Walsh P, Retik A, Vaughan ED, Wein A, editors. *Campbells text book of urology*. Vol II. 7th ed. Philadelphia: WB Saunders; 1988:3323-3324.
17. Puppo P, Belgrano E, Germinale F, Bottino P, Giulani L. Angiographic treatment of high-flow priapism. *Eur Urol* 1985;11: 397-400.
18. Levy J, Hessel S. Complications of angiography and interventional radiology. In: Baum S, editor. *Abraham's angiography*. Vol II. 4th ed. Boston: Little Brown; 1997:1024-1025.