

## Advances in Mammography Have Improved Early Detection of Breast Cancer

KH Ng,<sup>1</sup> M Muttarak<sup>2</sup>

<sup>1</sup>Department of Radiology, University of Malaya, Kuala Lumpur, Malaysia

<sup>2</sup>Department of Radiology, Chiang Mai University, Chiang Mai, Thailand

### ABSTRACT

*Breast cancer remains a leading cause of death among women throughout the world. The incidence is increasing globally and the disease remains a significant public health problem. Mammography is currently the best method to detect early breast cancer before it becomes clinically palpable. The use of mammography results in a 25% to 30% decreased mortality rate in screened women compared with controls after 5 to 7 years. Today's dedicated mammographic equipment with specially designed X-ray screen/film combinations coupled with controlled film processing produces excellent image quality mammograms. It is important to produce reliable high-contrast, high-resolution images for mammography. Both the American College of Radiology Mammography Accreditation Program and the Mammography Quality Standards Act have had significant impact on the technical quality of mammographic images in the USA and worldwide. The recent development in digital mammography has opened the possibility for improving diagnosis and novel applications. This article reviews the major technical developments that led to today's high quality mammograms.*

*Key Words:* Digital radiography, Image quality, Mammography, Quality control

### Early Detection of Breast Cancer

Breast cancer remains a leading cause of death for women throughout the world. It is the most common malignancy among women in developed countries and the second or third most common malignancy among women in developing countries.<sup>1</sup> The incidence of breast cancer is increasing globally and the disease remains a significant public health problem. The prognosis of breast cancer is related to the stage of the disease at diagnosis and treatment. The earlier the tumour is detected, the better the prognosis. Routine screening for breast cancer for asymptomatic women can detect clinically non-palpable tumours resulting in a survival rate of 95.1% after almost 20 years.<sup>2</sup> Early detection of breast cancer also permits less aggressive therapeutic options such as lumpectomy followed by radiation therapy as opposed to mastectomy, and a decreased need for systemic chemotherapy.

Mammography is currently the best method to detect early breast cancer before it becomes clinically palpable. The use of mammography results in a 25% to 30% decreased mortality rate in screened women compared with controls after 5 to 7 years.<sup>3</sup> A recent update of the experience of the Swedish 2-county screening trial at 20 years follow-up shows a significant 32% reduction in mortality.<sup>4</sup> Controversy has arisen about the age at which regular screening should begin. Many countries in Europe recommend biennial screening for women aged 50 years and older but many professional organisations in the USA recommend screening every 1 to 2 years for women aged 40 to 49 years, and annual screening for women aged 50 years and older.<sup>5</sup>

Although screening mammography has become well accepted,<sup>2-4</sup> 2 recently published articles by Danish researchers Gotzche and Olsen concluded that mammography is ineffective for reducing breast cancer mortality.<sup>6,7</sup> Despite the opinions of these researchers, many investigators and organisations still recommend screening mammography beginning at the age of 40 years with annual screening intervals because early detection through screening mammography has

---

*Correspondence:* Professor KH Ng, Department of Radiology, University of Malaya, Kuala Lumpur, Malaysia.  
Tel: (60 3) 7950 2088; Fax: (60 3) 7958 1973;  
Email: ngkh@um.edu.my

Submitted: 19 May 2003; Accepted: 9 July 2003.

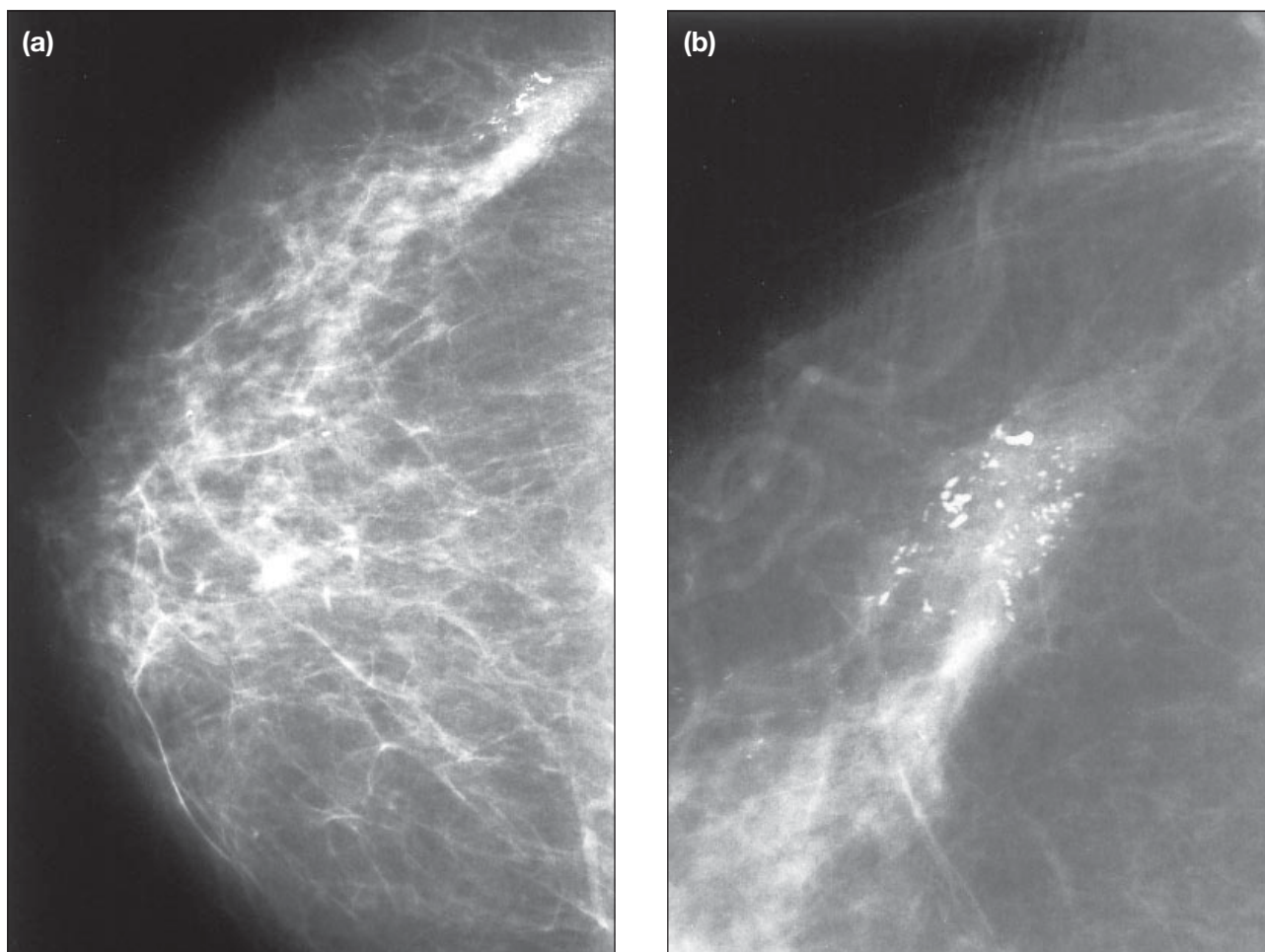
undoubtedly played a role in breast cancer mortality reduction.<sup>5,8-12</sup>

Before the widespread use of screening mammography, ductal carcinoma in situ (DCIS) was considered a relatively uncommon lesion, accounting for only 0.85% to 5.0% of all breast carcinomas.<sup>13</sup> Since the recent introduction of screening mammography, DCIS accounts for 30% to 45% of all detected cancers. The dramatic increase in incidence of DCIS can be explained by the introduction of screening mammography.<sup>14</sup> Microcalcifications are an especially important sign of early breast cancer since they are the dominant abnormality in 90% of in situ carcinomas.<sup>15</sup> Any measure that improves the mammographic demonstration or the radiologist's perception of microcalcifications should improve detection of DCIS. Technical advances in mammography equipment have led to significant improvement in mammographic image quality and changed the ability to detect early breast carcinoma (Figure 1).

### Technical Advances in Mammography

Although screen film mammography (SFM) is good, it is neither perfectly sensitive nor highly specific. It has important limitations in detecting subtle soft tissue lesions that represent breast carcinoma, especially in the presence of dense breast tissue. Because many carcinomas are undetected, there are ongoing efforts to improve the ability of mammography to detect cancers earlier.

There have been significant advances in mammographic X-ray equipment and in screen/film recording systems during the past 25 years.<sup>16-18</sup> Until the mid 1980s, many X-ray units were not dedicated mammography systems. These units had tungsten target tubes that were originally designed for other medical imaging procedures such as chest radiography. Many of these units had home-made compression devices that could not ensure adequate compression of the breast. Many of these units had large focal spots or short focal spot-to-breast surface distances that could result in significant geometric



**Figure 1.** Routine craniocaudal mammogram versus spot-magnification mammogram. (a) Right craniocaudal mammogram shows a clustered of microcalcifications in the outer quadrant and (b) spot-magnification mammogram shows better details of microcalcifications, which are linear and branching. Histology revealed ductal carcinoma in situ, comedo type.

blur (unsharpness). Direct exposure (industrial type) X-ray films were being used, which often required long exposure times (causing blur by motion) and that resulted in high radiation exposure. In addition, viewing conditions were inadequate.

Today, mammography is performed with dedicated mammography X-ray equipment.<sup>16-18</sup> These units have specially designed X-ray tubes, smaller focal spots, and significantly improved breast compression devices, among other features. Modern X-ray tubes have multiple targets of tungsten, molybdenum, and rhodium that are selected by microprocessor to give optimum tissue penetration. Cassettes and special films and intensifying screens are designed especially for mammography. Film processing has been the major weak link giving rise to image quality problems and artifacts. Nevertheless this has also significantly improved over time. Today, it is possible to obtain mammograms with higher image quality at a significantly lower radiation dose compared with 25 years ago. In 2000, the first digital mammography system was approved by the USA Food and Drug Administration (FDA) for clinical use. Table 1 lists the historical milestones in technical advances in mammography.

### Image Quality of Mammograms

Obtaining optimum image quality in mammography is technically very demanding, especially since this impacts on the accuracy of the diagnosis. Figure 2 shows measured X-ray attenuation coefficients of fibroglandular breast tissue, fat, and breast carcinoma versus X-ray energy.<sup>19</sup> The small difference between the curves illustrate why mammography is such a challenging imaging task, particularly when the tumour is surrounded by fibroglandular tissue. The limited dynamic range of film-screen mammography presents a serious limitation in detecting and recording the

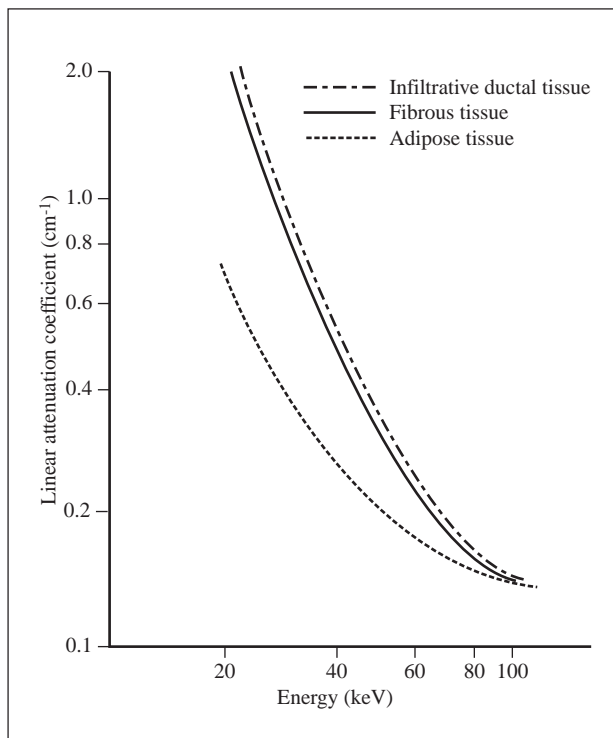


Figure 2. Attenuation coefficients of various breast tissues.<sup>19</sup>

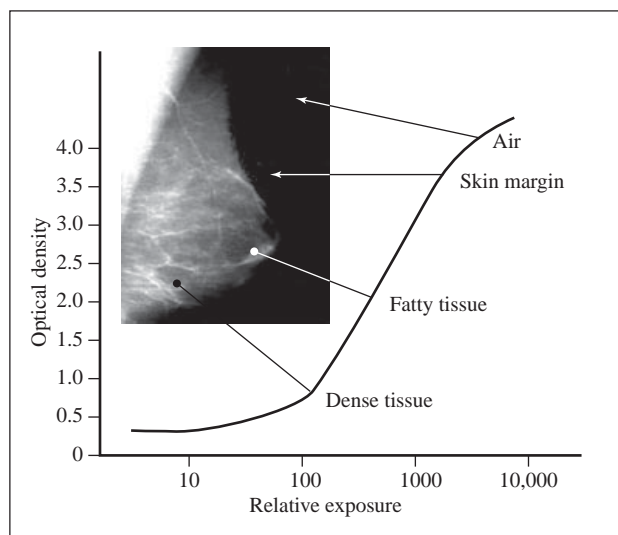
various components of the breast. The sigmoidal characteristic curve (Figure 3) is such that the contrast is high for intermediate exposure areas but low for both low and high exposures. In other words, ‘thin’ and ‘dense’ areas of the breast are displayed with low contrast; but this is improved with digital mammography.

### Quality Control Regulations in Maintaining Standard

Since the American Cancer Society guidelines for early detection of breast cancer have become widely accepted by the medical community, and because some facilities were known to produce poor quality mammograms, in 1987, the American College of Radiology (ACR) developed the Mammography Accreditation Program

Table 1. Historical milestones in technical advances in mammography.<sup>16-18</sup>

Year	Development	Organisation
Before 1969	Conventional tungsten target X-ray tubes with direct exposure industrial type film	
1969	Dedicated mammographic unit with molybdenum target tube and compression device	Compagnie Generale Radiologie Senographe
1971	Xeromammography	Xerox
1972	Screen-film system	Du Pont Lo-dose system
1976	Rare earth screen-film system and special cassette	Kodak Min-R system
1977	Magnification with microfocal spot	Radiological Sciences Inc.
1978	Grid	Philips
1987	American College of Radiology Mammography Accreditation Program	American College of Radiology
1992	American College of Radiology Mammography Quality Control Manual introduced	American College of Radiology
1994	Mammography Quality Standards Act (MQSA) implementation	Food and Drug Administration
2000	First digital mammography approved by the USA Food and Drug Administration for clinical use	General Electric Senographe 2000D



**Figure 3.** Mammography characteristic curve showing limited dynamic range.

that placed a strong emphasis on controlling and maintaining image quality and radiation dose levels. The ACR Quality Control Manual was introduced in 1992.<sup>20</sup> The ACR recommended that the mean glandular dose per film for an examination of 4.5 cm thick compressed breast of average composition is less than 1 mGy (without grid) and 3 mGy (with grid). Image quality analysis is performed to ensure that the film optical density, contrast, uniformity, and image quality imaging system and film processor are maintained at optimum levels. This is accomplished using an accreditation phantom (RMI 156 or 18-220) that simulates fibres, specks (micro-calcifications), and masses.

In October 1994, the Mammography Quality Standards Act (MQSA) became law.<sup>21</sup> According to the MQSA, a mammography facility must be certified by the FDA. MQSA requires annual medical physicist surveys on screen-film mammogram equipment. This has a significant impact on the improvement of the technical quality of mammographic images in the USA and worldwide. The ACR Mammography Accreditation Program has since become the international standard for quality control programs.

### Advent of Digital Mammography

Digital mammography is the most recent significant development in mammography. Digital mammography uses essentially the same mammography system as conventional mammography, but the system is equipped with a digital receptor to capture the breast image digitally for display on a computer monitor. With digital mammography, the magnification, orientation,

brightness, and contrast of the image may be altered after the exam is completed to help the radiologist see certain areas more clearly. This method presents a unique opportunity and challenge, with a new set of technical considerations, physical principles, and quality control. This technique offers many benefits such as improved contrast resolution, reduced radiation dose, post-acquisition image enhancement, rapid image display, improved imaging for dense breasts, improved sensitivity and specificity, simplified archival, retrieval and transmission, potential for computer-aided detection and diagnosis (CAD), and telemammography.

The X-ray detector system is fundamental to the performance of digital mammography. Currently, these detector technologies include flat panel imagers using amorphous silicon detector arrays integrated with a scintillator, flat panel direct detection approaches using amorphous selenium, photostimulable phosphors, and slot scanning techniques using charge-coupled devices.

While digital mammography is promising, it has some limitations that must be overcome before it can replace conventional mammography. Digital mammography must provide higher detail resolution (standard SFM provides up to 20 lp/mm) and become less expensive (digital mammography is currently 4 to 5 times more costly than conventional mammography). Equipment for digital mammography is commercially available both with small area (for digital stereotactic biopsy) and full-field digital mammography (FFDM), where the automatic exposure control detector can be the same as the entire image detector. In small field mammography, charge-coupled device detectors have been used with resolution of 20 lp/mm and challenge that of SFM. This is not the case for FFDM, due to the increase in the field size and number of pixels required to image the full breast.

A study has been conducted using mammographic contrast detail phantoms to compare low contrast performance of SFM and digital mammography.<sup>22</sup> A dual light collection mammographical imaging plate was employed providing digital images with pixel density of 50 mm. It was found that, despite the measured spatial resolution of digital and SFM images of 8 and 10 lp/mm, respectively, low contrast imaging performance of digital system was comparable with that of SFM.<sup>22</sup>

FFDM may offer improved detection and diagnosis but a recent report by Lewin et al concluded that no significant difference in cancer detection was observed

**Table 2.** Status of development in full-field digital mammography.

Status	Full-field digital mammography	Detector type
USA Food and Drug Administration approved	General Electric Senographe 2000D Fisher SenoScan Hologic Lorad Digital Breast Imaging	Amorphous silicon Charge-coupled device Charge-coupled device
Currently being investigated	Hologic/Lorad Selenia Siemens Fuji FCR Sectra MicroDose Mammography Hologic/Agfa Selenia Instrumentarium Diamond PlanMed Sophie Digital	Amorphous selenium Photostimulable phosphor Amorphous silicon Amorphous selenium Amorphous silicon Amorphous selenium

Abbreviation: FCR = Fuji Computed Radiography.

between FFDM and SFM but FFDM resulted in fewer recalls than did SFM.<sup>23</sup> However, these results are early and the studies are ongoing. More recent performance comparison of FFDM systems (18 x 24 cm) to SFM indicate that the clinical use of FFDM may generally improve image quality for equal or lower breast doses while providing tighter control on exposures and image quality than SFM.<sup>24</sup> Table 2 provides the status of development for FFDM.

The accuracy of the current digital mammography systems versus screen-film mammography is being evaluated in the Digital Mammographic Imaging Screening Trial (DMIST) study of 49,500 women, conducted through the ACR Imaging Network (ACRIN) at 19 study sites in the USA and Canada.<sup>25</sup> This largest USA federally funded clinical trial on medical imaging study is currently in progress. The full impact of digital mammography is likely to become significant when novel and emerging applications such as computer-aided detection and diagnosis (CAD), telemammography, contrast uptake imaging, tomosynthesis, tissue characterisation, and risk prediction through breast density analysis become clinically acceptable.<sup>26</sup> A brief description of these new applications is given below.

#### **Computer-aided Detection and Diagnosis**

In a digital mammography CAD system, suspicious lesions would be indicated to the radiologists by arrows or some other marking on the display screen. After a lesion is detected, artificial intelligence could be used to estimate the likelihood of malignancy to reduce the number of false positive biopsies and thereby increase diagnostic specificity.

#### **Telemammography**

Telemammography, which is transferral of digital images from one location to another, opens up new

possibilities for organising the routine reading of screening examinations to perform fast consultation or to demonstrate examinations in a remote location.

#### **Contrast Uptake Imaging**

In contrast uptake imaging, a series of images are taken after injection of Gadolinium diethyltriaminepentaacetic acid (Gd DPTA) contrast agent with the pre-contrast image subtracted. The net images are then evaluated as a function of tissue.

#### **Tomosynthesis**

In tomosynthesis, several images are acquired from different directions with a stationary detector and the result is an image with structures seen in a plane, while structures from remote planes in the object are more or less blurred.

The technique improves the investigation of lesions by eliminating irrelevant contrasts and may be useful for imaging dense breasts where fibrous tissue can obscure the visibility of a mass or other signs of cancer.

#### **Tissue Characterisation**

Once the image data are digital, dual-energy mammography is another technology that becomes practical. With this technique information about the atomic number and density characteristics of the tissue through which the X-ray beam traversed can be obtained. A weighted subtraction of one image from another can be done and additional information about tissue composition can be obtained.

#### **Quantitative Image Analysis: Risk Assessment**

With digital techniques, quantitative analysis of breast density data and textures of mammograms of asymptomatic women can allow prediction of future risk of breast cancer.

## REFERENCES

- Parkin DM, Muir CS, Whelan SL, Gao YT, Ferlay J, Powell J. Cancer incidence in five continents. Vol VI. Lyon: IARC Scientific Publication No 120, IARC; 1992.
- Letton AH, Mason EM, Ramshaw BJ. Twenty-year review of a breast cancer screening project: ninety-five percent survival of patients with nonpalpable cancers. *Cancer* 1996;77:104-106.
- Kerlikowske K, Grady D, Rubin SM, Sandrock C, Ernster VL. Efficacy of screening mammography: a meta-analysis. *JAMA* 1995;273:149-154.
- Tabar L, Vitak B, Chen HH, et al. The Swedish two-county trial twenty years later: update mortality results and new insights from long-term follow-up. *Radiol Clin North Am* 2000;38:625-651.
- Lee CH. Screening mammography: proven benefit, continued controversy. *Radiol Clin North Am* 2002;49:395-407.
- Gotzsche PC, Olsen O. Is screening for breast cancer with mammography justifiable? *Lancet* 2000;355:129-134.
- Olsen O, Gotzsche PC. Cochrane review on screening for breast cancer with mammography. *Lancet* 2001;358:1340-1342.
- Smart CR, Hendrick RE, Rutledge JH, Smith RA. Benefit of mammography screening in women ages 40 to 49 years: current evidence from randomized control trials. *Cancer* 1995;75:1619-1626.
- Feig SA, D'Orsi CJ, Hendrick RE, et al. American College of Radiology guidelines for breast cancer screening. *AJR* 1998; 171:29-33.
- NCI statement on mammography screening. Office of Communications/Mass Media Branch. Bethesda: National Institutes of Health; 2002.
- Screening for breast cancer. Recommendations and rationale. Rockville: Agency for Healthcare Research and Quality; 2002.
- Jackson VP. Screening mammography: controversies and headlines. *Radiology* 2002;225:323-326.
- Stomper PC, Margolin FR. Ductal carcinoma in situ: the mammographer's perspective. *AJR Am J Roentgenol* 1994;162: 585-591.
- Feig SA. Ductal carcinoma in situ: implications for screening mammography. *Radiol Clin North Am* 2000;38:653-668.
- Feig SA. Hormonal reduction of mammographic densities: potential effects on breast cancer risk and performance of diagnostic and screening mammography. *J Natl Cancer Inst* 1994; 86:408-409.
- Haus AG, Yaffe MJ, editors. Categorical course in diagnostic radiology physics: physical aspects of breast imaging current and future considerations. syllabus. Oak Brook: Radiological Society of North America; 1999.
- Haus AG, Yaffe MJ. Screen-film and digital mammography: image quality and radiation dose considerations. Dedicated mammographic X-ray equipment, screen-film processing systems and viewing conditions for mammography. *Semin Breast Dis* 1999;2:22-51.
- Haus AG, Yaffe MJ. Screen-film and digital mammography, in breast imaging. *Clin Radiol North Am* 2000;38:871-898.
- Johns PC, Yaffe MJ. X-ray characterization of normal and neoplastic breast tissues. *Phys. Med. Biol.* 1987;32:675-95.
- American College of Radiology (ACR) Mammography Quality Control Manual for Radiologists, Radiologic Technologists and Medical Physicists. Reston: American College of Radiology; 1999.
- MQSA. Mammography Quality Standards Act. <http://www.fda.gov/cdrh/mammography/mqsa-rev.html>
- Jamal N, Ng K-H, McLean D. Low contrast imaging performance of computed radiography and screen-film mammography systems. *Med Phys* 2003. In press.
- Lewin JM, D'Orsi CJ, Hendrick RE, et al. Clinical comparison of full-field digital mammography and screen-film mammography for detection of breast cancer. *AJR* 2002;179:671-677.
- Berns EA, Hendrick RE, Cutter GR. Performance comparison of full-field digital mammography to screen-film mammography in clinical practice. *Med Phys* 2002;29:830-834.
- ACRIN. American College of Radiology Imaging Network. <http://www.acrin.org/>
- Yaffe MJ. Digital mammography. In: Beutel J, Kundel HI, Van Metter RI, editors. Handbook of medical imaging. Vol 1. Physics and psychophysics. Bellingham: The International Society for Optical Engineering 2000;329-372.

### Continuing Medical Education in *Journal of the Hong Kong College of Radiologists*

The *Journal of the Hong Kong College of Radiologists* has introduced continuing medical education (CME) for Fellows of the Hong Kong College of Radiologists. The CME is based on articles published in the *Journal*, and the Editorial Board exercises the duty of selecting appropriate articles for such a purpose.

One CME point will be awarded for satisfactory completion (60% or more correct answers) of questions from each article selected.

Fellows of the Hong Kong College of Radiology may participate by returning the answer sheet by mail or fax to the College Secretariat.

#### Instructions

- Download the CME answer sheet from the website of Hong Kong College of Radiologists at <http://www.hkcr.org> or use the CME Questionnaire form provided on page 177 of this issue.
- Fill in your name on the answer sheet.
- Tick the correct answer square for each question.
- Mail or fax the answer sheet to the College by the submission deadline (30 Nov 2003 for this issue).

Hong Kong College of Radiologists, Room 909, 9/F, Hong Kong Academy of Medicine Jockey Club Building, 99 Wong Chuk Hang Road, Aberdeen, Hong Kong, China.  
Fax: (852) 2554 0739